

## Case Report

# Effect of Unani formulations on frostbite induced gangrene: a case report

Mohammad Shamim Khan\*

Department of Unani Medicine, Government Unani Dispensary, Kota, Rajasthan, India

**Received:** 27 February 2020

**Accepted:** 02 April 2020

**\*Correspondence:**

Dr. Mohammad Shamim Khan,  
E-mail: drshamimmd@yahoo.co.in

**Copyright:** © the author(s), publisher and licensee Medip Academy. This is an open-access article distributed under the terms of the Creative Commons Attribution Non-Commercial License, which permits unrestricted non-commercial use, distribution, and reproduction in any medium, provided the original work is properly cited.

### ABSTRACT

This article reports a case in which a 65 years old female patient of frostbite induced gangrene, was treated with unani drugs; Sharbat Banafsha and Arq Murakkab Musaffi Khoon as oral administration, and Marham Safed Kafoori as topical application, with the aim to evaluate the efficacy of drugs and to avoid Surgery. Patient has shown excellent and admirable result within 60 days of treatment. Finally frost bitten and gangrenous part completely healed and repaired without any surgical intervention.

**Keywords:** Gangrene, Unani Formulation, Anti-inflammatory activity, Anti-ulcer activity, Wound healing activity

### INTRODUCTION

Gangrene (Gangarana/Shafaquloos) means tissue death caused by a lack of blood flow, often occurs in the extremities like toes, fingers and limbs, evolving from infection, inflammation, injury, and degenerative changes, associated with chronic diseases, like diabetes mellitus.<sup>1,2</sup> Frostbite (Baradiyah) is defined as the acute freezing of tissues when exposed to temperatures below the freezing point of intact skin. The severity of injury depends upon the temperature gradient at the skin surface and the duration of exposure.<sup>3</sup> The pathophysiologic mechanism of frostbite injury associated with three pathways; tissue freezing, hypoxia, and the release of inflammatory mediators.<sup>3</sup> It is an important triggering factor for dry gangrene; clinically identified as cold, black, dry out and wither, eventually drops off over a period of weeks or months.<sup>2</sup>

Debridement and Amputation are definitive treatments for gangrene in all currently available pathies of medicine. Although Dhillon and Singh (2003) claimed the successful treatment of tail gangrene in buffaloes, yet

I have made an attempt to report here the clinical results of frostbite induced index finger gangrene in human being treated with Unani medicines.<sup>4</sup>

### CASE REPORT

A 65 years old female having gangrene visited to government Unani dispensary, Bheemganj Mandi, Kota, Rajasthan, India, for treatment. Since last 15 days, she suffered from gangrene in her right index finger caused by frostbite (Figure 1). The patient has mixed clinical features of gangrene and frostbite. The chief complaint was black, dry, and shrunken skin lesion with hard consistency, feeling of numbness in upper pore of ventral aspect of right index finger, while remaining parts of that finger influenced by intense pain, burning, tingling sensations and bluish colored, firm skin with soft underlying tissue, along with restricted movement of the finger and flu-like symptoms such as fever, lightheadedness, malaise, chills. She gave consent to start Unani treatment.

The patient was advised to take 20 ml of Sharbat Banafsha and 50 ml of Arq Murakkab Musaffi Khoon

with plain water twice a day at morning and evening on empty stomach orally, and to apply Marham Safed Kafoori on affected lesion of right index finger after placing in the warm decoction (Joshanda), prepared with Berg-e-Neem (*Azadirachta indica* leave) for 15 to 30 minutes as rewarming. Sharbat Banafsha and Arq Murakkab Musaffi Khoon are pharmacopeal, marketed from GMP certified company Hamdard and prepared according to Bayaz-e-Kabeer volume 2, while Marham Safed Kafoori; a patent Unani drug prepared in Ayurved Rasayan Shala Ajmer, Government of Rajasthan, and supplied to the Unani Dispensary, Kota, Rajasthan.<sup>5,6</sup> The duration of study was 60 days and no concomitant therapy was allowed during the study. The patient was assessed on the basis of clinical examination at every 15<sup>th</sup> day.

The composition of Sharbat Banafsha (each 25 ml) are; aqueous extract from Gul-e-Banafsha (*Viola odorata*) (flower) (extract) 3.02 gm, Qand Safed (*Saccharum officinarum*) (crystal) 24.19 gm.<sup>5</sup>

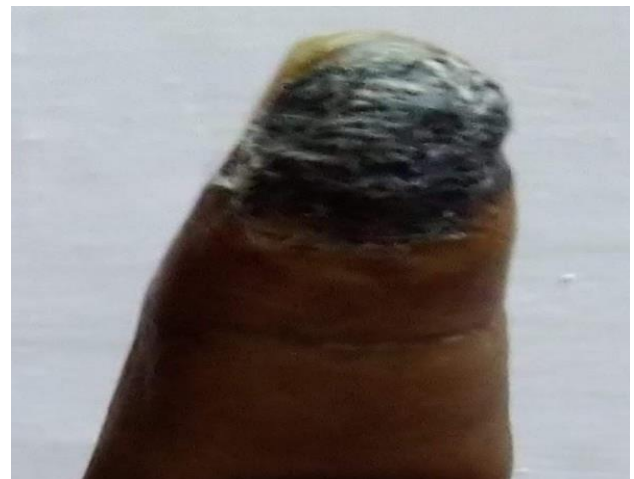The constituents of Arq Murakkab Musaffi Khoon (each 10 ml) are distillate of; Berg-e-Neem (*Azadirachta indica*) (leaf) (distillate) 104 mg, Post-e-Neem (*Azadirachta indica*) (stem bark) (distillate) 104 mg, Post-e-Bakain (*Melia azedarach*) (stem bark) (distillate) 104 mg, Berg-e-Bakain (*Melia azedarach*) (leaf) (distillate) 104 mg, Post-e-Kachnal (*Bauhinia racemosa*) (stem bark) (distillate) 104 mg, Post-e-Mulsari (*Mimusops elengi*) (stem bark) (distillate) 104 mg, Dudhi Khurd (*Euphorbia hirta*) (root) (distillate) 104 mg, Berg-e-Bhangra Siyah (*Ecliptaalba*) (leaf) (distillate) 104 mg, Shakh Berg-e-Jawansa (*Alhagi pseudalhagi*) (leaf) (distillate) 104 mg, Post-e-Gulnar (*Punica granatum*) (stem bark) (distillate) 104 mg, Berg-e-Hina (*Lawsonia inermis*) (leaf) (distillate) 104 mg, Mundi (*Sphaeranthus indicus*) (flower) (distillate) 104 mg, Shahtara (*Fumaria parviflora*) (leaf) (distillate) 104 mg, Sarphoka (*Tephrosea purpurea*) (leaf, flower) (distillate) 104 mg., Dhamaya (*Fagonia arabica*) (flower) (distillate) 104 mg, Chob Bijyasar (*Pterocarpus marsupium*) (heart wood) (distillate) 104 mg, Gul-e-Nilofar (*Nymphaea alba*) (flower) (distillate) 104 mg, Burada-e-Sandal Surkh (*Pterocarpus santalinus*) (heart wood) (distillate) 104 mg, Burada-e-Sandal Safed (*Santalum album*) (heart wood) (distillate) 104 mg, Gule Surkh (*Rosa damascena*) (flower) (distillate) 104 mg, Kishneez Khushk (*Coriandrum sativum*) (flower) (distillate) 104 mg, Tukhm Kasni (*Cichorium intybus*) (Sd.) (distillate) 104 mg, Beikh Kasni (*Cichorium intybus*) (root) (distillate) 104 mg, Majeeth (*Rubia cordifolia*) (stem bark) (distillate) 104 mg, Berg-e-Baid Sada (*Salix alba*) (leaf) (distillate) 104 mg, Burada Chob Sheesham (*Dalbergia sissoo*) (heart wood) (distillate) 104 mg, and Water 20 ml.<sup>5</sup>

The ingredients of *Marham Safed Kafoori* (per 30 gm) are; Zinc oxide 1.8gm, Kafoor (camphor) 1.8 gm, Mom

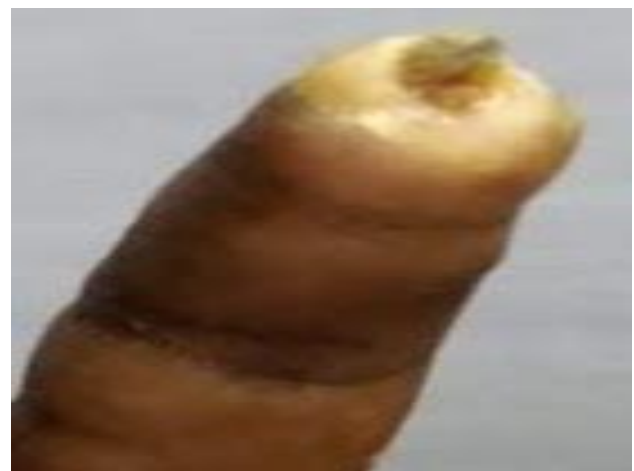Desi (beeswax) 7.8 gm, Roghan-e-Kunjad (sesame oil) 15.3 gm, Gul-e-Surkh (*rosa damascena* flower) 3.3 gm.<sup>6</sup>

## RESULTS

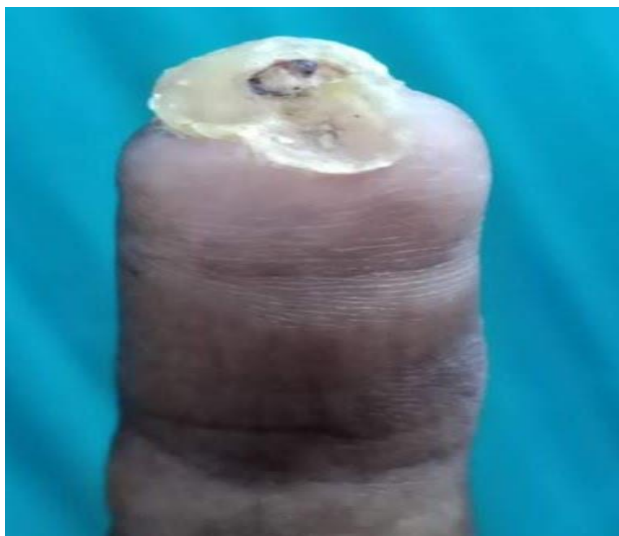
The clinical response in this case was excellent. At the first follow-up (15<sup>th</sup> day) patient reported that affected skin began to leak a foul-smelling discharge within a week of treatment. At 30<sup>th</sup> day; discharge ceased, flu-like and other symptoms like pain, burning, tingling sensations were disappeared and gangrenous part fallen off from index finger, followed by distal phalangeal bone was stripped (Figure 2). At 45<sup>th</sup> day; the exposed distal phalangeal bone broken down automatically, and wound rebuild with new tissues made up of collagen fibers and eventually remodeling (maturation) of the tissues occurred (Figure 3). At 60<sup>th</sup> day; the gangrenous wound of index finger completely healed and repaired (Figure 4). Hence there was debrided the damaged tissues through Unani medicine, without any surgical intervention like skin grafting and amputation. Above all medicines were found to be safe and effective.



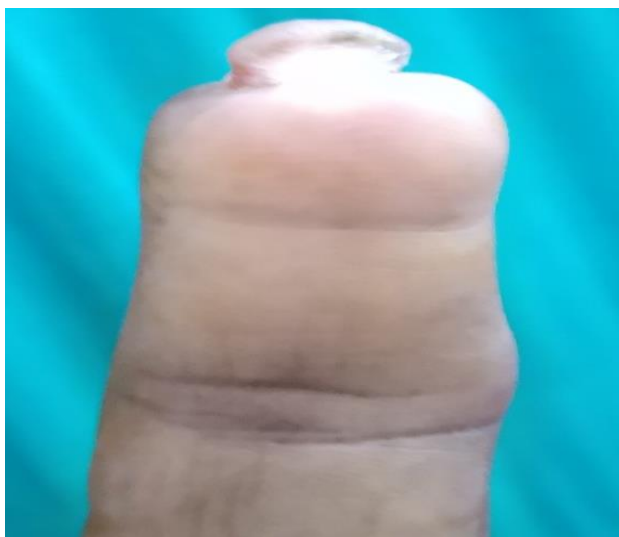**Figure 1: Pre treatment.**



**Figure 2: Post treatment of 30 days.**



**Figure 3: Post treatment of 45 days.**



**Figure 4: Post treatment of 60 days.**

## DISCUSSION

The beneficial actions of prescribed Unani formulations in this case can be attributed to the presence of complex spectrum of actions including blood purifier, anti-inflammatory, anti-ulcer, wound healing, and thrombolytic activities in their ingredients.

Sharbat Banafsha is highly beneficial in fever, cough, headache, eye pain, kidney pain. It removes ribs pain and chest pain.<sup>5,7</sup> Its chief component Gul-e-Banafsha (*Viola odorata* flower) has Haar (hot) and Ratab (moist) Mizaj (temperament) naturally.<sup>8</sup> The Hararat (hotness) of Gul-e-Banafsha (*Viola odorata* flower) may thaw the crystals and cause vasodilation which reverse the tissue freezing and vasoconstriction, while Ratubat (moistness) of *Viola odorata* flower may correct hypoxia by providing hydration extracellular first then intercellular in frostbitten part. It can also control the release of

inflammatory mediators due to Muhallil-e-waram (anti-inflammatory) effect.<sup>9</sup> It may protect the injured part from further damage due to Mulattif (demulcent) effect.<sup>8</sup> It can modify the gangrenous part structurally and functionally from abnormal to normal due to Mu'addil (altering) effect.<sup>8</sup> It is reported that crude methanolic extract at the dose of 400 mg/kg of *Viola odorata* has shown analgesic activity in acetic acid induced writhing and tail immersion animal models.<sup>10</sup> It was observed that, aqueous extract of *viola odorata* has a good anti-inflammatory property for lungs.<sup>11</sup>

Arq Murakkab Musaffi Khoon purifies the blood and cures boils, wheelks and abscess.<sup>5,7</sup> It has several biological activities, present in their ingredients. Condensed tannins from the Neem bark contain gallic acid, (+) gallocatechin, (-) epicatechin, (+) catechin and epigallocatechin, of which gallic acid (6), (-) epicatechin (7) and catechin (8) are primarily responsible for inhibiting the generation of chemiluminescence by activated human polymorphonuclear neutrophil (PMN), indicating that these compounds inhibit oxidative burst of PMN during inflammation.<sup>12</sup> A polysaccharide extracted from bark inhibits carrageenin-induced inflammation in mouse.<sup>12</sup> Two more polysaccharides, GIIa (15) and GIIIa (16) isolated from *M. azadirachta* bark also showed significant anti-inflammatory effect on carrageenin-induced edema in mice.<sup>12</sup> The aqueous extract of Neem leaf possesses potent immunostimulant activity as evidenced by both humoral and cell-mediated responses.<sup>12</sup> Neem leaf aqueous extract produces antiulcer effect in rats exposed to restraint – cold stress or ethanol orally by preventing mucus depletion and mast cell degranulation.<sup>12</sup> An aqueous extract of Neem bark has been shown highly potent antacid secretory and antiulcer activity and the bioactive compound has been attributed to a glycoside.<sup>12</sup> Methanolic and aqueous extract of Mundi flower were found to be an effective neuroprotective agent which could reverse D-galactose-induced oxidative damage and acceleration of aging.<sup>13</sup>

Berg-e-neem, post-e-neem, mundi, Berg-e-bakayan, Shahatra, Sarphoka, Dhamasa, and Burada Sandal Surkh possess blood purifying activity as these remove the toxins and waste products of blood from the affected organ.<sup>8,14</sup> Neem, Mundi, Berg-e-bakayan, post-e-kachnal, Dudhi Khurd, Bhangra Siyah, Shakh Berg-e-Jawansa, Sarphoka, Chob Bijaysar, Kishneez-e-Khushk, and Tukhm-e-Kasni refer to anti-inflammatory activity as these reduce the inflammation of injured part, caused by the release of the potent prostaglandins PGF 2 and thromboxane A2.<sup>8,14</sup> Neem, Mundi, Post-e-Kachnal, Post-e-Moolsari, and Shakh Berg-e-Jawansa allude to Anti-ulcer effect.<sup>8,14</sup> Neem and Mundi implies the wound healing effect.<sup>8,14</sup>

Warm bathing of spoiled part by decoction (Joshanda) of Berg-e-neem (*Azadirachta indica* leave) may be effective due to hydration, anti-inflammatory, antibacterial, antiulcer activities as recommended by researchers.<sup>8,12,14</sup>

Marham Safed Kafoori resolves the inflammation and removes dead tissue and debris. It cleans and heals the wound faster.<sup>6</sup> Zinc has anti-inflammatory properties and increases re-epithelialization supporting its use for treating eczemas.<sup>15</sup> Topical zinc oxide for its strong antioxidant and antibacterial action has been also used in treating atopic dermatitis.<sup>15</sup> It is observed that tail gangrene in buffaloes, recovered 100 per cent just within 4-7 days, by dusting a powder comprising zinc oxide, kaolin and boric acid in equal parts.<sup>4</sup> It inhibits the expression of integrins by keratinocytes and modulates the production of TNF- $\alpha$  and IL-6 and reduces the production of inflammatory mediators like nitric oxide.<sup>15</sup> Zinc also possesses antioxidant property and has been found useful in preventing UV induced damage and reducing the incidence of malignancies.<sup>15</sup> Cinnamon oil was found to be a better antibacterial agent, exhibiting broad range of antibacterial activity against common bacteria.<sup>16</sup> It is investigated that Cinnamomum camphora has potential anti-inflammatory effect on macrophage-mediated inflammatory phenomena such as cytokine production, NO release, PGE2 release, functional activation of adhesion molecules and oxidative stress.<sup>17</sup> Mom (Beeswax) has Muhallil-e-Waram (anti-inflammatory), Musakkin-e-Auja'a (pain sedative), Mundamil-e-Qurooh (wounds healer), and Munbit-e-Laham (muscle fibre grower) properties.<sup>18</sup> It is revealed that a mixture of, beeswax, honey and olive oil, as topical agent clinically effective in the treatment of canine deep second-degree burn as it accelerate the burn wound healing process.<sup>19</sup> Roghan-e-Kunjad (sesame oil) absorbs quickly and penetrates through the tissues to the very marrow of the bone. It enters into the blood stream through the capillaries and circulates.<sup>20</sup> It is mildly laxative, emollient and demulcent and used to treat wounds and burns.<sup>20</sup> It is naturally antibacterial for common skin pathogens such as *Staphylococcus* and *Streptococcus*. It contains a class of unusual compounds known as lignans, comprised of sesamin, sesamol, a small amount of sesamol, a-tocopherol bioavailability, increasing anti-oxidative ability, providing anti-inflammatory function.<sup>20</sup>

## CONCLUSION

It is concluded that treatment of frostbite induced gangrene showed successful result with Sharbat Banafsha, Arq Murakkab Musaffi Khoon and Marham Safed Kafoori. These formulations can be used in the treatment of gangrene to avoid skin grafting, amputation and other complications of gangrene like disability, psychogenic distress and death. Absence of unwanted effects, inexpensiveness, and the effectiveness of the Unani medicines will surely attract as prime therapy for the management of gangrene. Further studies in this direction are required.

*Funding: No funding sources*

*Conflict of interest: None declared*

*Ethical approval: Not required*

## REFERENCES

1. Ibn-e-Sina AAI AH. Alqanoon Fit Tib. Urdu Translation by Syed Ghulam Husain Kantoori. 4th vol. New Delhi: Idarah Kitab-us-Shifa; 2010.
2. Ali MZ, Sultana S. An Assignment on Gangrene. 2012; 1-16.
3. Murphy JV, Banwell PE, Roberts AHN, Mc Grouther DA. Frostbite: Pathogenesis and Treatment. The J of Trauma: Injury, Infection, and Critical Care. 2000;48(1):171-78.
4. Dhillon KS, Singh J, Kumar H, Singh BB, Bal MS. Treatment of tail gangrene in buffaloes. Veterinary Record. 2006;158:176.
5. Kabeeruddin HM. Beyaz-e-Kabeer. 2nd vol. Haiderabad Deccan: Hikmat Book Depo; 2004.
6. Anonymous. Parpatra - 1. Ayurved Rasayanshala Ajmer, Rajasthan; 1990.
7. Anonymous. Disease and Treatment. Hamdard (waqf) Laboratories (India): New Delhi; 2009.
8. Ali HSS. Unani Advia-e-Mufradah. 8th ed. New Delhi: Qaumi Council Barai Farogh Zaban-e-Urdu; 1999.
9. Qasemzadeh MJ, Sharifi H, Hamedanian M, Gharehbeqlou M, Heydari M. The Effect of Viola flower Syrup on the Cough of Children with Asthma: A Double Blind Randomized Controlled Trial. J Evidence-Based Complementary Alternative Med. 2015;20(4):287-91.
10. Antil V, Kumar P, Kannappan N, Diwan A, Saini P, Singh S. Evaluation of the analgesic activity of Viola odorata aerial parts in rats. J Natural Pharm. 2011;2:24.
11. Koochek M, Pipelzadeh M, Mardani H. The effectiveness of Viola odorata in the prevention and treatment of formalin-induced lung damage in the rat. J Herbs Spices Med Plants. 2003;10:95-103.
12. Biswas K, Chattopadhyay I, Banerjee RK, Bandyopadhyay U. Biological activities and medicinal properties of Neem (Azadiracht indica). Current Sci. 2002;82(11):1336-45.
13. Mahajan NG, Chopda MZ, Mahajan RT. A Review on Sphaeranthus Indicus Linn: Multipotential Medicinal Plant. Inte J Pharm Res Allied Sci. 2015;4(3):48-74.
14. Rafiquddin M, Kanz-ul-Advia Mufreda, 1st ed. Aligarh Muslim University, Aligarh; 1985.
15. Gupta M, Mahajan VK, Mehta KS, Chauhan PS. Zinc Therapy in Dermatology: A Review. Dermatol Res Pract. 2014;1-11.
16. Rangari P. Screening of Antibacterial Sensitivity of Essential Oils of Camphor and Cinnamon. Shodh Anusandhan Samachar. 2011;22-26.
17. Lee HJ, Hyun EA, Yoon WJ, Kim BH, Rhee MH, Kang HK, et al. In vitro anti-inflammatory and anti-oxidative effects of Cinnamomum camphora extracts. J of Ethnopharmacology. 2006;103:208-16.
18. Khan MS, Lari QH, Khan MA. Therapeutic Uses of Mom Zard (beeswax) in Unani System of Medicine - A Review. J Anal Pharm Res. 2016;3(1):00044.

19. Moustafa A, Atiba A. The Effectiveness of a mixture of honey, beeswax and olive oil in treatment of canine deep second-degree burn. *IDOSI*. 2015;14(2):244-50.
20. Pusadkar PP, Kokiladevi E, Bonde SV, Mohite NR. Sesame (*Sesamum indicum* L.) Importance and its

High Quality Seed Oil - A Review. *Trends in Biosci*. 2015;8(15):3900-06.

**Cite this article as:** Khan MS. Effect of Unani formulations on frostbite induced gangrene: a case report. *Int J Res Dermatol* 2020;6:427-31.