

Original Research Article

Efficacy of ultrathin epidermal grafting followed by narrow band ultraviolet B therapy for stable vitiligo: a novel therapy

Lakshmi Kamcharla, Sahitya Tadi*, Rakesh Darla, Nageswaramma Sidhabathuni

Department of Dermatology, Venereology and Leprosy, Guntur Medical College, Guntur, Andhra Pradesh, India

Received: 18 January 2020

Revised: 01 February 2020

Accepted: 04 February 2020

***Correspondence:**

Dr. Sahitya Tadi,

E-mail: sahitya.tadi@gmail.com

Copyright: © the author(s), publisher and licensee Medip Academy. This is an open-access article distributed under the terms of the Creative Commons Attribution Non-Commercial License, which permits unrestricted non-commercial use, distribution, and reproduction in any medium, provided the original work is properly cited.

ABSTRACT

Background: Different surgical techniques in the form of tissue or cellular grafting procedures are used alone or in combination with narrow band ultraviolet B (NBUVB) to treat stable vitiligo resistant to medical treatment. The aim of the study was to assess the cosmetic results obtained with combination therapy of ultrathin split-thickness skin grafts and adjuvant NBUVB therapy in resistant, stable vitiligo.

Methods: Forty patients of stable vitiligo were treated with ultrathin split-thickness grafting and the patients were then put on NBUVB therapy. Extent of repigmentation and final cosmetic outcome at the recipient as well as donor sites were assessed.

Results: The initial evidence of repigmentation was noted in the second week after starting NBUVB. Results showed 85% of patients had more than 90% repigmentation and the overall cosmetic results at the recipient site was good to excellent in 90% patients at the end of NBUVB treatment. Perigraft halo of depigmentation was seen in five patients (12%) on the recipient site. Hypertrophic scarring was seen in two patients at the donor site.

Conclusions: Ultrathin split-thickness skin grafting, when combined with NBUVB therapy, leads to better cosmetic outcome with faster onset of repigmentation in resistant and stable vitiligo.

Keywords: Vitiligo, Ultrathin epidermal grafting, NBUVB

INTRODUCTION

Vitiligo is a common depigmenting disorder, characterized clinically by milky white macules, and histologically by an absence of functional melanocytes in the affected area.¹⁻³ Although medical management is the primary treatment of choice, there still remains a group which is refractory to all these medical lines of treatment. Segmental vitiligo as well as vitiligo distributed over acral parts and non-hairy areas respond poorly to medical therapies in general.⁴ Vitiligo that is stable and refractory to medical therapies can be treated by certain surgical procedures like tissue or cellular grafting techniques. These surgical procedures basically donate some viable

melanocytes to the affected area of depigmentation. These viable melanocytes are then stimulated by different means like photochemotherapy ultraviolet A (PUVA) or PUVAsol therapy, narrowband ultraviolet B (NBUVB), topical steroids, and even excimer laser treatment to cause melanin production and thereby resulting in repigmentation of the recipient area.⁵⁻¹²

Grafting procedures used in vitiligo can be divided into two main groups - tissue grafting and cellular grafting.¹³ As far as tissue grafting procedures are concerned, there is a wide choice in the form of miniature punch grafting, suction blister grafting, split-thickness skin grafting, and even follicular skin grafting.¹⁴⁻¹⁸ Each of these surgical

techniques has its own advantages as well as disadvantages.¹³ Miniature punch grafting is the simplest procedure to perform, but it is commonly associated with adverse effects like “cobble-stoning” and “polka-dot” appearance at the recipient site as well as some residual scarring at the donor site.¹⁹ Suction blister grafting is associated with an excellent cosmetic and color matching at the recipient site and it does not normally cause any scarring at the donor site as well, but the procedure is time consuming and can take care of only smaller areas of depigmentation in a single sitting.²⁰ Split-thickness skin grafting is another tissue-grafting procedure used in vitiligo which provides a good, cosmetically acceptable repigmentation at the recipient site and does not lead to significant scarring at the donor site as well.^{16,17,21,22} With ultrathin grafts without any dermal component present, excellent results can be achieved at both the recipient as well as donor sites.^{23,24}

The objective of the study is to evaluate the cosmetic outcome and the factors affecting the cosmetic results obtained with ultrathin split thickness skin grafts followed by NBUVB therapy in stable, resistant vitiligo.

METHODS

This prospective study was done on 40 patients suffering from stable vitiligo resistant to all medical lines of treatment.

Stability was defined as no progression of existing lesions, no appearance of fresh lesions, and no evidence of Koebner phenomenon over at least 1 year.¹³

The patients were recruited over a period of about 1 year (2017-2018) from the regular outpatient consultation or from the group receiving NBUVB phototherapy with resistant residual lesions in Guntur Government Hospital, Guntur.

Institutional ethical clearance was taken and informed or written consent was taken from all patients participated in the study.

Preprocedure preparation

The whole procedure at the donor as well as the recipient sites was done under the influence of a topical anesthetic cream (prilox cream) in almost all the patients.

Procedure

Donor site

Donor area was chosen based on color matching with recipient area. Anterior aspect of thigh is the most preferred area.

Table 1: Common donor site.

Site	Donor area
Periorbital areas and face, neck	Medial aspect of arm
Fingers and foot	Thighs and calf area.
Lips, areola, nipple, genital area	Color match

To take ultrathin epidermal grafts from the donor area, the skin over the donor area was stretched both proximally as well as distally by applying a tangential force and epidermal grafts of uniform thickness were obtained using blade held with a straight artery forceps. The artery forceps move to and fro on the skin surface with movement occurring at wrist joint. The quality of the grafts was gauged by means of their translucent nature and by their ability to float on the isotonic saline solution. Donor site was covered with epidermal growth factor.

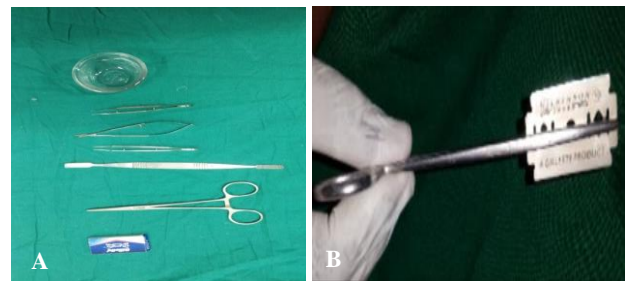


Figure 1: (A) Checklist of instruments, (B) blade held with artery forceps.

Recipient site

The recipient area was first cleaned with povidone iodine lotion and then dermabraded using motorized dermabrading apparatus. Dermabrasion was performed 0.5 mm beyond the margin of the recipient area to prevent any perigraft halo of depigmentation. The ultrathin epidermal grafts suspended in isotonic saline were then spread onto the dermabraded recipient sites with the help of glass slides and graft spreaders. The recipient area was then covered with double layer of antibiotic (chlorhexidine) coated gauze dressings and with dry collagen.

NBUVB therapy was started 3 to 5 days after removing the dressing and was given thrice a week on non-consecutive days according to set protocol. The initial dose of NBUVB was 200 mJ/cm² in all cases and the dose increments were 20% of the previous dose till faint erythema or perifollicular pigmentation was seen. NBUVB therapy was thus continued for a period ranging from 1 to 3 months, depending upon the response in an individual patient. The patients were followed up for a period ranging from 3 to 12 months, depending upon their response to treatment.

At the end of the study period, the response to treatment was evaluated objectively on the basis of the extent of repigmentation achieved as well as the cosmetic matching at the recipient site.

Statistical analysis

Sample size- weighted averages were calculated by dividing the total number of patients who achieved more than 75% pigmentation by the total number of patients in any particular category (e.g., age group, subtype of disease, or body part). A comparison of results in the above-described subgroups was done by means of chi-square contingency table. Significance was defined as $p > 0.05$.

RESULTS

All 40 patients were available for evaluation and belonged to Fitzpatrick skin type 3 or 4. A total of 56

lesions were treated, which were distributed on different sites of the body as given in Table 2. There were no adverse events to the phototherapy regimen.

Perigraft halo of depigmentation was the commonest complication of the surgical procedure, seen in 9 lesions in 12% of patients. Hyperpigmentation at recipient site is the second most common complication observed. Graft displacement was seen in two patients who underwent the procedure on lateral aspect of elbow. No patient in the study developed curling of the grafts or milia at the recipient site. Similarly, there was no scarring seen at the donor site in any other patient except those mentioned above.

The mean time to onset of repigmentation was 13 days (range, 9 to 19 days) after the start of NBUBV therapy. NBUBV was administered for a mean duration of 1.9 months (range, 1 to 2.8 months).

Table 2: Site of lesion and outcome.

Site	No of patients	>90% repigmentation	P value	No. of lesions	>90% repigmentation	P value
	N (%)	N (%)		N (%)		
Face including eyelids	16 (40)	16 (100)	0.9513 Not significant	20	20 (100)	0.9598 Not significant
Neck	2 (5)	2 (100)		4	3 (75)	
Upper limb including hands	10 (25)	6 (60)		12	8 (66.7)	
Trunk	6 (15)	5 (83.33)		12	10 (83.33)	
Lower limb including feet	6 (15)	5 (83.33)		8	6 (75)	
Total	40	34 (85)		56	47 (83)	

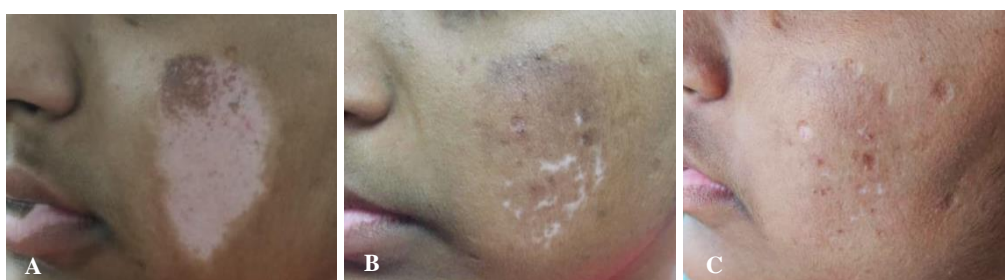


Figure 2 (A-C): Ultrathin epidermal skin graft (take up) over stable vitiligo patch over left cheek.

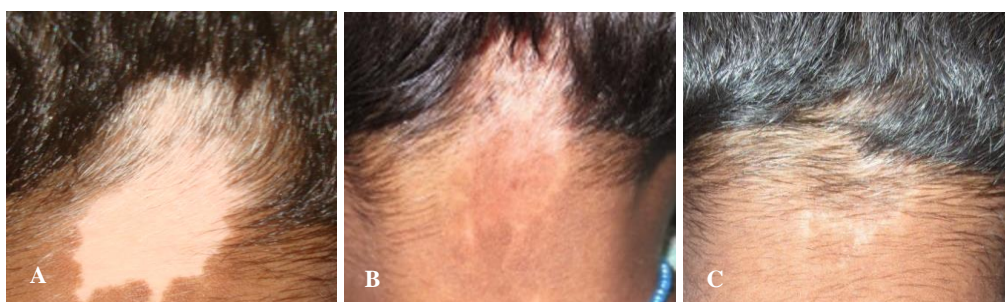


Figure 3 (A-C): Ultrathin epidermal skin graft (take up) over stable vitiligo patch over nape of neck.

About 85% (34 of 40) of patients achieved >90% repigmentation of the grafted lesions. Cosmetic matching was graded on visual analogue scale as good to excellent in 80% (32 of 40) cases.

As far as individual lesions were concerned, 47 (83%) lesions achieved >90% repigmentation in 34 patients (Table 2). Lesions on the face showed the best results, with all the 20 lesions in 16 patients achieving >90% repigmentation and a good cosmetic match. Lesions on the neck also showed really good results to the combination of ultrathin split thickness grafting with NBUVB. Eyelid lesions were grafted in few patients and all of them responded quite well (with >90% repigmentation) to the treatment regimen. We had patients in whom the procedure was performed on the breasts and both these patients (lesions in total) showed >90% repigmentation and excellent cosmetic match at the treatment sites. Areola or nipples were not involved in any of these two patients.

On the feet, a few patients underwent transplantation and majority (83.33%) of them responded with >90% repigmentation and an excellent color match. Even lesions on the ankle joints responded well to treatment. However, toe-tips or plantar skin was not involved in any of these patients.

There is no statistical significance correlating the cosmetic results achieved with the site of the treated lesion. However, the face and neck was seen to respond the best. Lesions on the elbows, ankles, and neck required special precautions to keep the grafts undisplaced.

In our series, composition of each subgroup on the basis of age, sex, type, stability of vitiligo was correlated with the cosmetic outcome of the therapy and found no statistically significant association (Table 3-5). However, the results were better in patients with focal or segmental type of disease and in younger patients than those with generalized type of disease and older age.

Table 3: Age and outcome.

Age (in years)	No of patients (%)	>90% repigmentation (%)	P value
10-20	19 (47.5)	17 (89.4)	0.9655 Not significant
21-30	12 (30)	11 (91.6)	
31-40	6 (15)	4 (66.6)	
41-50	3 (7.5)	2 (75)	

Table 4: Sex and outcome.

Sex	No of patients (%)	>90% repigmentation (%)	P value
Female	26 (65)	22 (84.6)	0.9789 Not significant
Male	14 (35)	12 (85.7)	

Table 5: Type of vitiligo and outcome.

Type	No of patients (%)	>90% repigmentation (%)	P value
Focal	24 (60)	22 (91.6)	0.7977 Not significant
Segmental	12 (30)	10 (83.3)	
Acro-facial	4 (10)	2 (50)	

DISCUSSION

It is well known that the response of vitiligo to medical therapies is not uniform on various body parts, in different subtypes of the disease, and in different age groups. An analysis of therapeutic response to various treatment modalities in 130 children and 415 adults with vitiligo showed better response in children to all treatment modalities.²⁵ Similarly, meta-analysis of literature has shown that the segmental form of vitiligo does not respond to medical therapies as readily as the generalized type of disease.²⁶ The response to psoralen-UVA therapy (mainstay of medical therapies for vitiligo) also varies with anatomic regions; the face being the most responsive and distal parts of extremities the least responsive.²⁷

Vitiligo that is stable and does not respond to medical lines of treatment can be managed by certain surgical procedures in the form of tissue or cellular grafting techniques. Split thickness skin grafting offers certain advantages over other tissue grafting procedures. However, with ultrathin grafts having no accompanying dermal tissue, the cosmetic outcome achieved at both recipient as well as donor site is usually excellent. The grafts that we used in the present study were all translucent grafts without any whitish tissue at the base. We laid emphasis on the translucent quality of the grafts obtained and not on the overall size of the grafts.

With the use of ultrathin grafts, there are minimal chances of scarring at the donor site owing to the loss of epidermis alone from the area. We have observed that if

one is able to achieve an ultrathin graft at the donor site, the same site can even be repeatedly used for taking similar grafts in the future. In fact, in our experience we have observed that it becomes easier to obtain a graft at the next session as the epidermis gets easily separated once it has regrown over the already-used donor area.

However, response to various surgical therapies in these subgroups is not known because no published study has researched this aspect. Our results and analysis of the literature on epidermal grafting has shown a trend of better response in younger individuals. The reasons for this are not exactly clear. It has been seen that younger persons have hypertrophic scar and keloids develop more often in response to injury than do older adults. This may be a result of excessive release of cytokines and other growth factors like interleukin-1, platelet-derived growth factor, and basic fibroblast growth factor in younger individuals, which stimulates the fibroblasts to multiply and synthesize more collagen.²⁸ Some of these growth factors and cytokines (e.g., basic fibroblast growth factor) produced during wound healing also stimulate melanocytes, probably leading to better pigmentation (after epidermal grafting) in younger individuals.²⁹ Support for better response in younger people also comes from the observation that melanocytes from younger persons proliferate better in culture than those from older people.^{30,31}

Unlike the medical therapies, the response of focal/segmental vitiligo is known to be better with epidermal grafting. Suga et al observed that in generalized vitiligo, the area of repigmentation was smaller and less homogenous compared with that of segmental or focal vitiligo.³² Hatchome et al treated 7 patients with focal/segmental and 11 patients with generalized vitiligo with epidermal grafting. Although all (100%) the patients with focal or segmental vitiligo achieved repigmentation, only 7 of 11 (63.6%) patients with generalized vitiligo could achieve satisfactory repigmentation.³³ The poorer response may be explained on the basis of differences in the immunologic pathogenesis of generalized and localized vitiligo.³⁴ There are reports of easier cultivation of melanocytes from localized vitiligo in comparison with those from generalized vitiligo.³⁵ The segmental/focal subtype of the disease is more stable in nature than the generalized type. Mostly because of this, many surgeons recommend the grafting procedure in only focal or segmental type of disease.³³

No definite pattern of results regarding different body parts was observed by us or reported in the literature. The difference in the outcome on various body parts was not statistically significant. Thus, the lesions on the distal extremities, which respond poorly to medical therapies, respond to epidermal grafting as favourably as lesions on any other site.

From our observations it is evident that outcome is not markedly affected by stability of the disease longer than 1 year. Thus, it is recommended that to reduce the anxiety of the patient, the procedure should be performed any time after 1-year stability; a longer wait in the hopes of better outcome is not warranted.

Grafting procedures are supplemented with NBUVB or PUVA to increase the chances of repigmentation as well as to achieve quicker results.⁵⁻¹⁰ NBUVB scores over PUVA as a treatment option in vitiligo as it is safer and does not require post-treatment protection from sun exposure. Another advantage of NBUVB is that it can be used safely in children as well.²⁵ NBUVB is thought to have a proliferative as well as a stimulatory effect on the melanocytes donated through the grafting procedure. Thus, one can achieve a rapid repigmentation when it is used as a supplementary therapy along with any grafting procedure. NBUVB has been used in combination with mini-punch grafting with good results.⁸ It has also been used after autologous epidermal cell culture procedure in resistant vitiligo with gratifying results.⁹

Clinical studies have shown that in case of split-thickness skin grafting, supplemental NBUVB not only causes a rapid repigmentation but also minimizes the chances of perigraft depigmentation.²⁴ Even excimer laser with its monochromatic 308 nm wavelength has been used in combination with split-thickness skin grafting and the authors have reported really good and early results with this combination.¹² What we have observed in our patient's that if ultrathin split-thickness skin grafting is followed immediately by a course of NBUVB, the onset of repigmentation is quite rapid as we have been able to see an evidence of repigmentation as early as the second week after the start of NBUVB regimen. Moreover, the color match achieved at the recipient site is also improved.

CONCLUSION

Split-thickness skin grafting is claimed to be the most successful tissue-grafting procedure in vitiligo and this has been our observation as well. With the use of ultrathin skin grafts, the outcome at both the donor as well as the recipient sites can be improved further. The procedure, when performed in carefully selected patients with a proper technique, can certainly provide excellent cosmetic results in resistant stable vitiligo. Concurrent use of NBUVB therapy gives faster and better cosmetic results.

ACKNOWLEDGEMENTS

We would like to thank Dr John Evtus.

Funding: No funding sources

Conflict of interest: None declared

Ethical approval: Not required

REFERENCES

- Mattoo SK, Handa S, Kaur I, Gupta N, Malhotra R. Psychiatric morbidity in vitiligo: Prevalence and correlates in India. *J Eur Acad Dermatol Venereol.* 2002;16:573-8.
- Aghaei S, Sodaifi M, Jafari P, Mazharinia N, Finlay AY. DLQI scores in vitiligo: Reliability and validity of the Persian version. *BMC Dermatol.* 2004;4:8.
- Kovacs SO. Vitiligo. *J Am Acad Dermatol.* 1998;38:647-66.
- Njoo MD, Spuls PI, Bos JD, Westerhof W, Bossuyt PM. Nonsurgical repigmentation therapies in vitiligo: Meta-analysis of the literature. *Arch Dermatol.* 1998;134:1532-40.
- Hann SK, Im S, Bong HW, Park YK. Treatment of stable vitiligo with autologous epidermal grafting and PUVA. *J Am Acad Dermatol.* 1995;32:943-8.
- Awad SS, Abdel-Raof H, Hosam El-Din W, El-Domyati M. Epithelial grafting for vitiligo requires ultraviolet-A phototherapy to increase success rate. *J Cosmet Dermatol.* 2007;6:119-24.
- Savant SS. Surgical therapy of vitiligo: Current status. *Indian J Dermatol Venereol Leprol.* 2005;71:307-10.
- Lahiri K, Malakar S, Sarma N, Banerjee U. Repigmentation of vitiligo with punch grafting and narrow-band UV-B (311 nm) a prospective study. *Int J Dermatol.* 2005;45:649-55.
- Lahiri K, Malakar S. Inducing repigmentation by regrafting and phototherapy (311 nm) in punch failure cases of lip vitiligo: A pilot study. *Indian J Dermatol Venereol Leprol.* 2004;70:156-8.
- Elisa P, Massimiliano R, Andre A, Paolo T, Francesca I, Lucio A. Autologous epidermal cultures and narrow-band ultraviolet B in the surgical treatment of vitiligo. *Dermatol Surg.* 2005;31:155-9.
- Barman KD, Khaitan BK, Verma KK. A comparative study of punch grafting followed by topical corticosteroid versus punch grafting followed by PUVA therapy in stable vitiligo. *Dermatol Surg.* 2004;30:49-53.
- Al-Mutairi N, Manchanda Y, Al-Doukhi A, Al-Haddad A. Long-term results of split-skin grafting in combination with excimer laser for stable vitiligo. *Dermatol Surg.* 2010;36:499-505.
- Parsad D, Gupta S. Standard guidelines of care for vitiligo surgery. *Indian J Dermatol Venereol Leprol.* 2008;74:37-45.
- Falabella R. Repigmentation of stable Leukoderma by autologous mini-grafting. *J Dermatol Surg Oncol.* 1986;12:172-9.
- Gupta S, Shroff S, Gupta S. Modified technique of suction blistering of epidermal grafting in vitiligo. *Int J Dermatol.* 1999;38:306-9.
- Kahn AM, Cohen MJ. Repigmentation in vitiligo patients- melanocytes transfer via ultra-thin grafts. *Dermatol Surg.* 1998;24:365-7.
- Achauer BM, Le Y, Vander Kam VM. Treatment of vitiligo with melanocytic grafting. *Ann Plast Surg.* 1994;33:644-6.
- Na GY, Seo SK, Choi SK. Single hair grafting for the treatment of vitiligo. *J Am Acad Dermatol.* 1998;38:580-4.
- Babu A, Thappa DM, Jaisankar TJ. Punch grafting versus suction blister epidermal grafting in the treatment of stable lip vitiligo. *Dermatol Surg.* 2008;34:166-78.
- Falabella R. Surgical therapies for vitiligo and other leukodermas, part 1: Minigrafting and suction epidermal grafting. *Dermatol Ther.* 2001;14:7-14.
- Agrawal K, Agrawal A. Vitiligo: Repigmentation with dermabrasion and thin split-thickness skin graft. *Dermatol Surg.* 1995;21:295-300.
- Njoo MD, Westerhof W, Bos JD, Bossuyt PM. A systematic review of autologous transplantation methods in vitiligo. *Arch Dermatol.* 1998;134:1543-9.
- Olsson M, Juhlin L. Long-term follow-up of leukoderma patients treated with transplants of autologous cultured melanocytes, ultra-thin epidermal sheets and basal cell layer suspension. *Br J Dermatol.* 2002;47:893-904.
- Khunger N, Kathuria SD, Ramesh V. Tissue grafts in vitiligo surgery - Past, present, and future. *Indian J Dermatol.* 2009;54:150-8.
- Grimes PE, Billips M. Childhood vitiligo: clinical spectrum and therapeutic approach. In: Hann SK, Nordlund JJ, editors. *Vitiligo, a monograph on the basic and clinical science.* Oxford: Blackwell Science; 2000: 61-69.
- Njoo MD, Spuls PI, Bos JD, Westerhof W, Bossuyt PM. Nonsurgical repigmentation therapies in vitiligo, meta-analysis of the literature. *Arch Dermatol.* 1998;134:1532-40.
- Morrison WL. PUVA therapy. In: Hann SK, Nordlund JJ, editors. *Vitiligo, a monograph on the basic and clinical science.* Oxford: Blackwell Science; 2000: 168-172.
- Niessen FB, Andriessen MP, Schalkwijk J, Visser L, Timens W. Keratinocyte-derived growth factors play a role in the formation of hypertrophic scars. *J Pathol.* 2001;194:207-16.
- Halaban R. The regulation of normal melanocyte proliferation. *Pigment Cell Res.* 2000;13:4-14.
- Abdel-Malek ZA, Swope VB, Nordlund JJ, Medrano EE. Proliferation and propagation of human melanocytes in-vitro are affected by donor age and anatomical site. *Pigment Cell Res.* 1994;7:116-22.
- Gilchrist BA, Vrabel MA, Flynn E, Szabo G. Selective cultivation of human melanocytes from newborn and adult epidermis. *J Invest Dermatol.* 1984;83:370-6.
- Suga Y, Butt KI, Takimoto R, Fujioka N, Yamada H, Ogawa H. Successful treatment of vitiligo with PUVA-irradiated autologous epidermal grafting. *Int J Dermatol.* 1996;35:518-22.

33. Hatchome N, Kato T, Hachiro T. Therapeutic success of epidermal grafting in generalized vitiligo is limited by Koebner phenomenon. *J Am Acad Dermatol.* 1990;22:87-91.
34. Koga M, Tango T. Clinical features and course of type A and type B vitiligo. *Br J Dermatol.* 1988;118:223-8.
35. Jee SH, Kuo YF, Wu YC, Chang CH, Kuo WL, Lu YC. Growth of human melanocytes from suction blister of localized vitiligo patient and from

foreskins of newborns and adults by modified culture medium. *J Formos Med Assoc.* 1993;92:7-14.

Cite this article as: Kamcharla L, Tadi S, Darla R, Sidhabathuni N. Efficacy of ultrathin epidermal grafting followed by narrow band ultraviolet B therapy for stable vitiligo: a novel therapy. *Int J Res Dermatol* 2020;6:167-73.