

Original Research Article

Trichoscopy in common scalp alopecia: an observational study

Krishnendra Varma, Ujjwal Singh, Manu Kataria*

Department of Dermatology, Venerology and Leprology, R.D. Gardi Medical College, Ujjain, Madhya Pradesh, India

Received: 12 January 2020

Revised: 09 March 2020

Accepted: 17 March 2020

*Correspondence:

Dr. Manu Kataria,

E-mail: livemanu@gmail.com

Copyright: © the author(s), publisher and licensee Medip Academy. This is an open-access article distributed under the terms of the Creative Commons Attribution Non-Commercial License, which permits unrestricted non-commercial use, distribution, and reproduction in any medium, provided the original work is properly cited.

ABSTRACT

Background: Many patients of alopecia are encountered in daily practice with diagnostic dilemma. Trichoscopy is a sensitive, non-invasive tool which aids in clinical diagnosis.

Methods: An observational study performed in adult patients with alopecia attending R.D. Gardi Medical College, Ujjain, over a period of one year. Trichoscopy was performed using a Dinolite digital microscope with both polarized and non polarized modes.

Results: 269 patients of alopecia (257 non cicatricial, 12 cicatricial) aged 18-50 years were enrolled. The diagnosis was made after detailed history and clinical examination. 173 (64.3%) males and 96 (35.7%) females. 45.4% patients were diagnosed to have alopecia areata in which yellow dots were the most common trichoscopic finding observed in 88.5% patients. 37.2% patients were diagnosed with androgenetic alopecia with hair diameter diversity >20% observed in all the patients. 9.3% patients were diagnosed to have telogen effluvium with short vellus hair seen in 64% patients. 3.7% of the patients were diagnosed to have seborrheic dermatitis with arborizing vessels being the most common finding seen in 90% patients. 2.9% patients were diagnosed with lichen planopilaris in which loss of follicles and peritubular white casts were seen in all the cases. 0.9% patients were diagnosed to have discoid lupus erythematosus with hyperkeratotic follicular plugging seen in all the cases. Overall yellow dots were the most common trichoscopic findings seen in 61% cases.

Conclusions: Trichoscopy is a reliable diagnostic tool in hair and scalp disorders. Hence trichoscopic evaluation should be done in every case of alopecia.

Keywords: Trichoscopy, Alopecia areata, Androgenetic alopecia, Telogen effluvium, Discoid lupus erythematosus, Lichen planopilaris

INTRODUCTION

Hair loss also known as alopecia refers to loss of hair from any part of the scalp or body. Most commonly the scalp is involved. With progression of hair loss over time it may become cosmetically unacceptable and psychologically frustrating to the patient. Losing hair is not usually a health threatening condition nevertheless it can affect a patient's self-esteem by inciting enormous psychological and emotional distress. There are many hairs related and unrelated conditions of the scalp which can result in loss of hair which can be permanent in

certain diseases.¹ Broadly alopecia can be classified into two categories.² Non cicatricial (reversible) alopecia and cicatricial (irreversible) alopecia. Common causes of non-cicatricial alopecias are: androgenetic alopecia, telogen effluvium, alopecia areata, trichotillomania, tinea capitis, anagen effluvium. while Common causes of cicatricial alopecia are: lichen planopilaris, discoid lupus erythematosus, frontal fibrosing alopecia, pseudopalaed of brocq, folliculitis decalvans, bacterial folliculitis and dissecting cellulitis of scalp.

There are various diagnostic modalities for diagnosing hair loss. Trichoscopy (dermoscopy of scalp) is a recent, novel, sensitive, non-invasive modality which provides rapid detection of hair and scalp disorders with diagnostic accuracy. The basic principle of trichoscopy is illumination and transillumination of skin or a lesion with different light source and studying it with a high magnification lens.³ Trichoscopic evaluation of normal and diseased scalp is based on observing Follicular patterns or dots, Interfollicular pattern which consists of visualization of pigments and vascular pattern, and Hair signs.^{2,4}

'Dots' are small, round hair follicle openings seen on trichoscopy. Yellow dots are seen as yellow colored round or polycyclic dots, and represent follicular infundibulum, distended with degenerating keratinocytes and sebum. Although characteristic of alopecia areata, yellow dots are also seen in androgenetic alopecia, discoid lupus erythematosus, dissecting cellulitis of scalp, etc.^{3,5} Black dots are seen within the yellow dots and represent broken pigmented hair (cadaverized hair), that are fractured before emerging from the scalp. Commonly found in trichotillomania, alopecia areata, tinea capitis, etc. They are not seen in healthy scalp.^{6,7}

White dots may appear as the classic, big, irregular white dots, seen around hair follicles, denote areas of perifollicular fibrosis, observed commonly in folliculocentric cicatricial alopecias, like in lichen planopilaris. They are formed due to destruction of hair follicles followed by fibrosis. The pinpoint white dots are small and regular. They correspond to empty hair follicles or to the eccrine sweat duct's openings. These are normal scalp findings.⁸

Red dots seen around the hair follicles in some patients of active discoid lupus erythematosus. They represent increased follicular blood supply and their presence signify a better prognosis with respect to hair regrowth.^{8,9}

Androgenetic alopecia (AGA) is characterized by hair diameter diversity due to miniaturization of the hair follicles. Variability in hair shafts diameter of more than 20% is diagnostic of this condition. Peripilar brown depressions known as peripilar sign is a specific feature of early AGA. In patients with advanced androgenetic alopecia, yellow dots can be observed and the sun-exposed scalp often shows the honeycomb pigment pattern. All these changes are more prominent in the frontal scalp and there is no significant difference in the findings in male and female pattern hair loss.^{10,11}

Trichoscopic findings of alopecia areata (AA) includes black dots, fractured hair shafts, exclamation mark hair, caudable hair, short vellus hair, coiled regrowing hair, and tapering hair.¹²

Trichoscopic findings of Telogen Effluvium are non-specific and includes empty hair follicles, short

regrowing hair, and hair diameter diversity less than 20%. These findings are distributed all over the scalp with no significant difference between frontal and occipital areas.¹³ Chronic telogen effluvium can be easily differentiated from pattern hair loss by absence of hair diameter diversity and peripilar halo.

Trichoscopic features of seborrheic dermatitis are atypical red vessels, arborizing vessels, and scales.

On trichoscopy lichen planopilaris is characterized by irregular white dots or areas that represent the fibrotic hair follicles and absent hair follicles. In the periphery of the lesion there are characteristic perifollicular scales and casts. Blue grey pigmentation in a 'targetoid' pattern may be seen around hair follicles. The interfollicular areas are spared.^{14,15}

Trichoscopic features of discoid lupus erythematosus (DLE) includes large yellow dots with or without keratin plugs, thick arborizing vessels, peripilar erythema and scaling, white patches and decreased follicular ostia.¹⁵

The objective of the study was to study the trichoscopic features of different types of alopecia in adult population and to assess the utility of trichoscopy in diagnosis of alopecia.

METHODS

The study was a cross sectional observational study conducted in the department of dermatology, venereology and leprosy, R.D. Gardi medical college and C.R. Gardi hospital, Ujjain (M.P.), between January 2017-19. For this study alopecia was defined as visible thinning and loss of hair from the scalp. Male and female patients between the age group of 18-50 years were included after taking informed consent. Hair loss due to external injury, chemotherapy or any drugs and systemic illness and hair shaft disorders were excluded.

In every patient a detailed history was elicited and recorded on a proforma, and relevant clinical examination was performed, following which trichoscopic examination was performed using a DINOLITE digital microscope system with adjustable polarization flexible LED system equipped with a video camera with lenses providing magnifications ranging from 20X to 220X. All patients were studied clinically and relevant data was recorded. Microsoft excel was used for data entry and analysis was done using SPSS version 23.

RESULTS

A total of 269 patients were enrolled. There were 173 males (64.3%) and 96 females (35.7%) as shown in (Table 1). The male to female ratio was 1.8:1. Majority of the patients were in the age group of 21-30 years (45%), followed by 31-40 years (25.7%). Overall, the age group of 21-40 years was affected the most (69.7%). 96%

patients presented with non scarring alopecia while 4% had scarring alopecia. Table 2, represents the distribution pattern of individual alopecia.

Table 1: Distribution of the patients according to gender.

Gender	Frequency	Percent
Male	173	64.3
Female	96	35.7
Total	269	100.0

Table 2: Distribution of individual alopecia.

Diagnosis	Total patients (%)
AA	122 (45.4)
AGA	100 (37.2)
TE	25 (9.2)
SD	10 (3.7)
LPP	8 (2.9)
DLE	2 (0.7)
Pseudopalade	2 (0.7)
Total	269 100.0

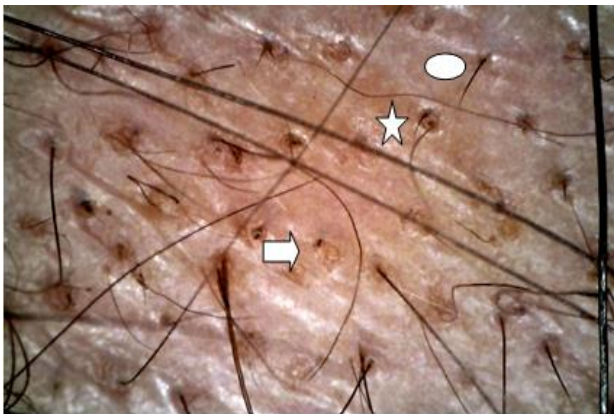


Figure 1: Yellow dots (arrow), short vellus hair (star), and short regrowing hair (circle).

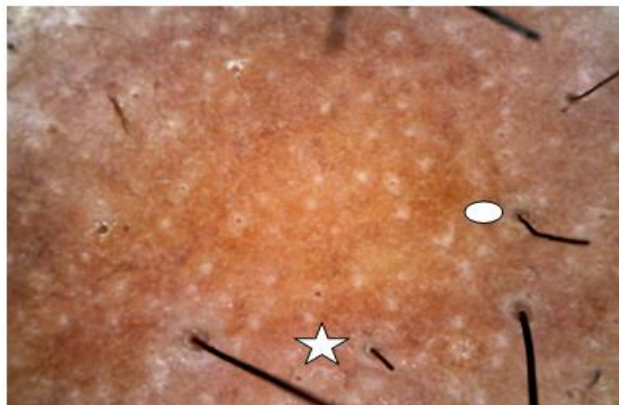


Figure 2: Broken hair (star) and caudability hair (circle).

Total 122 (45.4%) of the cases had alopecia areata (Table 2). On trichoscopic examination the most common finding was yellow dots (88.5%) followed by short vellus hair (54.1%), short re-growing hair (47.5%), exclamation mark hair (45.9%), black dots (36.1%) and broken hair (27.9%) Figure 1, 2, 3, and 4.

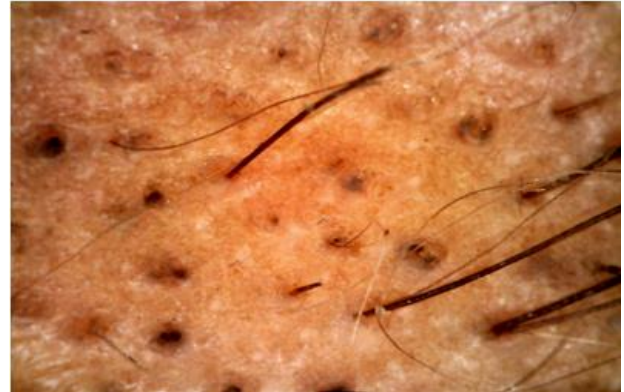


Figure 3: Black dots and broken hair.

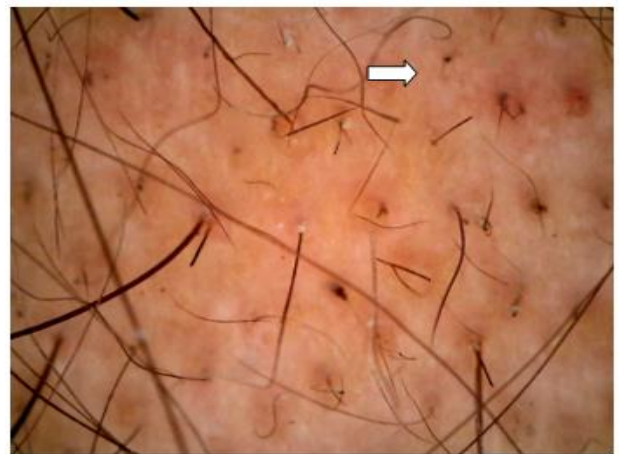


Figure 4: Multiple exclamation mark hair.

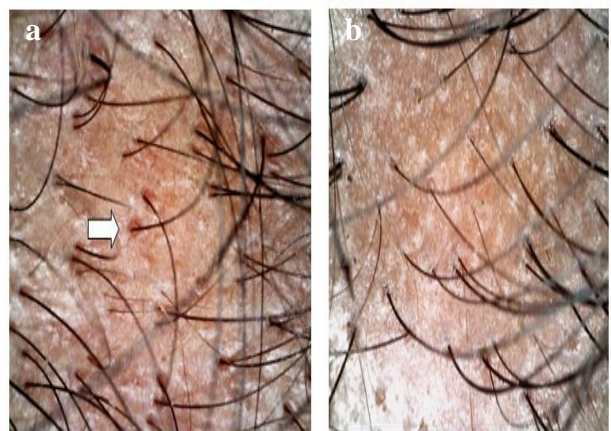


Figure 5: (a) Peri-pilar sign and (b) single follicles and short vellus hair.

AGA was seen in 100 (37.2%) patients. On trichoscopic evaluation the most common finding was peripilar sign (77%) followed by short vellus hair (75%), honey comb pigmentation (46%), single follicular units (40%) and yellow dots (37%). In Androgenetic alopecia hair diameter diversity of more than 20% was used as the diagnostic criteria and so it was present in all the cases Figure 5 (a and b).

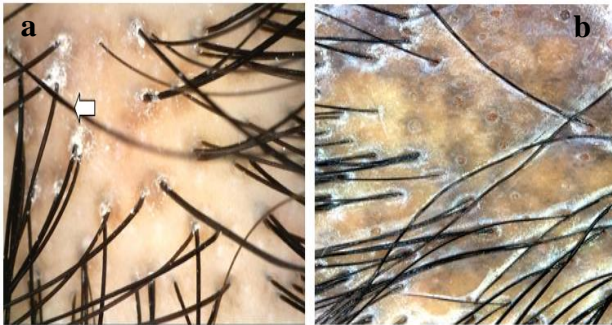

Figure 6: (a) Peri follicular scales (arrow) white fibrotic areas and (b) peri follicular pigment.

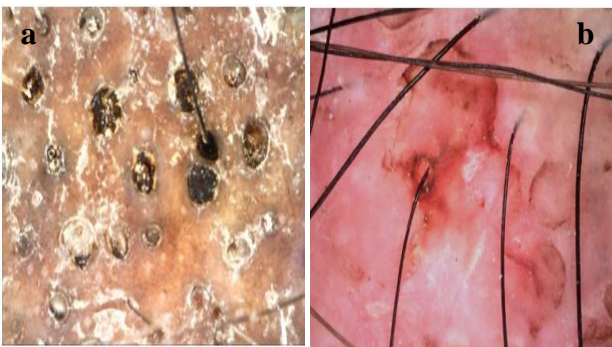


Figure 7: (a) Keratin filled follicles and (b) peri follicular erythema.

LPP was seen in 8 (2.9%) patients. On trichoscopy of lichen plano pilaris, white areas of fibrosis leading to loss of follicular ostia were seen in all the cases. Peri-tubular white cast around the existing hair shafts was also found in all the cases. Arborizing vessels were seen in 87.5% cases while peri follicular blue grey pigmentation and inter-follicular speckled pigmentation were seen in 62.5% cases and 12.5% cases respectively. Yellow dots were seen at the margin of the lesions in all the cases Figure 6 (a and b).

DLE was seen in 2 (0.7%) patients. Yellow dots with keratin plug and scales, thick arborizing vessels and perifollicular erythema were seen in both the cases Figure 7 (a and b).

Telogen effluvium was seen in 25 (9.2%) of the cases. On trichoscopy short vellus hair were seen most frequently (64%) followed by short re-growing hair (48%). Yellow dots were found in 28% cases while peri pilar halo was found in 12% cases.

Seborrheic dermatitis was seen in 3.7% cases of alopecia. On trichoscopy arborizing vessels were the most common finding seen in 90% patients. Yellow scales were more commonly seen than the white scales.

Overall yellow dots were the most common trichoscopic findings in the present study seen in 61% cases. Yellow dots were most commonly seen in alopecia areata (88.5%) followed by androgenetic alopecia (37%), telogen effluvium (28%) and seborrheic dermatitis.

DISCUSSION

In our study non cicatricial alopecia (258 cases) outnumbered the cicatricial alopecia (11 cases). The prevalence of alopecia in India has been measured for the major group of alopecia but there is not sufficient literature regarding the percentage distribution of each type. AGA is considered to be the commonest cause of alopecia worldwide followed by AA.¹⁶ In our study most common pattern observed was of Alopecia areata seen in 45.4% patients followed by androgenetic alopecia (37.2%), telogen effluvium (9.3%), seborrheic dermatitis (3.7%) and lichen planopilaris (2.9%). This frequency pattern in our study was in concordance with two similar India based studies conducted by Vora et al and Manmohan et al.^{17,18.}

In AA, the most common trichoscopic findings in our study were yellow dots (88.5%) followed by short vellus hair (54.1%), which is in comparison with study conducted by Chiramel et al where yellow dots were observed in 87.5% (20/24) patients and short vellus hair were observed in 50% (12/24) patients.¹⁹ Similar pattern was observed in a study conducted by Thapa et al in which yellow dots and short vellus hair were observed in 81.8% and 40.9% patients respectively.²⁰ In the largest trichoscopic study of 300 Asian patients with alopecia areata published by Inui et al yellow dots were observed in 63.7% patients, while Ross et al reported yellow dots in 94.8 (55/58) patients.^{8,21} These differences can be attributed to the different shampooing practices and hair care products usage. In our study 58 (47.5%) patients had short re-growing hair while Inui et al demonstrated them in 31.7% patients.²¹ Exclamation mark hair were seen in 31.7% (95/300) cases by Inui et al and 12.1% (8/66) cases by Mane et al.^{8,22} In our study they were seen in 56 (45.9%) patients. In the present study Black dots were observed in 44 (36%) patients while Inui et al demonstrated them in 44.3% (133/300) patients and Mane et al in 67.7% (44/66) patients.^{8,22} Broken hair were seen in 34 (27.9%) patients in our study which were less frequent as compared to Inui et al (45.7%) and Mane et al (55.4%).^{8,22}

A total of 100 patients were diagnosed with AGA in our study. On trichoscopy all the cases demonstrated HDD >20% as this was the diagnostic criterion for AGA. This finding is in concordance with previous studies done by Tosti et al in 2005 and Inui et al in 2011.^{12,8}

Occurrence of peripilar sign in our study matched with studies done by Inui et al.⁸ who reported PFP in 63% patients. Although our findings were not in concordance with similar Indian studies done by Chiramel et al and Vora et al.^{19,17}

In our study short vellus hair were seen in 75% of the patients which is comparable to studies done by Inui et al.⁸

The percentage of patients with AGA having yellow dots were 37% which was comparable to studies done by Inui et al but much lower than studies done by Chiramal et al and Vora et al.^{8,19,17}

In the present study out of total 25 cases of TE, the most common Trichoscopic finding was short vellus hair (64%) followed by short regrowing hair (48%), yellow dots (28%) and peri pilar halo (12%). There was minimal variation in thickness of hair and hair HDD <20% was the diagnostic criteria of TE in our study. These findings were comparable to a similar study conducted by Chiramel et al.¹⁹

A total of 10 patients with SD were enrolled in our study. On trichoscopic examination the most common finding was thin arborizing vessels (90%) followed by yellow scales (60%) and white scales (40%). These findings were consistent with those by Widaty et al in which the most common finding was thin arborizing vessels (40%) followed by yellow scales and white scales.²³

In the present study, out of 12 cases of scarring alopecia 8 cases had LPP. On trichoscopy all (100%) the cases had yellow dots, white structure less areas, loss of ostia, peritubular casts and scales. Perifollicular erythema was seen in 87.5% cases while 62.5% cases had blue grey dot pigmentation. These findings were comparable to study done by Chiramel et al, in which 100% cases had loss of follicular ostia followed by white areas (87.5%), blue grey dot (56.3%), yellow dots (50%), peri pilar casts and scales (43%).¹⁹ Duque Estrada et al reported perifollicular scales in 100% of patients.²⁴

Trichoscopic findings in DLE included yellow dots, thick keratin plugs and scales which were seen in all the cases.

Overall yellow dots were the most common trichoscopic findings in the present study seen in 61% cases, and were most commonly seen in alopecia areata (88.5%) followed by androgenic alopecia (37%), telogen effluvium (28%). Chiramel et al from north India, reported yellow dots in 87.5% of alopecia areata, 44.5% of female pattern hair loss, and 30% of telogen effluvium.¹⁹

CONCLUSION

Trichoscopy is a very simple, cost effective and a non-invasive diagnostic tool in hair and scalp disorders. It can help forming and confirming the diagnosis on the basis of

its characteristics finding. It is relatively easy to acquire the skill and expertise needed for trichoscopy as it can be mastered by all those with a keen eye to observe. Hence trichoscopic evaluation should be done in every case of alopecia.

Limitations

This study conducted in a single city with a sample size of 269 cannot be extrapolated to the general population. Moreover, number of patients were limited in certain types of alopecia.

Funding: No funding sources

Conflict of interest: None declared

Ethical approval: The study was approved by the institutional ethics committee

REFERENCES

1. Rudnicka L, Olszewska M, Rakowska A, Oledzka KE, Slowinska M. Trichoscopy: A new method for diagnosing hair loss. *J Drugs Dermatol.* 2008;7:651-4.
2. Rudnika L, Olzewska M, Slowinska M. Trichoscopy update. *J Dermatol Case Rep.* 2011;4:82-8.
3. Ross EK, Vincenzi C, Tosti A. Videodermoscopy in the evaluation of hair and scalp disorders. *J of the American Academy of Dermatol.* 2006;55(5):799-806.
4. Rudnicka L, Olszewska M, Rakowska A. Atlas of Trichoscopy Dermoscopy in Hair and Scalp Disease. Springer. 2012.
5. Tosti A, Estrada DB. Dermoscopy in hair disorders. *J Egypt Womens Dermatol Soc.* 2010;7:1-4.
6. Oledzka KE, Slowinska M, Rakowska A, Czuwara J, Sicinska J, Olszewska M, et al. 'Black dots' seen under trichoscopy are not specific for alopecia areata: Black dots in trichoscopy. *Clin Exp Dermatol.* 2012;37(6):615-9.
7. Black dots in trichoscopy. *Clin Exp Dermatol.* 2012;37(6):615-9.
8. Inui S, Nakajima T, Nakagawa K, Itami S. Clinical significance of dermoscopy in alopecia areata: analysis of 300 cases. *Int J Dermatol.* 2008;47(7):688-93.
9. Naveen K, Athanikar S, Reshme P, Hegde S. Clinical and dermatoscopic patterns of alopecia areata: A tertiary care centre experience. *Int J Trichology.* 2013;5(3):132.
10. Rakowska A, Slowinska M, Oledzka KE, Olszewska M, Rudnicka L. Dermoscopy in female androgenic alopecia: Method standardization and diagnostic criteria. *Int J Trichology.* 2009;1(2):123.
11. Sinclair R. Male pattern androgenetic alopecia. *BMJ.* 1998;317:865-9.
12. Ankad B. Trichoscopy of Alopecia Areata: A Diagnostic Aide. 2014;04(03).

13. Harrison S, Sinclair R. Telogen effluvium. *Clin Exp Dermatol.* 2002;27:389-5.
14. Rakowska A, Slowinska M, Oledzka KE, Warszawik O, Czuwara J, Olszewska M, et al. Trichoscopy of cicatricial alopecia. *J Drugs Dermatol JDD.* 2012;11(6):753-8.
15. Estrada DB, Estrada BD, Tamler C, Sodre CT, Barcaui CB, Pereira FBC. Dermoscopy patterns of cicatricial alopecia resulting from discoid lupus erythematosus and lichen planopilaris. *A Bras Dermatol.* 2010;85(2):179-83.
16. Kaliyadan F, Nambiar A, Vijayaraghavan S. Androgenetic alopecia: An update. *Indian J Dermatol Venereol Leprol.* 2013;79:613-25.
17. Vora RV, Pilani AP, Kota RKS, Singhal RR, Patel TM, Bhavsar ND. Trichoscopic findings in various Scalp Alopecias. *Indian J Clin Dermatol.* 2017;1:53-8.
18. Patil VS. Considerations while operating maxillofacial surgeries in a pregnant patient: A research review. *IOSR J Dent Med Sci.* 2019;18(1):29-31.
19. Chiramel MJ, Sharma VK, Khandpur S, Sreenivas V. Relevance of trichoscopy in the differential diagnosis of alopecia: A cross-sectional study from North India. *Indian J Dermatol Venereol Leprol.* 2016;82:651-8.
20. Thappa D, Mane M, Nath A. Utility of dermoscopy in alopecia areata. *Indian J Dermatol.* 2011;56(4):407.
21. Ross EK, Vincenzi C, Tosti A. Videodermoscopy in the evaluation of hair and scalp disorders. *J Am Acad Dermatol.* 2006;55:799-806.
22. Mane M, Nath AK, Thappa DM. Utility of dermoscopy in alopecia areata. *Indian J Dermatol.* 2011;56:407-11.
23. Widaty S, Pusponegoro EH, Rahmayunita G, Astriningrum R, Adinda MA, Oktarina C, et al. Applicability of trichoscopy in scalp seborrheic dermatitis. *Int J Trichol.* 2019;11:43-8.
24. Estrada DB, Tamler C, Sodre CT, Barcaui CB, Pereira FB. Dermoscopy patterns of cicatricial alopecia resulting from discoid lupus erythematosus and lichen planopilaris. *A Bras Dermatol.* 2010;85:179-83.

Cite this article as: Varma K, Singh U, Kataria M. Trichoscopy in common scalp alopecia: an observational study. *Int J Res Dermatol* 2020;6:361-6.