

## Original Research Article

# Effect of intralesional measles mumps rubella immunotherapy in cutaneous viral warts

Rahul N. Jaiswal, Anil P. Gosavi\*, Ravindranath B. Chavan, Darshana R. Kundale

Department of Dermatology, BJ Govt Medical College, Pune, Maharashtra, India

**Received:** 25 December 2019

**Revised:** 08 March 2020

**Accepted:** 09 March 2020

**\*Correspondence:**

Dr. Anil P. Gosavi,

E-mail: [dranilgosavi@gmail.com](mailto:dranilgosavi@gmail.com)

**Copyright:** © the author(s), publisher and licensee Medip Academy. This is an open-access article distributed under the terms of the Creative Commons Attribution Non-Commercial License, which permits unrestricted non-commercial use, distribution, and reproduction in any medium, provided the original work is properly cited.

### ABSTRACT

**Background:** Viral warts are benign proliferation of the skin and mucosa caused by various strains of double stranded DNA human papilloma virus (HPV). MMR immunotherapy of warts is a novel, simple, cost-effective procedure which treats wart by stimulation of non-specific cell mediated immune response to clear HPV virus from the skin. A study to evaluate the role of intralesional measles mumps rubella (MMR) immunotherapy in cutaneous viral warts.

**Methods:** Total 22 patients of both sexes were included in the study. Intralesional MMR 1 unit (0.1 ml) was injected into the largest wart at 2 weeks interval for a maximum of six treatments. Maximum dose of immunotherapy was 0.5 ml for one session and follow up was kept for 3 months duration.

**Results:** Out of 22, 20 patients completed the treatment, 12 patients (60%) shows complete response, 5 patients (25%) shows partial response and 3 patients (15%) shows no response.

**Conclusions:** Intralesional measles mumps rubella (MMR) immunotherapy is an easy, simple, minimally invasive and relatively painless technique, which helps in induction of an adequate immune response leading to resolution of warts.

**Keywords:** Measles mumps rubella, Human papilloma virus, Immunotherapy, Verruca vulgaris

### INTRODUCTION

Viral warts are commonly encountered benign proliferation of skin, mucous membrane and other epithelial tissues caused by the various strains of human papilloma virus (HPV). HPV clinically manifest as common warts (verruca vulgaris), filiform warts (digitate wart), flat warts (verruca plana), plantar warts, genital warts (condyloma accuminata), oral and laryngeal papillomas and epidermodysplasia verruciformis.<sup>1</sup> Viral warts are benign growth as papillomas that can grow anywhere on the body, commonly on the extremities, hands and feet that are difficult to treat and requires either medical or surgical treatment. Sometimes management is quite difficult, primarily due to recalcitrance to standard

modalities of treatment and high rates of recurrence. It has potential for spread to contiguous sites and to contacts leading to disfigurement and psychosocial effects resulting in considerable morbidity and so there is a constant demand for its cure. Multiple available treatment options including cryosurgery, chemical cautery, electrocautery, radiocautery, curettage and CO<sub>2</sub> lasers are generally painful and limited by rate of recurrences.<sup>2</sup> Multiple immunotherapy trials are being tried for the recurrent and recalcitrant viral warts such as intralesional vitamin D, PPD (purified protein derivative), candida antigen, tuberculin injection, BCG (Bacillus Calmette Guerin) vaccine and bleomycin injection with limited success.<sup>3</sup> The ideal aim of the treatment of warts is to remove the wart without recurrence by assisting the

immune system more effectively inducing life-long immunity to human papilloma viruses.<sup>4</sup> Intralesional measles mumps rubella (MMR) is a novel, simple, minimally invasive and relatively painless procedure which reduces wart by means of stimulation of cell mediated immune response to clear HPV virus.<sup>5</sup> This procedure does not result in scar formation, as in case of other treatment options. In multiple viral warts forming large plaque, especially of palms and soles, other destructive procedures are inappropriate and impractical.<sup>6</sup>

The objective of this study is to evaluate the role of intralesional MMR immunotherapy in multiple difficult to treat viral warts. Usually, as the cell mediated immunity starts progressing, the viral growth regresses in period of 4 to 12 weeks duration.<sup>8</sup>

## METHODS

After obtaining approval of institutional ethical committee of BJ Government Medical College, Pune, a total 22 cases of both sexes (14 males and 8 females) were included in the study. The study design is prospective follow up study completed between February 2019 to August 2019. A detailed history regarding duration and symptoms of the wart lesions was taken in each patient. The patients were examined for various clinical lesions and other systemic illness with complete blood count, liver function tests, renal function test, electrocardiography, and chest X-ray. The final diagnosis of viral warts was clinical only.

### Selection of cases

Inclusion criteria were patients of both sex and age >12 years having cutaneous viral warts with more than or equal to 5 lesions giving their consent for inclusion in the study. Exclusion criteria were patients not willing to give written informed consent, less than 12 years of age, pregnant and lactating women, individual with immune-compromised state or any active infection and patients with muco-cutaneous or ano-genital warts.

The detailed procedure was explained to the patient and the written informed consent was taken. Taking all the aseptic precaution, intralesional MMR 1 unit (0.1 ml) was injected into the largest wart at 2 weeks interval for a maximum of six treatments. Maximum dose of immunotherapy was 0.5 ml for one session and follow up was kept for 3 months duration. Response was assessed on the basis of clinical photographs noticing reduction in number and size of the lesion. Complete clearance- 100% resolution of lesions. Partial clearance- approximately 50% reduction of lesions. No response- no reduction in number and size of lesions.

Follow-up will be made every 4 weeks for 3 months to detect response using clinical photos and medical records. Counselling regarding further follow up of the patient and

outcome of the procedure was done to the patient. The data was analyzed using appropriate statistics. Mean values with standard deviations (SD) were calculated for quantitative data, and nominal data were presented as percentages. A statistically significant inverse correlation was found between the duration of warts and the degree of response using Pearson inverse correlation test.

## RESULTS

Out of total 22 patients, 20 patients with multiple cutaneous viral warts who completed follow up were included in this study and results are obtained using appropriate statistics. Amongst them 12 are males (60%) and 8 are females (40%) with male: female ratio of 1.5:1. The mean duration of the disease was  $6.3 \pm 1.2$  (range: 1-12) months. This study shows in general males are more affected than females with mean age was  $25.9 \pm 7.4$  years and the mean (SD) time to complete clearance was 6.7 (2.6%) weeks.

The most common site of wart presentation was the palmoplantar surface in 12 patients, followed by the hands/upper extremities in 8 patients and periungual in 2 patients. Immunotherapy observation after 3 months follow up shows complete response in 12, partial response in 5 and no response in 3 patients. Figure 1 shows pre immunotherapy and post immunotherapy results of complete resolution of warts over the dorsal aspect of viral warts in 3 weeks duration. Image no 2 showing recurrent and recalcitrant to treat difficult sites with complete resolution in 3 months with 6 sessions of immunotherapy. Image no 3 and 4 shows pre and post immunotherapy pictures of complete resolution of plantar warts in 2 months duration. Maximum response was seen in palmar warts followed by plantar warts. An important observation in this work was the better cure rate in patients with shorter disease duration. The fastest resolution of palmar warts was seen at 3 weeks duration with no recurrence. Most of the warts responded within 4-8 weeks of follow up period.

A statistically significant inverse correlation was found between the duration of warts and the degree of response ( $r=-0.2$ ,  $p=0.008$ , Pearson correlation test), indicating that patients with shorter disease duration responded better. MMR vaccine injection for resistant and recalcitrant periungual warts shows good response, moreover periungual warts did not adversely affect nail growth or caused onycholysis or nail dystrophy with no recurrence. We acknowledge the limitations of our study; it was an open-labelled study without randomization or controls.

The adverse effects noted in patients were pain at injection site in 10 (50%) patients, post procedure erythema in 4 patients (20%) and post inflammatory hyperpigmentation in 3 patients at injection site. The pain noticed during the procedure was quite tolerable which was treated with symptomatic drugs. These were very

few as compared to previous studies in literature. The final results of this MMR immunotherapy study show out of total 20 patients, there was complete response in 12 (60%) patients, partial response in 5 (25%) patients and no response in 3 (15%) patients.

Immunotherapy may work by activating a delayed hypersensitivity response to the wart tissue antigens, aiding clearance of both local and distant warts. This therapy was shown to be associated with the production of Th1 cytokines. Th1 cytokines TNF- $\alpha$  and IL-1 downregulate the transcription of HPV genes whereas INF- $\gamma$  and IL-2 stimulate cytotoxic T cells and natural killer cells to eradicate HPV-infected cells.<sup>8</sup> Intralesional

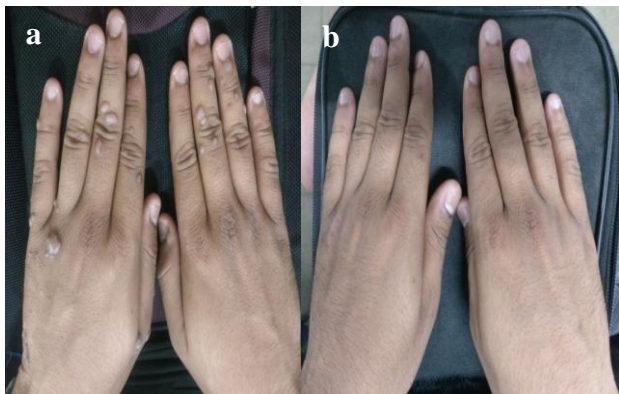immunotherapy has been shown to alter the cytokine profile to a predominant Th1 type, decreasing the Th2 response and inducing strong cell-mediated immunity.

**Table 1: Immunotherapy observation after follow up in all the cases.**

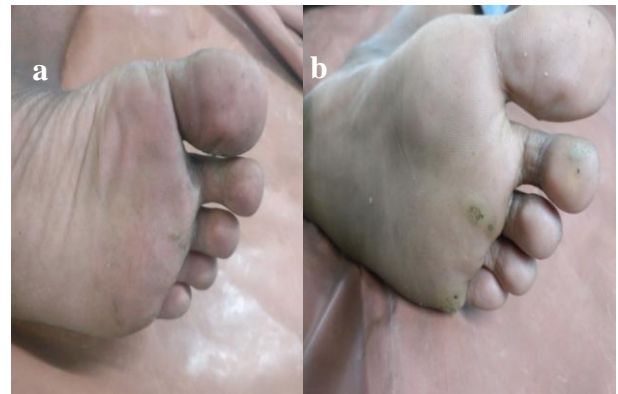MMR immunotherapy	Cases N (%)
Complete response	12 (60)
Partial response	5 (25)
No response	3 (15)
Lost to follow up	2 (10)
<b>Total</b>	<b>22</b>

**Table 2: Site wise response to treatment with MMR immunotherapy.**

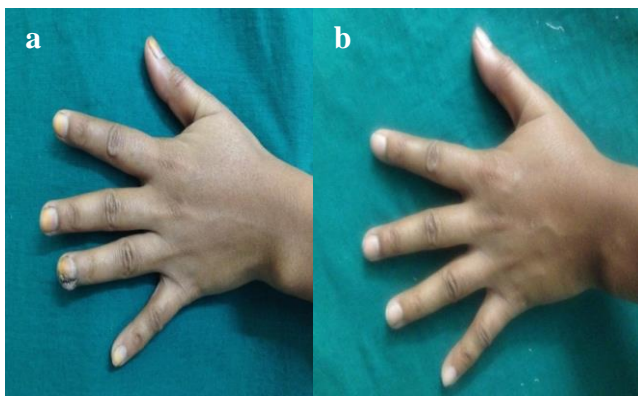
Site wise response	Complete response	Partial response	No response
	N (%)	N (%)	N (%)
Palmar warts	4 (20)	1 (5)	1 (5)
Plantar warts	3 (15)	2 (10)	1 (5)
Warts over dorsum of hand	2 (10)	1 (5)	0
Warts over dorsum of foot	1 (5)	1 (5)	1 (5)
Periungual warts	2 (10)	0	0
<b>Total (n=20)</b>	<b>12 (60)</b>	<b>5 (25)</b>	<b>3 (15)</b>



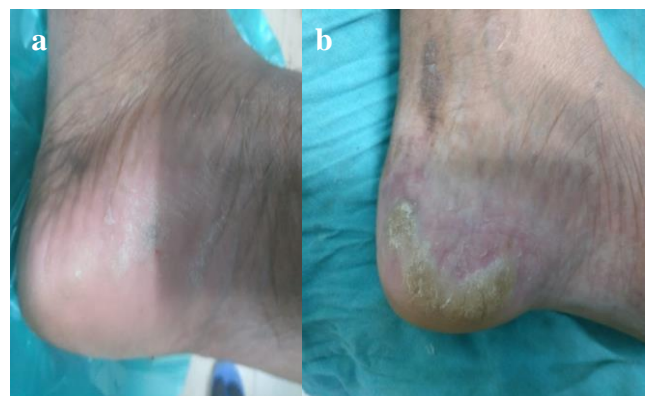
**Figure 1: (a) Before immunotherapy, (b) after immunotherapy (3 weeks).**



**Figure 3: (a) After immunotherapy, (b) before immunotherapy (5 weeks).**



**Figure 2: (a) Before immunotherapy, (b) after immunotherapy (4 weeks).**



**Figure 4: (a) After immunotherapy, (b) before immunotherapy (8 weeks).**

## DISCUSSION

The clearance of untreated distant warts strongly indicates the development of a widespread HPV-targeted immunity as a response of antigen injection and represents a major advantage of the intralesional immunotherapy. In study by Nofal et al study included 135 patients with single or multiple recalcitrant or non-recalcitrant common warts received intralesional MMR vaccine.<sup>7</sup> The results revealed complete response in 57 patients (81.4%), partial response in seven patients (10%), and no response in six patients (8.6%) of the MMR group. Complications reported during this study were keloid formation at injection sites and flu like illness in few patients which were not present in our study.

An important observation in this work was the better cure rate in patients with shorter disease duration. The fastest resolution of palmar warts was seen at 3 weeks duration with no recurrence. Most of the warts responded within 4-8 weeks of follow up. It is quite known that warts typically continue to increase in size and distribution and may become more resistant to treatment over time. So early treatment of warts is mandatory and waiting for spontaneous resolution might sometimes make the condition difficult to treat. Regarding the number of warts, we found a significant better response in multiple lesions than in single ones.

In study by, Zamanian et al carried out study to assess the efficacy of intralesional injection of mumps-measles-rubella vaccine in patients with wart which showed mean age was 18.9±12 years in the MMR group and 20.1±10 years in the normal saline group.<sup>10</sup> In our study we didn't use control group for comparison purpose and mean age group was 28.9±9.4 years and we did follow up for 3 months unlike this study where only 3 sessions of MMR was given over 15 days interval followed by a follow up of 45 days.

In a study by Meena et al using MWV for the treatment of multiple warts, a sensitization dose of 0.1 ml was given in each deltoid region at the baseline.<sup>11</sup> After 2 weeks, subsequent injections were given at an interval of 1 week intra-lesionally into three to five lesions at a time. Complete clearance of warts at the site of injection was seen in 33 (83%) patients with 23 (70%) of the 33 patients showing resolution of the distant untreated warts. While in our study complete resolution was seen in 60% and partial resolution in 25% patients with 15 of 17 patients shows resolution of distant warts. In a study by Mohamad et al, MMR vaccine was given in the treatment of plantar warts in 100 patients.<sup>12</sup> This study showed a significantly higher rate of complete clearance compared with the control group (82% vs. 0%, respectively). The rate of partial response was 6% versus 30%, and the rate of no response was 12% versus 70%, respectively. While in our study complete resolution was seen in 10 of 12

plantar warts and partial resolution in 3 plantar warts patients.

In a study by Nimbalkar et al each patient of viral wart was injected with 10 TU of tuberculin purified protein derivative (PPD) (0.1 ml) intra-lesionally in the largest wart at 2 weekly intervals.<sup>13</sup> Clinical assessment was done 3 weeks after the completion of treatment. The study showed that out of 45 patients, 62.2% showed complete clearance, eight patients 17.8% showed partial clearance, and 20 % patients showed no improvement. As compared to PPD, MMR injections were found to be more effective as our study showed 60% complete resolution, 25% partial resolution and only 15% no resolution of lesions. In another study by Gupta et al, in which killed MWV was used for the treatment of anogenital warts, a sensitization dose of 0.1 ml was given in each deltoid, and intralesional injections were given in ≤3 warts at a time, which were repeated at weekly intervals.<sup>6</sup> There was complete clearance of warts in eight out of the nine patients (88.9%) who were treated. All the patients included in the study were mucocutaneous warts including busche lowenstein tumor over genital sites. Our study was mainly done over cutaneous warts only.

Our results with MMR-treated group showed complete response in 60% patients, a closely similar response rate to those previously reported by Nofal (his study on the effect of MMR vaccine in the treatment of common warts with complete clearance in 65% of cases and no recurrence was observed during the follow up period) and Gamil et al (their study on MMR vaccine in treatment of plantar warts with slightly higher 87% complete clearance in injected warts).<sup>14,15</sup> Another study done by Brunk (using candida antigen with 85% clearance) and Gupta et al (using killed *Mycobacterium W* vaccine for the treatment of ano-genital warts with 88.9 % clearance) which is slightly higher than those reported by Phillips et al (using candida antigen injection with 72% clearance).<sup>16-18</sup>

Immunotherapy may work by activating a delayed hypersensitivity response to the wart tissue antigens, aiding clearance of both local and distant warts. This therapy was shown to be associated with the production of Th1 cytokines. Th1 cytokines TNF-α and IL-1 downregulate the transcription of HPV genes whereas INF-γ and IL-2 stimulate cytotoxic T cells and natural killer cells to eradicate HPV-infected cells. Intralesional immunotherapy has been shown to alter the cytokine profile to a predominant Th1 type, decreasing the Th2 response and inducing strong cell-mediated immunity.<sup>7</sup> We acknowledge the limitations of this study; it was an open-labelled study without randomization or controls with smaller sample size and shorter follow up duration.

## CONCLUSION

MMR Immunotherapy is simple, relatively painless, cost effective and efficacious modality of treatment for

multiple and recurrent cutaneous viral warts. It is effective equally at injected and distant site along with difficult to treat sites like periungual warts and prevent reoccurrence of wart with complete clearance. The side effects involved in the procedure is quite less and infrequent as compared to other modalities of treatment.

*Funding: No funding sources*

*Conflict of interest: None declared*

*Ethical approval: The study was approved by the institutional ethics committee, BJ GMC, Pune*

## REFERENCES

1. Bologna JL, Jorizzo JL, Julie V, Schaffer MD. Textbook of Dermatology: 3rd Edition, 2008 Mosby-elsevier publication, section 12, C78, 2008.
2. Pancos N, Velarde HH, Seinwill MR. Surgical autoimmunization against verruca plantaris via autogenic graft of papilloma in situ. Current Podiatry. 1980;23:23.
3. Shivakumar V, Okade R, Rajkumar V. Autoimplantation therapy for multiple warts. Indian J Dermatol Venereol Leprol. 2009;75(6):593-5.
4. Roden RB, Lowy DR, Schiller JT. Papillomavirus is resistant to desiccation. J Infect Dis. 1997;176:1076-9.
5. Srivastava PK, Bajaj AK. Autowart injection therapy for recalcitrant warts. Indian J Dermatology. 2010;55(4):367-9.
6. Gupta S, Malhotra AK, Verma KK, Sharma VK. Intralesional immunotherapy with killed Mycobacterium w vaccine for the treatment of anogenital warts: An open label pilot study. J Eur Acad Dermatol Venereol. 2008;22:1089-93.
7. Nofal A, Nofal E. Intralesional immunotherapy of common warts: Successful treatment with mumps, measles and rubella vaccine. J Eur Acad Dermatol Venereol. 2010;24:1166-70.
8. Griffiths C, Barker J, Bleiker T, Chalmers R, Creamer D. Textbook of Rooks of Dermatology: 9th edition. Wiley-Blackwell publication. 2010: 33.37-33.55.
9. Dhope A, Madke B, Singh AL. Effect of measles mumps rubella vaccine in treatment of common warts. Indian J Drugs Dermatol (serial online). 2017;3:14-9.
10. Zamanian A, Mobasher P, Jazi GA. Efficacy of intralesional injection of mumps-measles-rubella vaccine in patients with wart. Adv Biomed Res. 2014;3:107.
11. Meena JK, Malhotra AK, Mathur DK, Mathur DC. Intralesional immunotherapy with Mycobacterium w vaccine in patients with multiple cutaneous warts: Uncontrolled open study. JAMA Dermatol. 2013;149:237-9.
12. Mohamad NS, Badran F, Yakout E. Evaluation of the efficacy of a combination: Measles, mumps and rubella vaccine in the treatment of plantar warts. Our Dermatol Online. 2013;4:463-7.
13. Nimbalkar A, Pande S, Sharma R, Borkar M. Tuberculin purified protein derivative immunotherapy in the treatment of viral warts. Indian J Drugs Dermatol. 2016;2:19-23.
14. Nofal A, Nofal E. Intralesional immunotherapy of common warts: successful treatment with mumps, measles and rubella vaccine. J Eur Acad Dermatol Venereol. 2010;24:1166-70.
15. Gamil H, Elgharib I, Nofal A, Elaziz AT. Intralesional immunotherapy of plantar warts: report of a new antigen combination. J Am Acad Dermatol. 2010;63:40-3.
16. Brunk D. Injection of Candida antigen works on warts. Skin Allergy News. 1999;30:5.
17. Gupta S, Malhotra AK, Sharma VK. Intralesional immunotherapy with killed Mycobacterium W vaccine for the treatment of ano-genital warts: an open label pilot study. J Eur Acad Dermatol Venereol. 2008;22:1089-93.
18. Johnson SM, Roberson PK, Horn TD. Intralesional injection of mumps or candida skin test antigens: A novel immunotherapy for warts. Arch Dermatol. 2001;137:451-5.

**Cite this article as:** Jaiswal RN, Gosavi AP, Chavan RB, Kundale DR. Effect of intralesional measles mumps rubella immunotherapy in cutaneous viral warts. Int J Res Dermatol 2020;6:347-51.