

Original Research Article

A comparative study of fractional carbon dioxide laser, narrowband ultraviolet B and topical tacrolimus 0.1% ointment versus narrowband ultraviolet B, topical tacrolimus 0.1% ointment in stable vitiligo

Anusha Putta^{1*}, Mohammed Waseem Javed²

¹Department of DVL, M. R. Medical College, Kalaburagi, Karnataka, India

²Department of DVL, KBNIMS, Kalaburagi, Karnataka, India

Received: 09 November 2019

Revised: 06 January 2020

Accepted: 07 January 2020

***Correspondence:**

Dr. Anusha Putta,

E-mail: anushachowdary1993@gmail.com

Copyright: © the author(s), publisher and licensee Medip Academy. This is an open-access article distributed under the terms of the Creative Commons Attribution Non-Commercial License, which permits unrestricted non-commercial use, distribution, and reproduction in any medium, provided the original work is properly cited.

ABSTRACT

Background: Vitiligo, an acquired pigmentary disorder of skin and mucous membrane characterized by well circumscribed depigmented macules that occur secondary to selective destruction of melanocytes. Fractional CO₂ laser system is a recent advancement in the treatment of vitiligo which works on the concept of fractional photothermolysis, in which microscopic treatment zones are created which help in increasing the penetration of topically applied agent which indirectly improves drug efficacy.

Methods: A comparative study was conducted on 40 patients of stable vitiligo attending OPD, Dept of DVL with fractional CO₂ laser, narrowband ultraviolet B (NBUVB) and topical tacrolimus 0.1% vs NBUVB, topical tacrolimus 0.1% for a duration of 4 months and patients were followed up for 12 weeks post treatment.

Results: Patients on Fractional CO₂ laser in combination with NBUVB and topical tacrolimus 0.1% ointment showed >50% improvement compared with other group, with duration for initiation of pigmentation being comparatively less.

Conclusions: The treatment protocol with CO₂ laser in combination with topical tacrolimus 0.1% cream and NBUVB for stable vitiligo was more effective than NBUVB and topical tacrolimus 0.1% alone and this study demonstrates that adding fractional CO₂ laser improves repigmentation rate of vitiliginous lesions.

Keywords: Fractional CO₂ laser, NBUVB, Tacrolimus, Vitiligo

INTRODUCTION

Vitiligo is an acquired, idiopathic disorder characterized by circumscribed depigmented macules and patches with or without leukotrichia. Its characterized by loss of functional melanocytes and melanin in epidermis.¹ The disease has an incidence of 0.5%-2% with no ethnic or sex predilection. Vitiligo has polygenic or autosomal dominant inheritance pattern with incomplete penetrance and variable expression.²⁻⁴ Based on clinical association of vitiligo with number of disorders, its considered to be

autoimmune or autoinflammatory.⁵ People affected by vitiligo have a vast reduction of quality of life caused by color contrast between healthy pigmented skin and depigmented vitiliginous patches that give patients psychological problems.^{6,7} Medical treatment is the primary mode of therapy. Treatment can be broadly classified as medical, physical and surgical therapies and choice of treatment depends on extent, activity and refractoriness of disease. Combination of different modalities can be used to generate better outcomes compared to monotherapy.

Fractional CO₂ laser system is a recent advancement in the treatment of Vitiligo which works on the concept of Fractional photo thermolysis theory of laser skin resurfacing, in which microscopic treatment zones are created which help in increasing the penetration of topically applied agent which indirectly improves drug efficacy. The study was conducted to compare efficacy of fractional CO₂ laser, narrowband ultraviolet B (NBUVB), topical 0.1% tacrolimus ointment versus NBUVB and topical 0.1% tacrolimus ointment in patients with stable vitiligo.

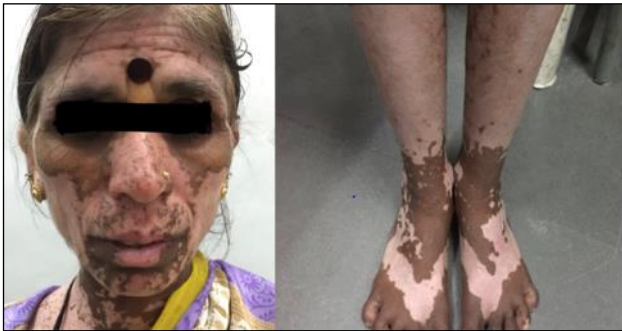

Figure 1: Generalised vitiligo.

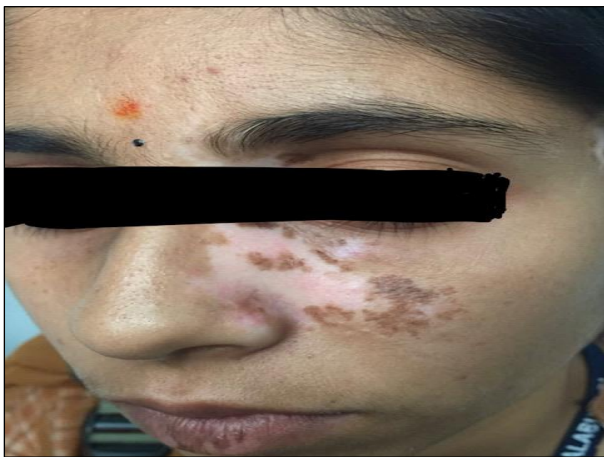

Figure 2: Segmental vitiligo.

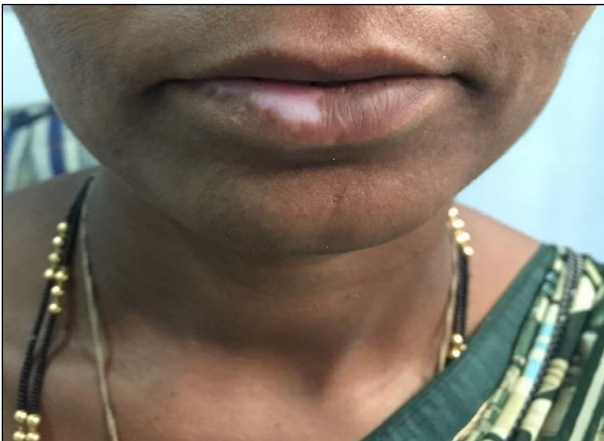

Figure 3: Mucosal vitiligo.



Figure 4: Acral vitiligo.

METHODS

A comparative study was conducted on 40 patients of stable vitiligo attending OPD, department of Dermatology, Basaveshwara Teaching and General Hospital, Kalaburagi from March 2018 to September 2018. Study subjects were selected based on inclusion - exclusion criteria. Information was collected through proforma from each patient. Ethical clearance was taken for the study from ethical committee. Stable vitiligo. Patients with age >14 yrs and those with stable vitiligo were included and those with active skin infections, pregnant and nursing patients, patients currently on isotretinoin or have taken isotretinoin within the previous 12 months, active vitiligo patients with new, spreading lesions and positive koebner's phenomenon were excluded. Statistical analysis was done by Chi square test using SPSS version 20.0 and p value <0.05 was taken as significant.

Initial clinical examination of the patient was done to determine the characteristics of vitiligo, including clinical type, number, size, and distribution. Patients were divided into 2 groups.

Group A patients were treated with CO₂ laser followed by NBUVB 0.5 J/cm² and tacrolimus ointment 0.1%. Group B patients were treated with NBUVB 0.5 J/cm² and tacrolimus ointment 0.1%.

Preparation prior to procedure

After obtaining written and informed consent, the skin was cleansed using mild cleanser. Local anesthetic cream was applied under occlusion for 1 hour to the entire area to be treated with laser. Eyes were covered with eye shields. Two passes of FCO₂ was used. Standard digital photographs will be taken at baseline, before each treatment session, and 16 weeks after the final treatment.

Lutronic fractional CO₂ was used with beam size 300 μ, peak power 30 W, beam mode static, pulse energy 100, density 150 spots per cm², total density 150 spots per cm².

Procedure in group A

FCO₂ laser was delivered in above specifications, followed by NB-UVB 0.5 J/cm² and topical tacrolimus 0.1% ointment on same day of procedure and continued twice daily throughout the study period. CO₂ laser was repeated every 15 days and the phototherapy sessions were given twice weekly for a period of 4 months.

Procedure in group B

NB-UVB phototherapy twice weekly and tacrolimus 0.1% ointment twice a day for 4 months.

Evaluation of patient was scored using a quartile grading scale.

Table 1: Quartile grading scale.

Grade	Percentage of Re pigmentation	Response
0	0	Nil
1	1-25%	Minimal
2	26-50%	Moderate
3	51-75%	Good
4	>75%	Excellent

RESULTS

Out of 40 patients of vitiligo, 26 were females and 14 were males. The commonest age group seen was 20-30 years. Age of onset of vitiligo in this study ranged from 20-30 years. The commonest site of lesion was over lower limbs. Family history was seen in 4 patients. In this study vitiligo was seen in association with hypothyroidism in 2 patients. Previous treatment history was seen in 31 patients.

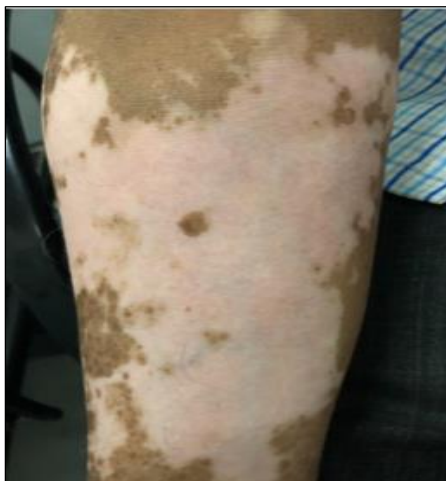

Figure 5: Group A patient - before treatment.

Among 40 patients Grade 3 repigmentation was seen 48% in Group A and 23% in Group B. Time taken for initiation of repigmentation was <6 weeks in Group A in

38% and 10% in group B. Marginal type of repigmentation was the commonest type in Group A and perifollicular in Group B. Erythema and was common side effect in Group A and pruritis in Group B.

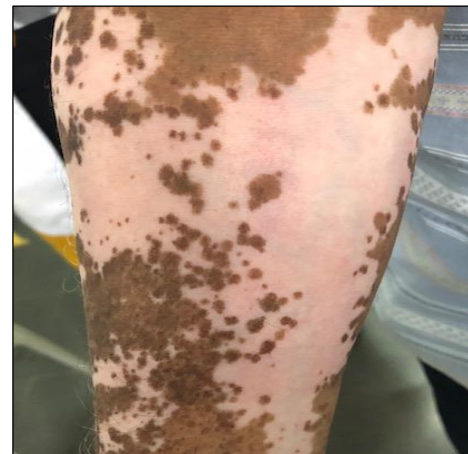

Figure 6: Group A patient - 12 weeks of treatment.

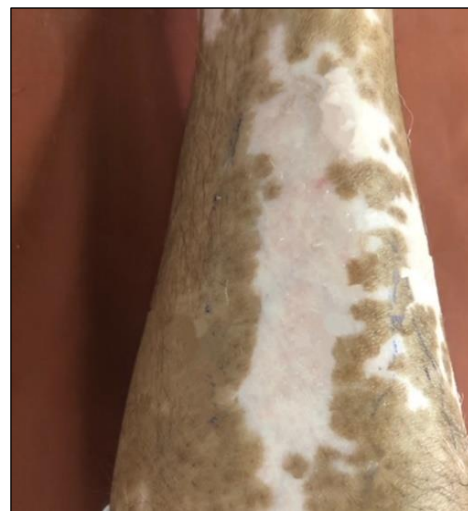

Figure 7: Group B - before treatment.

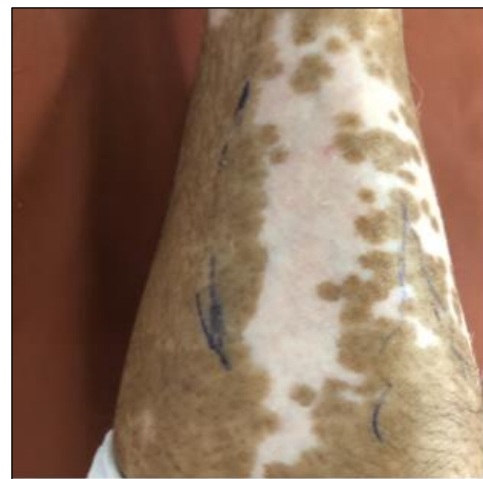


Figure 8: Group B - 12 weeks of treatment.



Figure 9: Fractional CO₂ laser.

DISCUSSION

Vitiligo is a common pigmentary disorder of the skin. Widespread prejudices, ignorance, taboos, lack of scientific appraisal, and confusion of vitiligo with leprosy - all make it a social embarrassment for the patient, although the patient's life expectancy remains unaffected.⁸⁻⁹

Out of 40 patients, majority were females which is different from that reported by Handa and Kaur, Koranne et al.^{10,11}

Age of onset of vitiligo in this study ranged from 20-30 yrs, while Howtiz et al, showed the age of onset to be between 40 and 60 years.¹² Positive family history which is considered to be a poor prognostic factor for vitiligo was seen in 4 patients in this study. Familial occurrence has been reported to be in the range of 6.25% to 30%.¹³ The association of vitiligo with thyroid disease was seen in 2 patients in this study but was reported to be 12% by Gopal et al.¹⁴

Many mechanisms may contribute to improvement of vitiligo with CO₂ laser. It produces immediate tissue retraction due to denaturation of collagen bundles, and this shrinkage over treated skin surface may contribute to narrowing of vitiliginous lesions.¹⁵ Yuan et al, found that ablative Fr: CO₂ laser is more effective than no ablative fractional laser in treatment of NSV.¹⁶

Tacrolimus induces pigmentation by modulating immune response as well as by inducing melanocyte proliferation and migration. It suppresses the levels of a pro inflammatory cytokine, like TNF alpha which also suppresses the melanin production.¹⁷⁻²⁰

Nordal et al, treated half side of patients with tacrolimus ointment 0.1% once daily and half side with placebo

ointment and gave whole body NBUVB twice or thrice weekly for at least 2 months. The mean repigmentation was greater with tacrolimus.²¹ Wu et al, demonstrated that NBUVB irradiation stimulates the release of basic fibroblast growth factor and endothelin-1 from keratinocytes, which induces melanocyte proliferation.^{22,23}

In this study Grade 3 repigmentation was more in group A, 8 patients which was seen only in 2 patients of group B. Grade 1 repigmentation was more in group A, 7 patients compared to group B, 3 patients and no repigmentation was seen in 7 patients of group B, and in 2 patients of Group A. Duration of onset of repigmentation was <6 weeks in 8 patients of group A and 2 patients of group B, >6 weeks in 10 patients of group A and 11 patients of group B.

Njoo et al, in a study of 51 children with vitiligo reported more than 75% overall repigmentation in 27 patients (53%) after 1-year of treatment with NBUVB.²⁴

Marginal and diffuse type of repigmentation was common in group A and perifollicular in Group B. This was similar to the perifollicular pattern has been shown to be the most common pattern of repigmentation associated with NBUVB as is also seen with other UV based therapies like PUVA therapy and excimer laser.²⁵ A study by Bhatnagar et al, compared the mean repigmentation for therapy resistant sites in patients exposed to NBUVB versus PUVA; it showed that after approximately 6 months of treatment (thrice weekly), 68% of repigmentation was possible using NBUVB versus 54% using PUVA.²⁶

CONCLUSION

Combining FCO₂ laser, NBUVB and 0.1% tacrolimus ointment produces a significant improvement in stable vitiligo compared to NBUVB and 0.1% tacrolimus ointment.

Funding: No funding sources

Conflict of interest: None declared

Ethical approval: The study was approved by the institutional ethics committee

REFERENCES

- Ortonne JP. Vitiligo and other Disorders of Hypopigmentation. In: Bologna JL, Jorizzo JL, Rapini RP (eds). *Dermatology*. Spain: Elsevier; 2008: 913-914.
- Bleehen SS, Ebling FJ, Champion RH. Disorders of skin color. In: Champion RH, Burton JL, Ebling FJ (eds). *Textbook of Dermatology*. London: Blackwell Scientific Publications; 1992:1561-1622.
- Moscher DB, Fitzpatrick TB, Hori Y, Ortonne JP. Disorders of pigmentation. In: Fitzpatrick TB, Isen AZ, Wolff K, Freedberg IM, Austen KF (eds).

- Dermatology in general medicine. New York: McGraw Hill; 1993:903.
- Bolognia JL, Pawelek JM. Biology of hypopigmentation. *J Am Acad Dermatol.* 1988;19:217-55.
 - Griffiths C, Barker J, Bleiker T, Chalmers R, Creamer D. Acquired pigmentary disorders, acquired hypomelanosis. *Rooks Textbook of Dermatology.* 9th edition. Oxford: Wiley; 2016: 88.
 - Kent GA, Abadie M. Psychological effects of vitiligo: a critical incident analysis. *J Am Acad Dermatol.* 1996;3:895-8.
 - Prasad D, Pandhi R, Dogra SKanwar AJKumar B. Dermatology Life Quality Index Score in vitiligo and its impact on treatment outcome. *Br J Dermatol.* 2003;148:373-4.
 - Koranne RV, Sachdeva KG. Vitiligo. *Int J Dermatol.* 1998;27:676-81.
 - Nair BKH. Vitiligo: A retrospect. *Int J Dermatol.* 1978;17:55-7.
 - Handa S, Kaur I. Vitiligo: Clinical findings in 1436 patients. *J Dermatol.* 1999;26:653-7.
 - Koranne RV, Sehgal VN, Sachdeva KG. Clinical profile of vitiligo in North India. *Ind J Dermatol Venereol Leprol.* 1986;52:81-2.
 - Howits J, Brodthagen H, Schwarts M, Thomsen K. Prevalence of vitiligo: Epidemiological survey the Isle of Bornholm, Denmark. *Arch Dermatol.* 1977;113:47-52.
 - Shajil EM, Agrawal D, Vagadia K, Marfatia YS, Begum R. Vitiligo: Clinical profiles in Vadodara, Gujarat. *Indian J Dermatol.* 2006;51:100-4.
 - Gopal K, Rama Rao GR, Kumar YH, Appa Rao MV, Vasudev PS. Vitiligo: A part of a systemic autoimmune process. *Indian J Dermatol Venereol Leprol.* 2007;73:162-5.
 - Ross EV, Yashar SS, Naseef GS, Barnette DJ, Skrobal M, Grevelink J, et al. A pilot study of in vivo immediate tissue contraction with CO₂ skin laser resurfacing in a live farm pig. *Dermatol Surg.* 1999;25(11):851-6.
 - Yuan J, Chen H, Yan R, Cui S, Li YH, Wu Y, et al. Fractional CO₂ lasers contribute to the treatment of stable non-segmental vitiligo. *Eur J Dermatol.* 2016;26(6):592-8.
 - Grimes PE, Morris R, Avannis-Aghajani E, Soriano T, Meraz M, Metzger A. Topical tacrolimus therapy for vitiligo: Therapeutic responses and skin messenger RNA expression of proinflammatory cytokines. *J Am Acad Dermatol.* 2004;51:52-61.
 - Lan CC, Yu HS, Wu CS, Kuo HY, Chai CY, Chen GS. FK506 inhibits tumour necrosis factor-alpha secretion in human keratinocytes via regulation of nuclear factor-kappaB. *Br J Dermatol.* 2005;153:725-32.
 - Moretti S, Spallanzani A, Amato L, Hautmann G, Gallerani I, Fabiani M, et al. New insights into pathogenesis of vitiligo: Imbalance of epidermal cytokines at sites of lesions. *Pigment Cell Res.* 2002;15:87-92.
 - Lee KY, Jeon SY, Hong JW, Choi KW, Lee CY, Choi SJ, et al. Endothelin-1 enhances the proliferation of normal human melanocytes in a paradoxical manner from the TNF- α -inhibited condition, but tacrolimus promotes exclusively the cellular migration without proliferation: A proposed action mechanism for combination therapy of phototherapy and topical tacrolimus in vitiligo treatment. *J Eur Acad Dermatol Venereol.* 2013;27:609-1.
 - Nordal EJ, Guleng GE, Rønnevig JR. Treatment of vitiligo with narrowband-UVB (TL01) combined with tacrolimus ointment (0.1%) vs. placebo ointment, a randomized right/left double-blind comparative study. *J Eur Acad Dermatol Venereol.* 2011;25:1440.
 - Wu CS, Yu CL, Wu CS, Lan CC, Yu HS. Narrow-band ultraviolet-B stimulates proliferation and migration of cultured melanocytes. *Exp Dermatol.* 2004;13:755-63.
 - Wu CS, Lan CC, Yu HS. Narrow-band UVB irradiation stimulates the migration and functional development of vitiligo-IgG antibodies-treated pigment cells. *J Eur Acad Dermatol Venereol.* 2012;26:456-64.
 - Njoo MD, Bos JD, Westerhof W. Treatment of generalized vitiligo in children with narrow-band (TL-01) UVB radiation therapy. *J Am Acad Dermatol.* 2000;42:245-53.
 - Parsad D, Pandhi R, Dogra S, Kumar B. Clinical study of repigmentation patterns with different treatment modalities and their correlation with speed and stability of repigmentation in 352 vitiliginous patches. *J Am Acad Dermatol.* 2004;50:63-7.
 - Bhatnagar A, Kanwar AJ, Prasad D, De D. Comparison of systemic PUVA and NB-UVB in treatment of vitiligo: An open prospective study. *J Eur Acad Dermatol Venereol.* 2007;21:638-42.

Cite this article as: Putta A, Javed MW. A comparative study of fractional carbon dioxide laser, narrowband ultraviolet B and topical tacrolimus 0.1% ointment versus narrowband ultraviolet B, topical tacrolimus 0.1% ointment in stable vitiligo. *Int J Res Dermatol* 2020;6:243-7.