

Case Report

A six-year old girl presenting with alopecia areata incognita: a case report

Ashish Dalal^{1*}, Ajay Kumar², Ritambhara Lohan³, Muskaan Ahlawat⁴

Department of Dermatology, ¹Shaheed Hasan Khan Mewati, GMC, Nalhar, Haryana, India, ²Dr. D.Y. Patil Institute of Medical College, Hospital & Research Centre, Pimpri, Pune - 411018 India

³Department of Pediatrics, W-Pratiksha Hospital, Gurgaon, India

⁴Himalayan Institute of Medical Sciences, Uttarakhand, India

Received: 30 November 2016

Accepted: 23 December 2016

*Correspondence:

Dr. Ashish Dalal,

E-mail: ashishskincare@gmail.com

Copyright: © the author(s), publisher and licensee Medip Academy. This is an open-access article distributed under the terms of the Creative Commons Attribution Non-Commercial License, which permits unrestricted non-commercial use, distribution, and reproduction in any medium, provided the original work is properly cited.

ABSTRACT

A proportion of cases of diffuse hair loss over the scalp mimicking telogen effluvium or androgenetic alopecia are found to have alopecia areata incognita (AAI) on dermoscopic examination and histopathology. AAI has commonly been reported in middle aged women who present with a sudden increase in hair shedding with diffuse alopecia developing after several months. Though the typical glabrous patches of hair loss observed in classical alopecia areata are absent, the abrupt and intense hair loss with a positive hair pull test is suggestive of AAI. There are few reports of AAI occurring in children. We are reporting a case of AAI in a 6-year old child.

Keywords: Alopecia areata incognita, Diffuse hair loss, Telogen hairs

INTRODUCTION

Alopecia areata (AA) is the commonest cause of hair loss in children the other causes being tinea capitis, telogen effluvium and trichotillomania.¹ It is characterized by discrete glabrous patches of alopecia over the scalp or any hair bearing area without clinical signs of inflammation. Alopecia areata incognita (AAI) is a variant of alopecia areata initially described by Rebera that is characterized by an abrupt diffuse shedding of telogen hair over the scalp without any glabrous patches.² AA commonly occurs in young people below the age of forty whereas AAI is more common in older age groups.³ We are reporting AAI in a child with progressive diffuse hair loss over the scalp and localized alopecia over the eyebrows on follow up.

CASE REPORT

A six year old girl presented with diffuse hair loss over the scalp of three months duration. Her mother noticed a significant increase in shedding of hair three months back which had gradually progressed to diffuse baldness over scalp. There was no history of any febrile illness or surgical trauma in the past few months.

Dermatological examination revealed diffuse hair loss over the entire scalp (Figure 1).

The hair pull test and was positive with easy extraction of about 10-14 hairs with each gentle tug showing telogen hair in various stages of maturation. A potassium hydroxide mount of the hair did not reveal any fungal elements. Complete blood counts and thyroid function

tests were normal while antinuclear antibody test was negative; a diagnosis of acute idiopathic telogen effluvium was made.

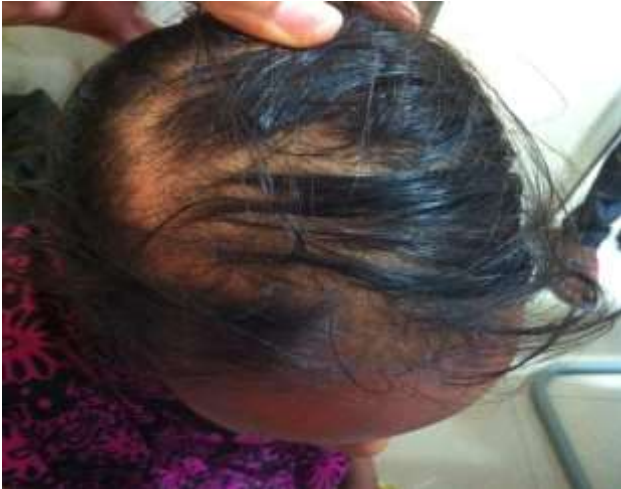

Figure 1: Diffuse hair loss with hair thinning over fronto-parietal area.

On follow up after four weeks the diffuse alopecia over the scalp had progressed further and the patient had developed patchy hair loss over both eyebrows (Figure 2).

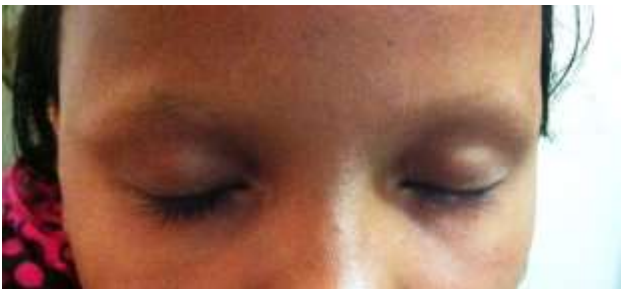

Figure 2: Bilateral loss of eyebrows.

On doing scalp dermoscopy, black dots, broken hairs and short vellus hairs were seen (Figure 3 and 4).

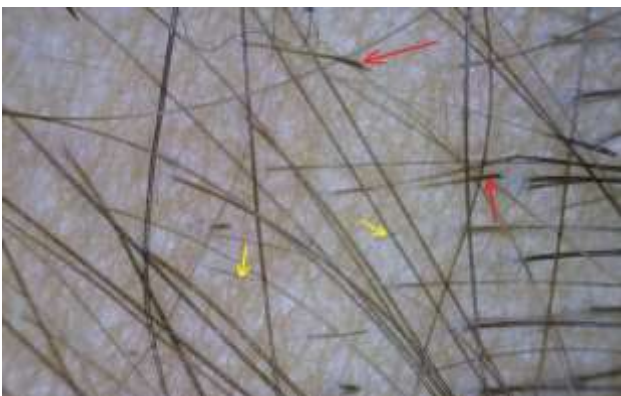


Figure 3: Scalp dermoscopy showing short vellus hairs (yellow arrows) and tapering hairs (red arrows).

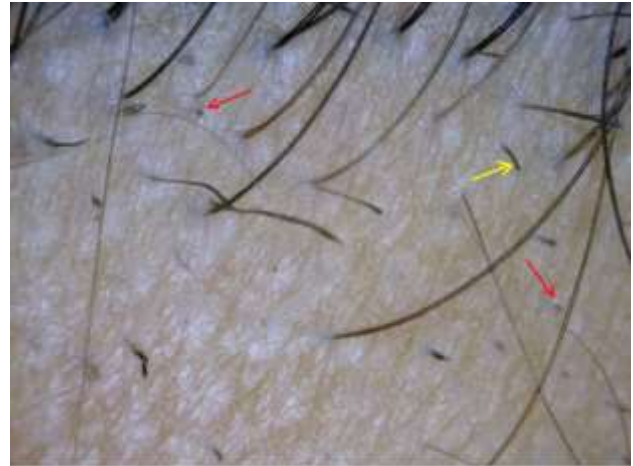

Fig. 4: Scalp dermoscopy showing broken hairs (yellow arrows) and Black dots (red arrows).

Histopathological examination was carried out from the parietal area of scalp which revealed a peribulbar infiltrate around some of the hair follicles. Taking the dermoscopic and histopathological findings into consideration a revised diagnosis of AAI was made.

DISCUSSION

Hair loss in children is an important complaint in dermatology clinics that accounts for 7.5% of pediatric cases. Common causes of hair loss in children include tinea capitis, alopecia areata, telogen effluvium, trichotillomania and traction alopecia whereas uncommon causes are folliculitis decalvans, congenital ichthyosis, nevus sebaceous and Netherton syndrome.⁴

In the year 1987 Rebora had proposed that loss of hair in each circumscribed zone in AA is attributable to the presence of a group hair simultaneously in early anagen VI subphase of the hair cycle as a stochastic event. This group of hair escapes into telogen phase and remain in situ for 100 days before being shed off, resulting in circumscribed hair loss in that zone. He further hypothesized that those with a low percentage of telogen hair exhibit circumscribed zones of hair loss seen in classical AA in which there is damage to groups of hair whereas those with a higher percentage of telogen hair exhibit a diffuse pattern of hair loss called AAI in which isolated hairs scattered all over the scalp are damaged.

Though 'diffuse alopecia areata', 'acute alopecia totalis' and 'acute and diffuse alopecia of the female scalp'⁵ are conditions that have been clubbed with AAI, Rebora has drawn a distinction between diffuse alopecia areata and AAI.³

Moreover half of the cases of AAI on follow up develop patches of AA.³ This is consistent with the progression of diffuse hair loss over the scalp and the development of patchy AA over the eyebrows in our patient on follow up.

The relative absence of yellow dots on dermoscopy in our patient may be attributed to the absence of pheomelanin in hair in individuals of Indian ethnicity.

Funding: No funding sources

Conflict of interest: None declared

Ethical approval: Not required

REFERENCES

1. Cortés GA, Mardones VF, Zemelman DV. Aetiology of childhood alopecia. Rev Chil Pediatr. 2015;86(4):264-9.
2. Rebora A. Alopecia areata incognita: a hypothesis. Dermatologica. 1987;174:214-8.
3. Rebora A. Alopecia areata incognita: a comment. Clinics. 2011;66(8):1481.
4. Al-Refu K. Hair loss in children: common and uncommon causes; clinical and epidemiological study in Jordan. Int J Trichology. 2013;5(4):185-9.
5. Molina L, Donati A, Valente NSY, Romiti R. Alopecia areata incognita. Clinics (Sao Paulo). 2011;66(3):513-5.

Cite this article as: Dalal A, Kumar A, Lohan R, Ahlawat M. A six-year old girl presenting with alopecia areata incognita: a case report. Int J Res Dermatol 2017;3:158-60.