

## Original Research Article

# Clinico-epidemiological study of genodermatoses in pediatric age group

Kalyan Dalave, Mahendra Singh Deora, Sonia Sabhandasani,  
Pallavi Singh\*, Alisha Mittal, Bhavika Shah

Department of Dermatology, Dr. D.Y. Patil Medical College and Hospital (affiliated to Dr. D.Y. Patil Vidyapeeth University), Pune, Maharashtra, India

**Received:** 07 November 2019

**Revised:** 21 November 2019

**Accepted:** 28 November 2019

**\*Correspondence:**

Dr. Pallavi Singh,

E-mail: [drpallavisingh1492@gmail.com](mailto:drpallavisingh1492@gmail.com)

**Copyright:** © the author(s), publisher and licensee Medip Academy. This is an open-access article distributed under the terms of the Creative Commons Attribution Non-Commercial License, which permits unrestricted non-commercial use, distribution, and reproduction in any medium, provided the original work is properly cited.

### ABSTRACT

**Background:** Genetic diseases causing abnormalities in structure and/or function of skin are termed as genodermatoses. As there is paucity of epidemiological data of genodermatoses from our country, this study was conducted to determine the latest clinical and epidemiological trends of pediatric genodermatoses.

**Methods:** A hospital-based observational study consisting of 35 clinically diagnosed pediatric genodermatoses cases, who reported to the Dermatology OPD, Dr. D.Y. Patil Medical College, Pune, was conducted for a period of two years. Socio-demographic and clinical information was collected and clinical examination was performed on all patients to record any cutaneous/extra-cutaneous abnormality. The participants were then subjected to necessary investigations to elucidate the additional disease components. The data was evaluated using appropriate statistical methods.

**Results:** Out of 4032 pediatric patients, 35 were found to have genodermatoses. Majority (57.14%) cases belonged to the first decade of life. There was no sexual predilection (male:female - 0.94:1). The commonest genodermatoses detected were neurofibromatosis and tuberous sclerosis (17.14% each). Most common mode of inheritance seen was autosomal dominant (57.14%). Family history and consanguinity were recorded in 45.71% and 22.86% cases respectively. Café-au-lait macules seen in 22.86% cases and ocular anomalies recorded in 34.38% cases were the commonest cutaneous and extracutaneous manifestations, respectively.

**Conclusions:** Genodermatoses are rare skin disorders with systemic involvement at times, resulting in poorer prognosis. This necessitates more focus on this speciality.

**Keywords:** Genodermatoses, Pediatric, Neurofibromatosis, Tuberous sclerosis

### INTRODUCTION

Genodermatoses are a group of inherited disorders with a conglomeration of cutaneous and systemic signs and symptoms.<sup>1</sup> They do not always manifest at birth, have a variable degree of inheritance and cause considerable morbidity and psychosocial distress due to lack of concrete treatment.<sup>2</sup>

Besides seeking the symptomatic treatment for the disease, the family of the diseased must cope with the risk of disease recurrence in future gestation.<sup>3</sup> Therefore, while evaluating a patient of suspected genodermatoses, a thorough family history often delineates the mode of inheritance which helps predict risk of recurrence.

To get a comprehensive view of a disease, studying its epidemiology and clinical presentation is important. Most

research work associated with genodermatoses is limited to the western population. Very few reports have been published from Indian studies.

So, we conducted this study to characterize pediatric genodermatoses on the basis of their clinical and epidemiological profile. This will set a baseline data for future researchers to make a quick diagnosis of these rare conditions.

**METHODS**

A hospital-based observational study was conducted on the pediatric population, aged 0-18 years, attending the Dermatology OPD of Dr. D.Y. Patil Medical College and Hospital, Pune, over a period of two years from July 2016 to July 2018. Thirty-five cases that were diagnosed to have genodermatoses based on their clinical manifestations, were included in the study. Patients beyond 18 years of age and those unwilling to give consent were excluded.

After taking an informed consent/assent from all the participants and recording their socio-demographic information, a detailed history pertaining to skin complaints, their onset, progression, family history, exacerbating and relieving factors and associated medical

disorders was recorded. Based on the history, pedigree analysis was done for all patients.

A thorough clinical examination was performed to record any cutaneous or extracutaneous abnormality. The morphology, configuration and distribution of lesions were recorded.

Routine blood examination including complete blood count (CBC), total leukocyte count (TLC), differential leukocyte count (DLC), erythrocyte sedimentation rate (ESR), liver function tests (LFT), renal function tests (RFT) and urine routine and microscopy were done for all patients. Radiological examination was done wherever required.

The statistical analysis was performed using the SPSS software version 20.0 (SPSS Inc., Chicago, IL, USA). Continuous variables were presented as measures of central tendency and categorical variables were presented as absolute numbers and percentage.

**RESULTS**

Thirty-five out of 4032 pediatric patients reporting to our OPD between July 2016 to July 2018, were found to have genodermatoses. Hence the incidence of genodermatoses in pediatric population was recorded as 0.87%.

**Table 1: Age and diagnosis wise distribution of cases.**

Diagnosis	No. and percentage of cases in each age group			
	0-6 years	7-12 years	13-18 years	Total
	N (%)	N (%)	N (%)	N (%)
Neurofibromatosis	1 (2.86)	1 (2.86)	4 (11.43)	6 (17.14)
Tuberous sclerosis	0	3 (8.57)	3 (8.57)	6 (17.14)
Ectodermal dysplasia	1 (2.86)	2 (5.71)	1 (2.86)	4 (11.43)
Ichthyosis	2 (5.71)	1 (2.86)	0	3 (8.57)
Pachyonychia congenita	0	1 (2.86)	2 (5.71)	3 (8.57)
Hereditary palmo-plantar keratoderma	2 (5.71)	1 (2.86)	0	3 (8.57)
Oculo-cutaneous albinism	2 (5.71)	0	0	2 (5.71)
Progeria	0	1 (2.86)	1 (2.86)	2 (5.71)
Others	3 (8.57)	2 (5.71)	1 (2.86)	6 (17.14)
<b>Total</b>	<b>11 (31.43)</b>	<b>12 (34.29)</b>	<b>12 (34.29)</b>	<b>35 (100)</b>

**Table 2: Sex and diagnosis wise distribution of cases.**

Diagnosis	Males	Females	Total
	N (%)	N (%)	N (%)
Neurofibromatosis	3 (8.57)	3 (8.57)	6 (17.14)
Tuberous sclerosis	4 (11.43)	2 (5.71)	6 (17.14)
Ectodermal dysplasia	2 (5.71)	2 (5.71)	4 (11.43)
Ichthyosis	2 (5.71)	1 (2.86)	3 (8.57)
Pachyonychia congenita	0	3 (8.57)	3 (8.57)
Hereditary palmo-plantar keratoderma	0	3 (8.57)	3 (8.57)
Oculo-cutaneous albinism	2 (5.71)	0	2 (5.71)
Progeria	2 (5.71)	0	2 (5.71)
Others	2 (5.71)	4 (11.43)	6 (17.14)
<b>Total</b>	<b>17 (48.57)</b>	<b>18 (51.43)</b>	<b>35 (100)</b>

These cases belonged to the age range of 0-18 years. Out of which 12 (34.28%) cases each were in the age group of 7-12 and 13-18 years respectively, while 11 (31.43%) participants were in the age group of 0-6 years (Table 1).

There was no sexual predilection in the study group. The male:female ratio was 0.94:1 (Table 2).

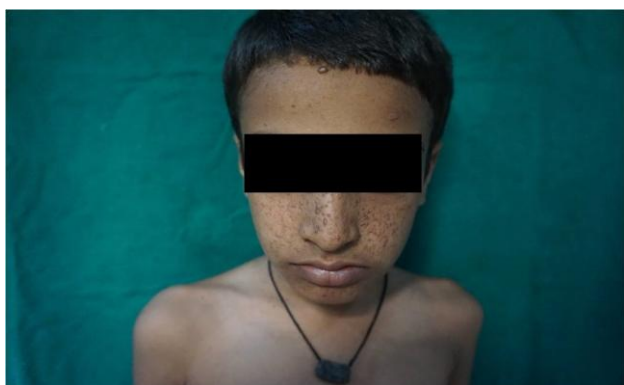Mode of inheritance was autosomal dominant in 20 (57.14%) cases, autosomal recessive in 11 (31.43%) cases, X-linked dominant in one (2.86%) case and X-linked recessive in three (8.57%) cases, respectively.

Sixteen (45.72%) cases had positive family history- 8 (22.86%) cases of autosomal dominant, 6 (17.14%) of autosomal recessive, 1 (2.86%) of X-linked dominant and 1 (2.86%) of X-linked recessive mode of inheritance, respectively.

Twenty-seven (77.14%) cases had non-consanguineous parents, while consanguinity was recorded in parents of only 8 (22.86%) cases.

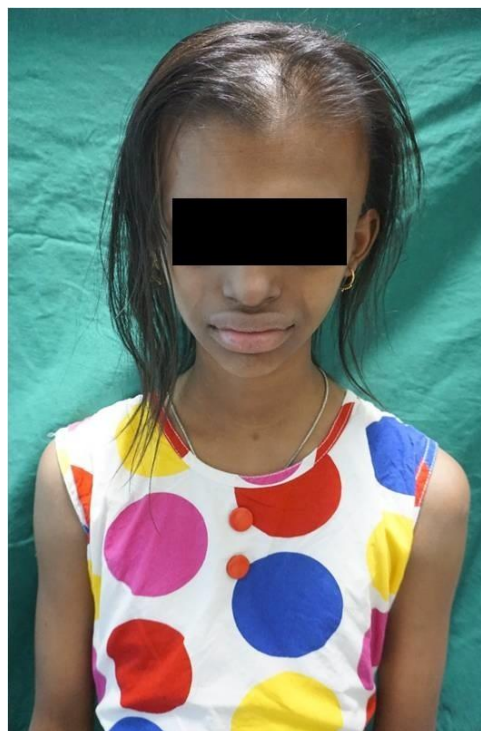Neurofibromatosis (NF) and Tuberous sclerosis (TSc) were the commonest genodermatoses with 6 (17.14%) cases each; followed by Ectodermal dysplasia with 4 (11.43%) cases; ichthyosis, pachyonychia congenita and hereditary palmoplantar keratoderma with 3 (8.57%) cases each and oculo-cutaneous albinism and progeria with 2 (5.71%) cases each, respectively. Remaining 6 (17.14%) included one case each of Menkes disease, Darier's disease, incontinentia pigmenti, Hermansky-Pudlack syndrome, Chediak-Higashi syndrome and Griscelli syndrome.

Café-au-lait macules (CALMs) were the most consistent feature seen in all six cases of NF with presence of neurofibromas and axillary freckles in 3 (50%) cases each. Amongst the extra-cutaneous manifestations, Lisch nodules in the eyes were the commonest feature seen in 3 (50%) cases. Other less common features included dystrophic scoliosis, splenomegaly and hydrocephalus in one case and nystagmus and diarrhea in another.



**Figure 1: Angiofibromas in a case of tuberous sclerosis.**

Angiofibromas were the commonest cutaneous feature seen in all 6 cases of TSc (Figure 1) followed by Shagreen patch in 5 (83.33%) patients. CALMs and confetti macules were recorded in 2 (33.33%) cases each, while ash leaf macule was seen in 1 (16.67%) patient only. An association of Becker's nevus with TSc was seen in one case. Amongst the extra-cutaneous features, cortical tubers were present in 3 (50%) cases with history of convulsions present in one of them. Other uncommon manifestations included cardiac rhabdomyomas and renal angiomyolipoma in 1 (16.67%) case and retinal hamartomas were present in another (16.67%).



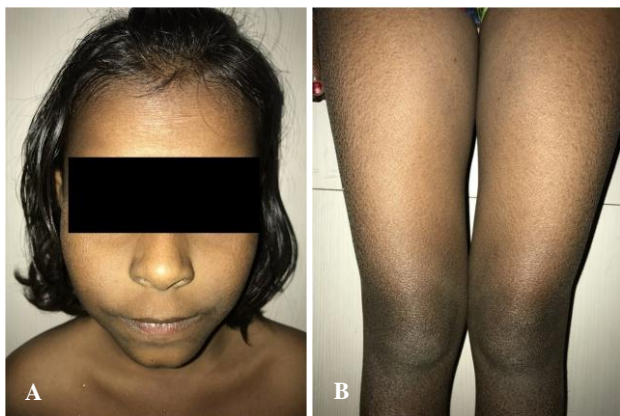**Figure 2: Ectodermal dysplasia.**

All 4 cases of ectodermal dysplasia had sparse body and scalp hair. Of these, 3 (75%) cases presented with hypohidrosis and 1 (25%) with anhidrosis. 2 (50%) patients presented with saddle nose and sunken eyeballs; out of whom frontal bossing was seen in 1 (25%) case and peg teeth, protruded lips and hoarseness of voice in another (Figure 2). History of recurrent respiratory tract infection was present in 1 (25%) case.

Nail changes were present in all three cases of pachyonychia congenita, with twenty nail dystrophy and palmoplantar keratoderma seen in 2 (66.67%) cases and additional follicular keratosis in one of them. The third case presented with nail plate thickening, subungual hyperkeratosis, distal onycholysis and focal enamel loss (33.33%).

Out of the three cases of ichthyosis, 2 (66.67%) were of Ichthyosis vulgaris with extreme xerosis of skin all over the body except flexural areas (Figure 3 A and B). The

third case was of recessive X-linked ichthyosis presenting with xerotic skin over neck, abdomen and all four limbs sparing the palms and soles. This child had history of recurrent infection (5-6 episodes/year), preterm delivery and neonatal intensive care unit (NICU) admission for 15 days. His sibling was suffering from Chediak-Higashi syndrome.



**Figure 3: (A) Case of ichthyosis vulgaris; (B) lower extremities depicting ichthyosis vulgaris in same patient.**

Out of the three cases of hereditary palmo-plantar keratoderma, one was diagnosed with Naxos syndrome having woolly hair, nontransgradient palmo-plantar keratoderma and right heart disease (right bundle branch block, antero-septal myocardial ischemia and t-wave inversion). The second case was found to have malde-malada syndrome with diffuse transgradient palmo-plantar keratoderma, hyperhidrosis, maceration with superadded candidal intertrigo and nail dystrophy, with disease onset during infancy. The third case showed punctate palmo-plantar keratoderma without any associated features.

Both cases of oculo-cutaneous albinism presented with skin, hair and iris hypopigmentation. Photophobia and poliosis were observed in both patients. Horizontal pendular nystagmus and diarrhea were extra-cutaneous features present in one of them.

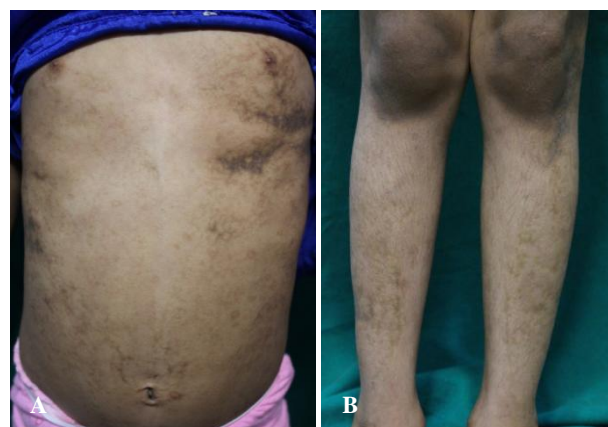
Two siblings with progeria presented with sparse scalp and eyebrow hair, sclerodermatous skin changes on trunk and extremities, prominent scalp veins, generalized lipodystrophy and loose wrinkled skin especially over hands and feet. The extra-cutaneous manifestations included protruding ears, prominent eyes, frontal and parietal bossing, beaked nose, dental anomalies, protruberant abdomen, prominent joints, growth failure and high pitched voice.

A two-year-old female patient of Chediak-Higashi syndrome presented with light-colored scalp hair since birth with skin and iris hypopigmentation. Photophobia was observed. Slight hepatosplenomegaly was noted on

examination but lymphadenopathy was absent. She had history of preterm delivery with very low birth weight of 1.6 kg and NICU admission for 15 days. She had recurrent respiratory tract infections (6-7 episodes/year). Her male twin was suffering from recessive X-linked Ichthyosis. On investigations, low hemoglobin and platelet count were noted, while TLC was normal. Presence of large intracytoplasmic neutrophilic granules confirmed the diagnosis of Chediak-Higashi syndrome.

A nine-year-old male patient with suspected Hermansky-Pudlak syndrome presented with hypopigmented skin with lentigines and brown hair. The extra-cutaneous manifestations included nystagmus, photophobia, loss of visual acuity and history of easy bruisability and recurrent epistaxis. His peripheral blood smear was normal.

A three-year-old male of Menkes syndrome presented with silvery, twisted, kinky and fragile scalp hair associated with mental retardation, bone deformities and repeated infections. He had history of having floppy body, seizures and regression of developmental milestones since infancy. Microscopic examination of scalp hair revealed pili torti and trichorrhexis nodosa.



**Figure 4: (A) Case of Incontinentia pigmenti with hyperpigmented blaschkoid lesions; (B) hyperpigmented blaschkoid lesions of Incontinentia pigmenti on lower extremities of same case.**

A seven-year-old female patient of incontinentia pigmenti presented with hyperpigmented Blaschkoid lesions on the trunk and extremities (Figure 4 A and B). The diagnosis was considered due to history of presence of fluid-filled lesions which after sometime became warty. The extra-cutaneous manifestations included strabismus, decreased visual acuity and developmental delay.

A 14-year-old female patient of Darier's disease presented with multiple dirty, warty hyperkeratotic papules over face, trunk and limbs and palmar pits. Nail changes included plate thinning, subungual

hyperkeratosis and V-shaped nicking of the nail free edges.

Lastly, a five-year-old female patient of Griscelli syndrome presented with low-grade fever, jaundice, light-brown to silver coloured hair and ill-defined facial hyperpigmentation. The extra-cutaneous manifestations included hepatomegaly, convulsions and regression of developmental milestones. Microscopic hair examination revealed irregular clumping of pigment in hair shaft. CBC revealed low hemoglobin and platelet count with normal TLC.

Amongst the cutaneous lesions present in all the cases, CALMs were the commonest, seen in 8 (22.86%) cases; followed by angiofibromas and sparse body and scalp hair in 6 (17.14%) cases each; palmoplantar keratoderma, nail dystrophy, light coloured hair and Shagreen patch in 5 (14.28%) patients each; neurofibromas, axillary freckles, ichthyosis and hypohidrosis in 3 (8.57%) cases each and confetti macules in 2 (5.71%) cases. Besides these, ash leaf macule, hyperkeratotic papules, follicular keratosis, blaschkoid lesions, Becker's nevus, anhidrosis and V-shaped nick in the nails were present in 1 (2.86%) case each.

Amongst the extra-cutaneous manifestations, ocular anomalies were the commonest, present in 12 (34.38%) cases manifesting as Lisch nodules, nystagmus, photophobia, decreased visual acuity and sunken eyeball; followed by CNS anomalies present in 7 (20%) patients manifesting as cortical tubers, convulsions, hypotonia, developmental delay and mental retardation; recurrent infections in 6 (17.14%) cases; bone anomalies in 5 (14.28%) cases; nasal anomalies manifesting as saddle or beaked nose and dental anomalies in 4 (11.43%) cases each; frontal bossing and voice changes in 3 (8.57%) cases each; cardiac anomalies in 2 (5.71%) patients and one (2.86%) case with renal anomalies.

## DISCUSSION

Genodermatoses consign to an inherited skin disorder associated with structure and function. Several genodermatoses present with multisystem involvement leading to increased morbidity and mortality. In our study, a total of 35 patients were enrolled and studied in detail.

In the present study the incidence of genodermatoses was 0.87%. In another study, by Kumar et al, the incidence was recorded as 0.62%.<sup>4</sup> The exact incidence of these disorders is not reported in the literature but it is believed that at least 1% of all live births had these disorders inherited in a simple Mendelian fashion.<sup>5</sup>

The cases belonged to the age range of 0-18 years. Majority (57.14%) cases belonged to the first decade of life. This is similar to the results demonstrated in the study by Purkait.<sup>6</sup>

The male:female ratio in the study population was 0.94:1, indicating no sexual predilection. In the studies by Katibi and Purkait the male:female ratio were 1.25:1 and 1.09:1 respectively, indicating a slight male preponderance.<sup>6,7</sup>

Mode of inheritance was autosomal dominant in 20 (57.14%) cases, autosomal recessive in 11 (31.43%) cases, X-linked dominant in 1 (2.86%) case and X-linked recessive in 3 (8.57%) cases respectively. Similar frequency of inheritance for such type of disorders had been reported by other workers.<sup>4</sup>

Positive family history was recorded in 16 (45.72%) cases- 8 (22.86%) cases of autosomal dominant, 6 (17.14%) of autosomal recessive, 1 (2.86%) of X-linked dominant and 1 (2.86%) case of X-linked recessive mode of inheritance, respectively. Amongst 20 autosomal dominantly inherited cases, 8 (40%) cases had positive family history. Kumar recorded positive family history in 29.4% cases of autosomal dominant genodermatoses.<sup>4</sup> Such low incidence presence of family history in autosomal dominant disorders can be explained on the basis of new mutation which is frequent in autosomal dominant traits, low expressivity of gene in parent and extramarital paternity.<sup>8</sup> Increased paternal age has been noticed in sporadic cases of most autosomal dominant disorders.<sup>9</sup> Amongst the autosomal recessively inherited cases, affected persons may or may not have a positive family history of the similar disorder. The risk of developing a trait can be altered by factors like environmental changes, mosaicism, mutations etc.<sup>10</sup> In cases of X-linked recessive disorders, characteristic pattern of inheritance was observed. Only males were affected and the trait was being transmitted from carrier mother to their sons.<sup>4</sup>

Consanguinity was recorded in parents of 8 (22.86%) patients overall, out of which 5 (62.5%) cases were autosomal recessively inherited disorders and 3 (37.5%) were autosomal dominantly inherited disorders. None of the cases with X-linked inheritance had consanguineous parents. Out of a total of 11 autosomal recessively inherited cases, only 5 (45.45%) had consanguineous parents, while remaining six (54.55%) cases had non-consanguineous parents. In all these cases, disease developed because a) parents who are heterozygotes (carriers) will have a quarter of their children affected b) if one parent is affected and the other a heterozygous carrier for the same gene, half of their children are affected and c) if both the parents are affected and defective for the same gene then all children are affected.<sup>10</sup>

NF and TSc were the commonest genodermatoses (17.14% each); followed by Ectodermal dysplasia (11.43%); ichthyosis, pachyonychia congenita and hereditary palmoplantar keratoderma (8.57% each) and oculo-cutaneous albinism and progeria (5.71% each), respectively. Remaining 6 (17.14%) cases included one case each of Menkes disease, Darier's disease,

Incontinentia pigmenti, Hermansky-Pudlack syndrome, Chediak-Higashi syndrome and Griscelli syndrome. Contrary to these results, Kumar S et.al reported that out of 34 cases studied, Ichthyosis (55.88%) was the commonest in pediatric age group, followed by Acrodermatitis enteropathica (11.76%), Palmoplantar keratoderma and Epidermolysis bullosa (8.82% each), Cutis laxa (5.88%) and one case each of TSc, Pachyonychia congenita and Hypomelanosis of Ito (2.94%).<sup>4</sup>

Amongst neurofibromatosis patients, CALMs was the commonest cutaneous manifestation seen in all 6 cases, followed by axillary freckles and neurofibromas in 3(50%) cases each. Purkait R et.al observed similar findings in their study.<sup>6</sup> While in a study by Obringer et.al, CALMs were recorded in similar frequency but axillary freckles and neurofibromas were recorded in 81% and 15% cases respectively.<sup>11</sup>

Amongst the extra-cutaneous manifestations, Lisch nodules in the eyes were recorded in three (50%) cases. Purkait et.al and Obringer et.al observed Lisch nodules in 45.45% and 30% cases respectively.<sup>6,11</sup> Skeletal anomalies were recorded in one (16.67%) case, in our study while Purkait et.al and Obringer et.al detected skeletal anomalies in 0.09% and 6.67% cases.<sup>6,11</sup>

Angiofibromas were the commonest cutaneous feature seen in all 6 cases of TSc followed by Shagreen patch in 5 (83.33%) cases, hypopigmented macules (confetti and ash leaf macules) were recorded in 3 (50%) cases and CALMs in 2 (33.33%) cases. These results were in concordance with other studies. Incidence of angiofibromas was noted to be high in various studies, ranging from 88% to 100%.<sup>6,12,13,14</sup> Incidence of Shagreen patch was almost similar to the incidence in other Indian studies (65%, 66.7% and 77.7%).<sup>6,12,14,15</sup> Lower incidences of hypopigmented macules recorded as 55.5% and 65% were noted in other studies.<sup>14</sup> In a study, CALMs were occasional cutaneous findings seen in 28.3% cases. A rare association of Becker's nevus with TSc was seen in one case of our study.<sup>16</sup>

Amongst the extra-cutaneous features, cortical tubers were present in 3 (50%) cases with history of convulsions present in one of them. In contrast, Purkait et al reported cortical tubers in 91.3% cases with convulsions recorded in 78.2% cases. Another study demonstrated cortical tubers in 13.3-30% cases.<sup>17</sup> Other uncommon manifestations included cardiac rhabdomyomas and renal angiomyolipoma in 1 (16.67%) case and retinal hamartomas were present in another (16.67%). Purkait et.al demonstrated cardiac rhabdomyomas and renal angiomyolipomas in 30.43% and 13% cases. Nath et al demonstrated in his study, presence of retinal hamartomas in 40% cases, cortical tubers in 30% cases and renal angiomyolipomas in 10% cases.<sup>15</sup> Retinal hamartomas have been reported in 1.2-6.7% of patients in other studies.<sup>14,17</sup>

All four cases of ectodermal dysplasia had sparse body and scalp hair. Out of which, 3 (75%) cases presented with hypohidrosis and 1 (25%) with anhidrosis. Two (50%) cases presented with saddle nose and sunken eyeballs; out of whom frontal bossing was seen in 1 (25%) case and peg teeth, protruded lips and hoarseness of voice in another. History of recurrent respiratory tract infection was present in one (25%) case. These results were consistent with findings of studies conducted by Clarke et al and Mehta et al.<sup>18,19</sup>

Nail changes were present in all three cases of pachyonychia congenita, with twenty nail dystrophy and palmoplantar keratoderma seen in 2 (66.67%) cases and additional follicular keratosis in one of them. The third case presented with nail plate thickening, subungual hyperkeratosis, distal onycholysis and focal enamel loss (33.33%). These findings were consistent with previous studies.<sup>20,21</sup>

Two (66.67%) out of the 3 cases of ichthyosis, were of ichthyosis vulgaris with autosomal dominant inheritance. The third case was of recessive X-linked ichthyosis. This child had history of recurrent infection (5-6 episodes/year). His sibling was suffering from Chediak-Higashi syndrome. Thus autosomal dominant ichthyosis was the commonest followed by X-linked ichthyosis (33.33%). Such pattern of ichthyosis has been documented in other studies as well.<sup>4,22,23</sup>

Out of the three cases of Hereditary palmo-plantar keratoderma, one was diagnosed with Naxos syndrome having woolly hair since birth, nontransgradient palmo-plantar keratoderma developed at the age of two years and right heart disease was diagnosed coincidentally in routine ECG at three years of age. The latter is in contrast to the usual presentation of heart disease in adolescence.<sup>24</sup>

The second case of palmoplantar keratoderma was considered to be Malde-malada syndrome because of consanguineous parents resulting in autosomal recessive inheritance, disease onset in infancy, transgradient typical glove and socks like hyperkeratosis, hyperhidrosis, maceration with superadded candidal intertrigo and nail dystrophy. Other similar cases have been described in literature.<sup>25,26</sup>

Oculo-cutaneous albinism (OCA) presented with skin, hair and iris hypopigmentation, poliosis and photophobia in both the cases. Nystagmus was the extra-cutaneous features present in one (50%) case. Karen et al observed similar findings in his study. OCA is the commonest inherited disorder of generalized hypopigmentation, with an estimated frequency of 1:20,000 in most population. The inheritance pattern is autosomal recessive.<sup>27,28</sup>

Two siblings who were diagnosed to have progeria, presented with typical clinical manifestations of the disease as has been reported in other studies. Progeria is a

premature aging syndrome. The earliest feature is growth failure which usually occurs in infancy. Its exact etiology is unknown, but point mutations in lamin A (LMNA) gene is considered as a cause. Its incidence is about one in 4-8 million newborns. Cutaneous manifestations are earlier to appear followed by skeletal and cardiovascular systems. In our case cardiovascular system was normal.<sup>29,30</sup>

The clinical presentation of the Chediak-Higashi syndrome (CHS) patient is similar to that mentioned in other studies. CHS is a rare autosomal recessive multisystem disorder of infancy or early childhood, caused by mutations in a single gene- *LYST* gene localized to 1q42-43.<sup>31</sup>

The Hermansky-Pudlak syndrome (HPS) case presented with hypopigmentation of skin and hair, ocular anomalies and easy bruisability. HPS is an autosomal recessive disorder characterized by oculocutaneous albinism, platelet storage-pool deficiency and lysosomal accumulation of ceroid lipofuscin. The albinism results in iris transillumination, variable degrees of skin and hair hypopigmentation and congenital nystagmus, which is always present in these patients. Strabismus is commonly associated with this condition but was absent in our patient. Bleeding is the leading cause of mortality in these patients.<sup>32,33</sup>

Three-year-old male presenting with light-coloured, twisted scalp hair associated with mental retardation and repeated infections with history suggestive of hypotonia, convulsions and developmental delay, was considered to have Menkes syndrome because microscopic examination of scalp hair revealed pili torti and trichorrhexis nodosa. Menkes syndrome is a rare X-linked recessive disorder of copper metabolism, where intestinal copper uptake is normal, but copper transport to other tissues is affected. The defective protein is a copper-binding ATPase, ATP7A.<sup>34,35</sup>

A seven-year-old female patient of incontinentia pigmenti presented with hyperpigmented blaschkoid lesions on the trunk and extremities. The diagnosis was considered due to history of evolution of the typical lesions associated with this condition. These findings were consistent with other studies. Also known as Sulzberger syndrome, it is an uncommon genodermatosis that primarily affects female infants, inherited by X-linked dominant gene and is lethal in males. Classically, it manifests with linear vesicular lesions evolving into verrucous lesions within a few weeks and followed by peculiar swirled pigmentation which lasts for many years.<sup>36</sup>

Darier's disease was considered in a 14-year female because of its typical presentation with multiple dirty, warty hyperkeratotic papules over face, trunk and limbs and palmar pits. Nail plate thinning, subungual hyperkeratosis and V-shaped nicking of the free edges of

nails were observed. These findings were consistent with previous studies.<sup>37,38</sup>

Griscelli syndrome was considered in one case due to typical presentation of partial albinism of hair and skin, fever, hepatomegaly, anemia and thrombocytopenia and neurologic involvement. Microscopic hair examination revealed irregular clumping of pigment in hair shaft. Griscelli syndrome is a rare autosomal recessive disease characterized by pigmentary dilution of skin and hair, variable cellular immunodeficiency and an acute phase of uncontrolled T lymphocyte and macrophage activation leading to fatal hemophagocytic syndrome.<sup>39,40</sup>

Thus, besides the dermatological manifestations, extracutaneous features, especially ocular and CNS anomalies have been observed in the aforementioned cases. This reflects the multisystem involvement commonly associated with genodermatoses.

## CONCLUSION

The incidence of genodermatoses, was found to be 0.87%, with majority cases belonging to the first decade of life. Positive family history was recorded in 45.72% patients with autosomal dominant pattern being the commonest mode of inheritance. Neurofibromatosis and tuberous sclerosis were the commonest genodermatoses reported from our study. Café-au-lait macules and ocular anomalies were the most common cutaneous and extracutaneous manifestations, in our study.

Since there is dearth of data pertaining to clinical presentation of genodermatoses, our study provides a baseline data for future researches. Because phenotypic heterogeneity is known in these syndromes, further studies are required to consolidate these results. The rarity of genodermatoses and lack of awareness in this context are the major drawbacks in the planning of research in this speciality.

## Limitations

Lack of genetic testing required for definitive diagnosis and subjective nature of history provided by the patients/guardians.

## ACKNOWLEDGEMENTS

I am extremely grateful to Gen. (Dr.) Y.K. Sharma, Professor Emeritus, Department of Dermatology, Venereology and Leprosy, for his patience and motivation. He played a pivotal role in this work with his unerring accuracy and ability to solve the problems promptly.

*Funding: No funding sources*

*Conflict of interest: None declared*

*Ethical approval: The study was approved by the institutional ethics committee*

## REFERENCES

- Pandhi D. Current status of genodermatoses: An Indian perspective. *Indian J Dermatol Venereol Leprol.* 2015;81:7-9.
- Sybert VP. Genetic skin disorders. New York: Oxford University Press; 2017: 1.
- Cantatore-Francis MJL, Glick SA. Prenatal diagnosis of genodermatoses: current scope and future capabilities. *Int J Dermatol.* 2010;49(4):353-61.
- Kumar S, Sharma RC. Genodermatoses in paediatric age group. *Indian J Dermatol Venereol Leprol.* 1996;62:235-6.
- Pembrey ME. Genetic factors in disease. In: Weather Hall DJ, Leellingham JGG, Warell DA, eds. Oxford textbook of medicine. London: Oxford University Press, 1987; 4.1-4.40.
- Purkait R, Samanta T, Thakur S, Dhar S. Neurocutaneous syndrome: A prospective study. *Indian J Dermatol.* 2011;56:375-9.
- Katibi OS, Dlova NC, Chateau AV, Mosam A. The prevalence of paediatric skin conditions at a dermatology clinic in KwaZulu-Natal Province over a 3-month period. *SAJCH.* 2016;10(2):121-5.
- Mckusick VA. Genetics and dermatology. *J Invest Dermatol.* 1973;60:343-59.
- McGrath JA, McLean WHI. Genetics in relation to the skin. In: Wolff K, Goldsmith LA, Katz SI, Gilchrist B, Paller A, Laffell D, editors. Fitzpatrick's dermatology in general medicine. 7th ed. New York: McGraw-Hill; 2008: 73-87.
- Kumaran MS, De D. Basic genetics for dermatologists. *Indian J Dermatol Venereol Leprol.* 2013;79:457-68.
- Obringer AC, Meadows AT, Zackai EH. The diagnosis of neurofibromatosis 1 in the child under the age of 6 years. *Am J Dis Child.* 1989;143:717-9.
- Ghosh SK, Debabrata B, Gobinda C, Ghosh A, Sharmila S, Somenath S. Mucocutaneous Changes In Tuberous Sclerosis Complex: A Clinical Profile Of 27 Indian Patients. *Indian J Dermatol.* 2009;54:255-7.
- Rama Rao GR, Krishna Rao PV, Gopal K, Kumar YH, Ramachandra BV. Forehead plaque: A cutaneous marker of CNS involvement in tuberous sclerosis. *Indian J Dermatol Venereol Leprol.* 2008;74:28-31.
- Jeevan KB, Thappa DM, Narasimahan R. The cutaneous features of tuberous sclerosis: A hospital based study in south India. *Indian J Dermatol.* 2001;46:149-53.
- Nath J, Dubey A, Pavan R. Analysis of twenty pediatric cases of tuberous sclerosis complex: Are we doing enough?. *Indian J Dermatol Venereol Leprol.* 2015;81:23-8.
- JóŸwiak S, Schwartz RA, Janniger CK, Michaowicz R, Chmielik J. Skin lesions in children with tuberous sclerosis complex: Their prevalence, natural course, and diagnostic significance. *Int J Dermatol.* 1998;37:911-7.
- Tonekaboni SH, Tousi P, Ebrahimi A, Ahmadabadi F, Keyhanidoust Z, Zamani GH, et al. Clinical and Para clinical Manifestations of Tuberous Sclerosis: A Cross Sectional Study on 81 Pediatric Patients. *Iran J Child Neurol.* 2012;6:25-31.
- Clarke A, Phillips DI, Brown R, Harper PS. Clinical aspects of X-linked hypohidrotic ectodermal dysplasia. *Arch Dis Child.* 1987;62:989-96.
- Mehta U, Brunworth J, Fete TJ, Sindwani R. Head and neck manifestations and quality of life of patients with ectodermal dysplasia. *Otolaryngol Head Neck Surg.* 2007;136:843-7.
- Leachman SA, Kaspar RL, Fleckman P, Florell SR, Smith FJ, McLean WH, et al. Clinical and pathological features of pachyonychia congenita. *J Investig Dermatol Symp Proc.* 2005;10:3-17.
- Anneroth G, Isacson G, Lagerholm B, Lindvall AM, Thyresson N: Pachyonychia congenita. A clinical, histological and microradiographic study with special reference to oral manifestations. *Acta Derm Venereol.* 1975;55:387-94.
- Rand RE, Baden HP. The ichthyoses-a review. *J Am Acad Dermatol.* 1983;8:285.
- Well RS, Kerr CB. Clinical features of autosomal dominant and autosomal recessive ichthyosis in an English population. *Br Med J.* 1966;1:947-50.
- Rai R, Ramachandran B, Sundaram V S, Rajendren G, Srinivas C R. Naxos disease: A rare occurrence of cardiomyopathy with woolly hair and palmoplantar keratoderma. *Indian J Dermatol Venereol Leprol.* 2008;74:50-2.
- Yadav BS, Sonawane SN, Deshpande PR, Risbud. Palmoplantar keratoderma - Mal de Meleda type. *Indian J Dermatol Venereol Leprol.* 1994;60:359-61.
- Jee SH, Lee YY, Wu YC, Lü YC, Pan CC. Report of a family with Malde meleda in Taiwan, a clinical, histopathological and immunological study. *Dermatologica.* 1985;171:30-7.
- Gronskov K. Oculocutaneous albinism. *Orphanet J Rare Dis.* 2007;2:43.
- Rao VA, Swathi P, Chaitra, Thappa DM. Bilateral keratoconus with oculocutaneous albinism. *Indian J Dermatol Venereol Leprol.* 2008;74:407-9.
- Agarwal US, Sitaraman S, Mehta S, Panse G. Hutchinson-Gilford progeria syndrome. *Indian J Dermatol Venereol Leprol.* 2010;76:591.
- Badame AJ. Review of progeria. *Arch Dermatol.* 1989;125:540-4.
- Rudramurthy P, Lokanatha H. Chediak-higashi syndrome: A case series from Karnataka, India. *Indian J Dermatol.* 2015;60:524.
- Bagheri A, Abdollahi A. Hermansky-Pudlak Syndrome;a Case Report. *J Ophthalmic Vis Res.* 2010;5(4):269-72.
- Hermansky F, Pudlak P. Albinism associated with hemorrhagic diathesis and unusual pigmented reticular cells in the bone marrow: report of two



- cases with histochemical studies. *Blood.* 1959;14:162-9.
34. Choudhary SV, Gadegone RW, Koley S. Menkes kinky hair disease. *Indian J Dermatol.* 2012;57:407-9.
  35. Menkes JH. Kinky hair disease. *Pediatrics* 1972;50:181-3.
  36. Agarwal P. Incontinentia pigmenti. *Indian J Dermatol Venereol Leprol.* 1997;63:368-9.
  37. Udagani M M, Siddaramappa B, Shankar R, Swamy B. Darier's disease. *Indian J Dermatol Venereol Leprol.* 1991;57:162.
  38. Bedi BMS, Garg BR. Darier's disease, *Ind J Dermatol Venereol Leprol.* 1978;44:145-8.
  39. Kumar T S, Ebenazar S, Moses PD. Griscelli syndrome. *Indian J Dermatol.* 2006;51:269-71.
  40. Griscelli C, Durandy A, Guy-Grand D, Daguillard F, Herzog C, Prunieras M. A syndrome associating partial albinism and immunodeficiency. *Am J Med.* 1978;65:691-702.

**Cite this article as:** Dalave K, Deora MS, Sabhandasani S, Singh P, Mittal A, Shah B. Clinico-epidemiological study of genodermatoses in pediatric age group. *Int J Res Dermatol* 2020;6:34-42.