

Case Report

Four sexually transmitted diseases in one: a rare case report

S. D. Fernandes, N. Jegadish, R. Ramachandran, K. Gopalakrishnan, Murali Narasimhan*

Department of DVL, SRM Medical College Hospital and RC, Potheri, Tamil Nadu, India

Received: 23 October 2019

Revised: 10 December 2019

Accepted: 12 December 2019

***Correspondence:**

Dr. Murali Narasimhan,

E-mail: leecutis@gmail.com

Copyright: © the author(s), publisher and licensee Medip Academy. This is an open-access article distributed under the terms of the Creative Commons Attribution Non-Commercial License, which permits unrestricted non-commercial use, distribution, and reproduction in any medium, provided the original work is properly cited.

ABSTRACT

Sexually transmitted diseases (STDs) often pose a diagnostic challenge especially in countries like India, where access to reliable diagnostic laboratory tests is minimal. The exact cause of the STDs has to be determined, so that appropriate therapy can be administered and the risk of transmission to others can be reduced. However, determining the etiology can be complicated by limitations of current diagnostic testing modalities and by the fact that more than one infection may coexist. Here, authors report a case who presented with genital ulcer disease and discharge with four etiologies.

Keywords: Candidal Balanoposthitis, Genital herpes simplex, Gonorrhoea, Sexually transmitted diseases, Syphilis

INTRODUCTION

Sexually Transmitted Infections (STIs) are a loosely defined constellation of infections and syndromes that are epidemiologically heterogeneous but all of which are almost always or at least often transmitted sexually.¹ Sexually Transmitted Diseases (STD) are caused by variety of pathogens, including viruses, bacteria, fungi, and parasitic, which manifest themselves in a wide variety of clinical symptoms.² Bacterial STDs include syphilis, gonorrhea, chancroid, lymphogranuloma venereum, granuloma inguinale, chlamydial, mycoplasmal, and ureaplasma infections. Viral STDs include molluscum contagiosum, genital warts, herpes genitalis, CMV, EBV, HIV, viral hepatitis. Fungal STDs include candidiasis. Parasitic infections include trichomoniasis, scabies and pediculosis pubis. Various risk factors that predispose to STI include HIV infection, unprotected sexual contact with the infected partner, homosexuality, intravenous (IV) drug abuse, alcohol addiction, and anal penetration.³⁻⁵ Effective case management involves correctly diagnosing and treating symptomatic and asymptomatic patients, providing

patient education for consistent condom use and partner management to prevent reinfection and transmission to others. And multiple etiologies should always be kept in mind while dealing with STD cases.⁶

CASE REPORT

An unmarried 28 years old male presented to the STD OPD with complaints of genital ulcers for 7 days, genital discharge for 3 days and fever for 2 days. Patient denied history of any sexual contact. On examination, three well defined, non-tender ulcers with indurated base of size 0.5 cm in diameter were noted over glans penis. Radial fissuring was noted over prepuce (Figure 1). Subpreputial discharge was present. Perianal soddening was seen. Bilateral inguinal lymph nodes were enlarged, firm and non-tender. 10% KOH mount showed abundant, short, stout, septate and unbranched pseudo hyphae with spores seen (Figure 2). Spirochetes were demonstrated by dark field microscopy. Tzanck smear showed multinucleated giant cells (Figure 3). Gram staining of subpreputial discharge showed numerous pus cells with intracellular gram-negative cocci in pairs (Figure 4).

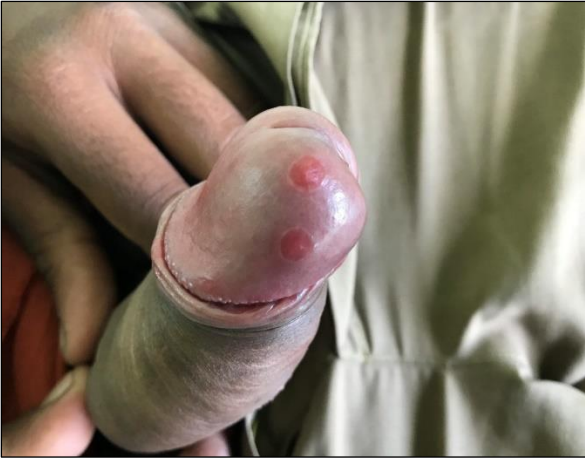

Figure 1: Well defined, non-tender ulcers with indurated base of size 0.5 cm in diameter over glans penis.

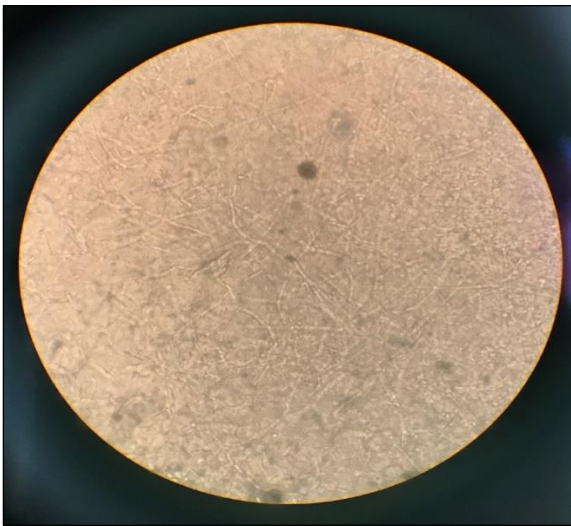


Figure 2: 10% KOH showing abundant, short, stout, septate and unbranched pseudohyphae with spores.

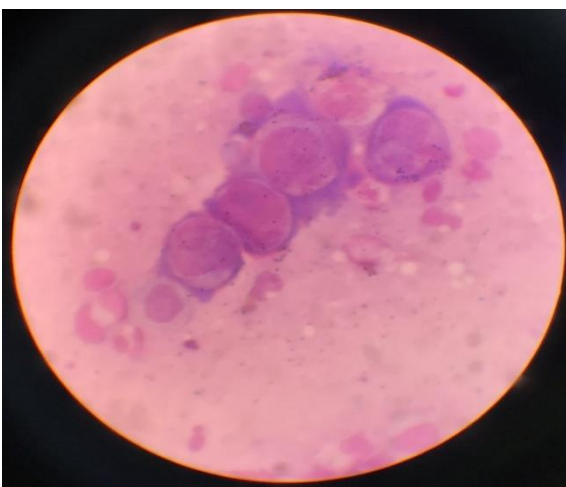


Figure 3: Tzanck smear showing multinucleated giant cells.

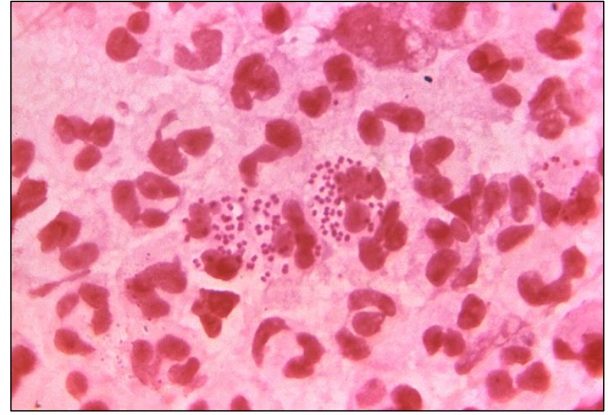


Figure 4: Gram staining showing numerous pus cells with intracellular gram-negative cocci in pairs.

RPR was reactive. Serology for HbSAg, HCV and HIV were negative. Hence a diagnosis of syphilis with genital herpes simplex type 2, gonorrhoea and candidal balanoposthitis was made. Patient was treated with inj. ceftriaxone 250 mg i.m. (single dose), tab. azithromycin 1g (stat dose), inj. benzathine penicillin 2.4 million units im (single dose), tab. acyclovir 400 mg t.i.d. for 7 days and tab. fluconazole 150 mg PO (stat dose).

DISCUSSION

Both ulcerative and nonulcerative STIs promote HIV transmission by augmenting Human Immunodeficiency Virus (HIV) infectiousness and susceptibility.⁷ Hence, providing earlier “treatment for prevention” has the potential to significantly lessen infectivity and decrease transmission to uninfected partner.⁸ However, in countries like India, accurate diagnosis is a challenge due to limited accessibility to proper diagnostic facilities. Multiple STIs in same patient may be present in 1.7% to 9%.^{9,10} Hence, it is essential to rule out possible STDs, considering multiple etiologies. Besides treating the patient, counselling on consistent condom use and treatment of partner are key strategy in management of STDs.

CONCLUSION

Although, multiple etiologies should always be considered in any patient with venereal disease, it is very unusual to find four etiological agents simultaneously in the same patient. Hence this case is reported for its rarity.

Funding: No funding sources

Conflict of interest: None declared

Ethical approval: Not required

REFERENCES

1. Marfatia YS, Sharma A, Joshipura SP. Overview of sexually transmitted diseases. In: Valia RG, Valia AR, eds. IADVL Textbook of Dermatology. 3rd

- edition. Volume 59. Mumbai: Bhalani Publishing House; 2008: 1766-1778.
2. King K, Holmes, P, Frederick Sparling, Walter E. Stamm, Peter Piot, Judith N. Wasserheit, Lawrence Corey, Myron S. Cohen and D. Heather Watts. Sexually Transmitted Diseases. 4th edition. The McGraw-Hill Companies: New York; 2007: 3.
 3. Jamison DT, Breman JG, Measham AR, Alleyne G, Claeson M, Evans DB, et al. Disease control priorities in developing countries. World Bank; 2006;3:311-30.
 4. UNAIDS. AIDS Epidemic Update: December 2005. Geneva: UNAIDS; 2005.
 5. Verma RK, Collumbien M. Homosexual activity among rural Indian men: implications for HIV interventions. *Aids.* 2004;18(13):1845-7.
 6. DiCarlo RP, David HDH. The clinical diagnosis of genital ulcer disease in men. *Clin Infec Dis.* 1997;25(2):292-8.
 7. Shafii T, Burstein GR. An overview of sexually transmitted infections among adolescents. *Adolesc Med Clin.* 2004;15(2):201.
 8. Cohen MS, Chen YQ, McCauley M, Gamble T, Hosseinipour MC, Kumarasamy N, et al. Prevention of HIV-1 infection with early antiretroviral therapy. *New Eng J Med.* 2011;365(6):493-505.
 9. Nyati A, Gupta S, Jain SK, Yadav D, Patidar BL, Sharma M. A retrospective study of the pattern of sexually transmitted infections from a tertiary care hospital of Rajasthan. *Ind J Sexu Trans Dis AIDS.* 2017;38(2):147.
 10. Prabhakar P, Narayanan P, Deshpande GR, Das A, Neilsen G, Mehendale S, et al. Genital ulcer disease in India: etiologies and performance of current syndrome guidelines. *Sexu Trans Dis.* 2012;39(11):906-10.

Cite this article as: Fernandes SD, Jegadish N, Ramachandran R, Gopalakrishnan K, Narasimhan M. Four sexually transmitted diseases in one: a rare case report. *Int J Res Dermatol* 2020;6:272-4.