

Case Report

Bleomycin-induced flagellate pigmentation: a case report from North-East India

Nandakishore Thokchom, Nandita Bhattacharjee*, Linda Kongbam

Department of Dermatology, Venereology and Leprology, Regional Institute of Medical Sciences, Imphal, Manipur, India

Received: 31 July 2019

Accepted: 04 October 2019

***Correspondence:**

Dr. Nandita Bhattacharjee,

E-mail: piyubhattacharjee@gmail.com

Copyright: © the author(s), publisher and licensee Medip Academy. This is an open-access article distributed under the terms of the Creative Commons Attribution Non-Commercial License, which permits unrestricted non-commercial use, distribution, and reproduction in any medium, provided the original work is properly cited.

ABSTRACT

Bleomycin is an antitumour antibiotic commonly used in the management of Hodgkin's lymphoma and germ cell tumours. Flagellate pigmentation is a very specific and rare cutaneous adverse effect of bleomycin. It is characterised by linear, painless, pruritic, hyperpigmented lesions simulating marks of whiplashes over trunk and extremities. With the advent of targeted therapies resulting in the infrequent use of bleomycin, this unique side effect is also uncommonly encountered nowadays. Here, we report a case of bleomycin-induced flagellate pigmentation in a 35-year-old Indian female with ovarian teratoma. The characteristic patterned hyperpigmented patches developed following 2nd cycle of chemotherapy with bleomycin, etoposide and cisplatin.

Keywords: Bleomycin, Flagellate, Pigmentation

INTRODUCTION

Flagellate pigmentation is a rare and unique side effect of systemic bleomycin. Bleomycin is an antitumour antibiotic, used for Hodgkin's lymphoma and germ cell tumours. Bleomycin induced flagellate hyperpigmentation was first reported by Moulin et al in 1970.¹ It is seen in 10-20% of patients treated with systemic bleomycin.² The incidence of flagellate hyperpigmentation is decreasing due to the infrequent use of bleomycin. We report here a case of bleomycin-induced flagellate pigmentation in a 35-year-old female with ovarian teratoma.

CASE REPORT

A 35-year-old lady was referred from the department of radiation oncology with history of itchy, hyperpigmented lesions over neck, trunk and extremities for one month. She was earlier diagnosed with ovarian immature teratoma. She was on 4th cycle of combination

chemotherapy bleomycin, etoposide and cisplatin (BEP regimen) including bleomycin 30 mg, etoposide 130 mg and cisplatin 26 mg. The lesions developed after two cycles of chemotherapy. At onset, the patient developed generalised itching followed by erythematous linear streaks over neck, back and upper extremities. It was followed by dark brownish discolouration of the areas of scratching within 2 days. There was no history of any physical abuse or mushroom intake.

General physical examination was normal except for pallor. On cutaneous examination, multiple, well defined, hyperpigmented, non-tender, non-scaly, linear streaks were present over neck (Figure 1A), left shoulder (Figure 1B), trunk and extremities (Figure 1C). The size of the streaks ranged from 5-20 mm in width and 2-6 cm in length. Longitudinal melanonychia was present over right sided toe nails (Figure 2). Oral mucosa and genitalia were not involved. Systemic examination was normal. All the routine blood investigations were within normal limit except hemoglobin 8.2 gm%. Histopathological

examination showed orthokeratotic epidermis, basal layer hypermelanosis with underlying dermis histologically unremarkable (Figure 3). Based on the history of bleomycin use and the typical clinical presentation, the diagnosis of bleomycin-induced flagellate pigmentation was made. The patient was treated with topical clobetasol and antihistamines. She was then switched to bleomycin sparing regimen for management of ovarian teratoma. On follow up, the itching was relieved, but the hyperpigmented streaks showed minimal improvement.

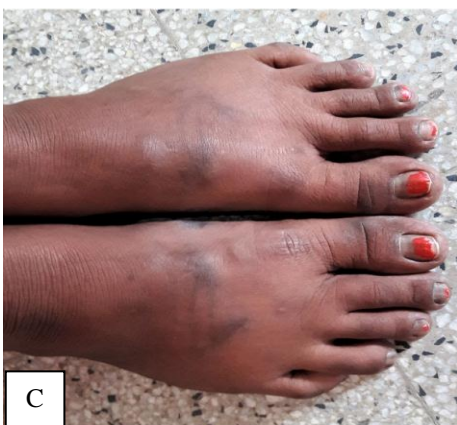
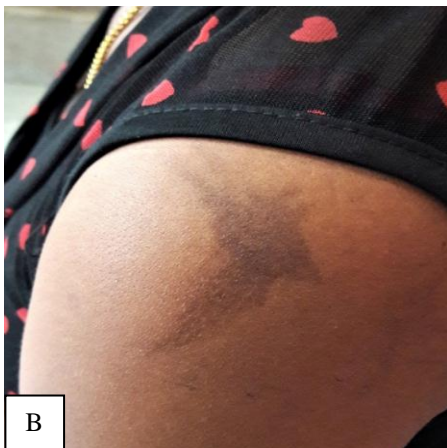
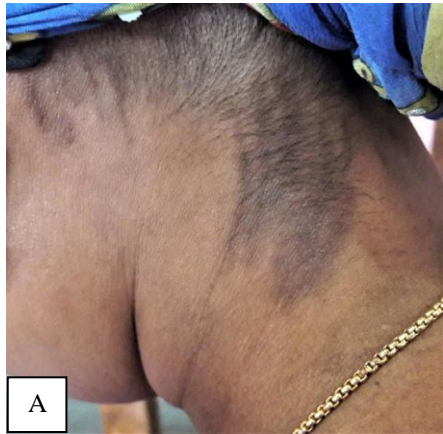Figure 1: (A) Linear hyperpigmented streaks over neck, (B) left shoulder and (C) dorsum of bilateral feet.

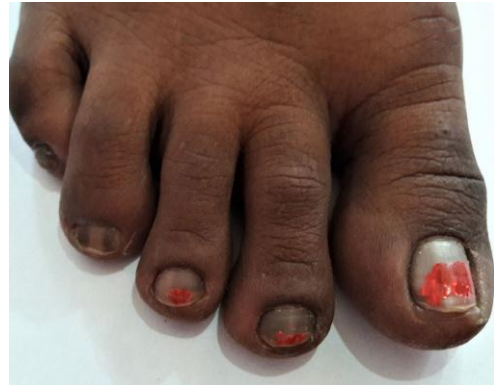

Figure 2: Longitudinal melanonychia over right sided toe nails.

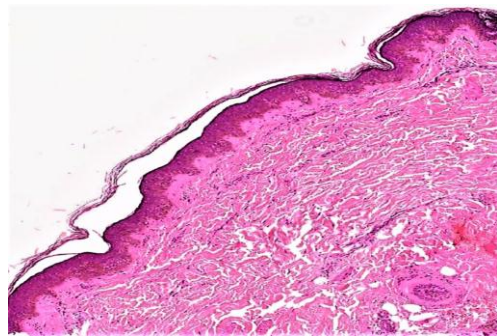


Figure 3: Orthokeratotic epidermis with basal layer hypermelanosis (H and E, 40X).

DISCUSSION

Bleomycin-induced flagellate pigmentation is an unusual and distinctive presentation of drug toxicity. The adverse effects of bleomycin predominantly involve skin and respiratory system due to lack of inactivating enzyme, bleomycin hydrolase in these tissues.³ The pathogenesis of this pigmentation remains unclear and many hypotheses have been proposed as microtrauma leading to local leakage of bleomycin, increased melanogenesis and altered pigment maturation.⁴ Flagellate pigmentation has also been reported with trastuzumab, following consumption of Shiitake mushroom, adult-onset Still's disease and dermatomyositis.^{2,7}

Flagellate pigmentation is relatively uncommon in adults and rare in children.⁵ It usually presents 12-24 hours to 9 weeks after initiation of bleomycin.² In our patient, the lesions appeared after 2 cycles of BEP therapy. Sharma et al also reported similar lesions after 2 cycles of BEP.⁵ The flagellate pigmentation generally appears after cumulative dose of 100-300U of bleomycin, but doses as low as 14U has been reported following intralesional injections in verruca.⁶ In the present case, the cumulative dose of bleomycin was 70U. Bleomycin-induced flagellate dermatitis starts as linear, painless, pruritic, erythematous streaks over accessible areas of trunk and extremities along the lines of scratching or pressure areas followed by persistent pigmentation. The pigmentation

may be diffuse, patchy or linear. The patient appears to be whipped over multiple areas of body. It may be associated with circumscribed hyperpigmentation over joints, melanonychia or sclerodermoid changes.^{8,9} In our patient, flagellate pigmentation was preceded by pruritic, erythematous streaks over neck, trunk and extremities at onset over areas of scratching and melanonychia was present over right sided toe nails. The histopathological findings are non-specific, varying from basal layer hypermelanosis to spongiosis with perivascular lymphohistiocytic infiltrates as seen in stage of erythema.² In our patient, histopathological examination showed orthokeratotic epidermis with basal layer hypermelanosis.

There is no specific therapy available for flagellate pigmentation. The lesions are self-limiting and gradually resolve after discontinuation of the offending drug. Associated pruritus is treated with oral antihistamines and topical steroids.^{9,10} In the present case, the patient was treated with topical clobetasol and oral antihistamine followed by symptomatic relief.

This case is being reported to highlight the classical and unique cutaneous adverse effect of bleomycin therapy as similar patterned pigmentation is not seen with any other antitumour antibiotic.

Funding: No funding sources

Conflict of interest: None declared

Ethical approval: Not required

REFERENCES

1. Moulin G, Fiere B, Beyvin A. Cutaneous pigmentation caused by bleomycin. Bull Soc Fr Dermatol Syphiligr. 1970;77:293-6.
2. Chang MW. Disorders of hyperpigmentation. In: Bologna JL, Schaffer JV, Cerroni L, editors. Dermatology. 4th ed. China: Elsevier Limited; 2018: 1115-1143.
3. Vuerstaek JD, Frank J, Poblete-Gutierrez P. Bleomycin-induced flagellate dermatitis. Int J Dermatol. 2007;46(3):3-5.
4. Grynspan R, Niemeyer-Corbellini JP, Lopes MS, Ramos-e-Silva M. Bleomycin-induced flagellate dermatitis. BMJ Case Rep. 2013;2013:bcr2013009764.
5. Sharma P, Sinha R, Kumar D, Kumar A. Bleomycin-induced flagellate dermatosis in a 7-Year-Old child: A case report with review of literature. Indian J Paediatr Dermatol. 2018;19:339-41.
6. Abess A, Keel DM, Graham BS. Flagellate hyperpigmentation following intralesional bleomycin treatment of verruca plantaris. Arch Dermatol. 2003;139:337-9.
7. Cohen PR. Trastuzumab-associated flagellate erythema: Report in a woman with metastatic breast cancer and review of antineoplastic therapy-induced flagellate dermatoses. Dermatol Ther. 2015;5:253-64.
8. Gaurkar SP, Mehta N, Parmar KS, Shah BJ. Bleomycin-induced flagellate dermatitis. Indian J Drugs Dermatol. 2015;1:38-40.
9. Basu D, Podder I, Das A. Bleomycin-induced flagellate hyperpigmentation: a case report with review of literature. Pigment Int. 2016;3:40-2.
10. Larson KN, Gagnon AL, Wilson BB. Bleomycin-induced flagellate hyperpigmentation. Clin Case Rep. 2017;5(4):429-30.

Cite this article as: Thokchom N, Bhattacharjee N, Kongbam L. Bleomycin-induced flagellate pigmentation: a case report from North-East India. Int J Res Dermatol 2019;5:879-81.