

## Original Research Article

# Mucocutaneous manifestations among persons receiving highly active anti-retroviral therapy

Vijaya Anand M., Parimalam Kumar\*, Nandagopal K.

Department of DVL, Government Kilpauk Medical College, Affiliated to The Tamil Nadu Dr. MGR Medical University, Chennai, India

**Received:** 20 November 2016

**Revised:** 23 December 2016

**Accepted:** 26 December 2016

**\*Correspondence:**

Dr. Parimalam Kumar,

E-mail: [drparimalam@gmail.com](mailto:drparimalam@gmail.com)

**Copyright:** © the author(s), publisher and licensee Medip Academy. This is an open-access article distributed under the terms of the Creative Commons Attribution Non-Commercial License, which permits unrestricted non-commercial use, distribution, and reproduction in any medium, provided the original work is properly cited.

### ABSTRACT

**Background:** Mucocutaneous manifestations in patients positive for HIV are helpful in the diagnosis as well as treatment of the disease. Consequent to the introduction of Highly Active Anti-Retroviral Therapy (HAART), there seems to be an increase in the presentation of non-infective diseases. It was aimed to analyse the mucocutaneous manifestations in HIV infected patients taking HAART and correlate with age and CD4 lymphocyte count.

**Methods:** A retrospective analysis of 125 People Living With HIV (PLWH) having mucocutaneous manifestations receiving HAART who attended a tertiary care city hospital over a period of ten months from January 2016 to October 2016 was carried out. The findings were correlated with CD4 count and age. The data were collected from the patient follow up cards maintained by qualified Dermatovenereologist.

**Results:** There was no major gender difference in our study. The trans genders presented with only non-infectious skin diseases. Younger patients had a higher CD4 count ( $p=0.01\%$ ) which was statistically significant. Candidiasis and pruritic papular eruption were the commonest infective and non-infective diseases observed respectively. The mean CD4 count comparison was statistically significant ( $p=0.04$ ). The count was highest for insect bite allergy and lowest for oral hairy leukoplakia. The mean age of disease manifestation was highest for Herpes zoster and lowest for aphthous ulcers 45 and 29 years respectively. All the adverse reactions observed were to efavirenz.

**Conclusions:** With the improvement of CD4 count in PLWH receiving HAART, the proportion of non-infectious inflammatory disease manifestations are on the rise. Awareness about this fact is very important for effective management.

**Keywords:** Mucocutaneous manifestations, Opportunistic infection, HIV, HAART, CD4 count

### INTRODUCTION

It was in 1986 the first documented evidence of HIV infection in India made.<sup>1</sup> Since then various citations about the mucocutaneous manifestations of HIV infected persons were recognized. After the introduction of Highly Active Anti-Retroviral Therapy (HAART) the medical and paramedical fields have started witnessing a change in the clinical presentation of PLWH receiving HAART.

If not all, in more than 90% of patients with HIV, mucocutaneous manifestation is observed.<sup>1,2</sup> Thus making a thorough dermatological examination is mandatory in all suspected cases of HIV infection as these findings can serve as a guide to the diagnosis and assess the severity.<sup>3,4</sup> Such observation may perhaps help initiation of therapy where facility for CD4 count is not available. CDC classification system for HIV infected adults and adolescents has divided those who are positive

for HIV into three major categories 1, 2 and 3 based on the CD4 count having <200 cells/ $\mu$ L; 200-499 cells/ $\mu$ L and >500 cells/ $\mu$ L respectively.<sup>6</sup> It is well known that certain disease manifestations are more commonly seen in a particular category and some are seen in all categories. While candidiasis is seen in all stages of HIV infection, Kaposi's sarcoma is mainly seen if the CD4 count is very low i.e. <200. We aimed to analyse the different mucocutaneous manifestations and correlate with age and CD4 count in PLWH receiving HAART.

**METHODS**

We undertook a cross sectional retrospective study to analyse the different mucocutaneous manifestations in PLWH receiving HAART who attended a tertiary care city hospital over a period of ten months from January 2016 to October 2016 were included for the study. Those with diabetes were excluded from the study. All patients were seen by a qualified Dermatovenereologist and diagnosis was confirmed with lab tests wherever necessary. The National AIDS Control (NACO)

guidelines were followed for documenting the findings on the patient follow up card. Required data like age, sex, CD4 count and the clinical and final diagnosis were collected retrospectively from the patient performance card maintained in the department.

**Statistical analysis:** All the data were entered in the required fields in the excel sheet. Statistical analysis was done using Chi square test and One-way ANOVA F-test. The resultant data were analysed with reference to correlation between the clinical findings, age and CD4 count. Our observations were compared with previous literature.

**RESULTS**

Out of the 125 patients studied, 63 were males. The youngest patient was 12 and the oldest was 76 years old respectively. The age and sex distribution is given in Table 1 and 2. While there has been no significant difference in the sex distribution, both the trans-genders recorded in our study had non- infective diseases.

**Table 1: Age wise CD4 count seen in 125 PLWH on HAART having mucocutaneous manifestations.**

Age	CD4						Total	Chi square test
	< 200		200 -499		>500			
	n	%	n	%	n	%		
< 30 years	7	25.9%	11	40.7%	9	33.3%	27	
31 -40 years	17	30.4%	14	25.0%	25	44.6%	46	$\chi^2=16.35$ P=0.01 significant
41 -50 years	17	58.6%	8	27.6%	4	13.8%	29	
> 50 years	6	46.2%	6	46.2%	1	7.7%	13	
	47		39		39		125	

**Table 2: Sex wise disease pattern seen in 125 PLWH on HAART.**

Disease	Sex					
	Male		Female		Transgender	
	n	%	n	%	n	%
<b>Apthus</b>	1	50.0%	1	50.0%		
<b>Candidiasis</b>	32	52.5%	29	47.5%		
<b>Herpes Zoster</b>	1	100.0%				
<b>Oral Hairy Leukoplakia</b>	1	50.0%	1	50.0%		
<b>Dermatophytosis</b>	2	40.0%	3	60.0%		
<b>Eczema</b>			1	100.0%		
<b>Folliculitis</b>	2	50.0%	2	50.0%		
<b>Herpes Simplex</b>			1	100.0%		
<b>Insect bite reaction</b>			1	100.0%		
<b>Impetigo</b>			1	100.0%		
<b>Itching</b>	1	50.0%	1	50.0%		
<b>Pruritic papular eruption</b>	12	57.1%	8	38.1%	1	4.8%
<b>Drug reaction</b>	7	41.2%	9	52.9%	1	5.9%
<b>Pityriasis versicolor</b>	4	66.7%	2	33.3%		

**Table 3: Mucocutaneous manifestations seen in different categories of CD4 count in 125 PLWH on HAART.**

Muco-Cutaneous Manifestations	CD4					
	Category I		Category II		Category III	
	< 200		200 -499		>500	
	n	%	n	%	n	%
<b>Apthus</b>			1	50.0%	1	50.0%
<b>Candidiasis</b>	32	52.5%	13	21.3%	16	26.2%
<b>Herpes Zoster</b>	1	100.0%				
<b>Oral Hairy Leukoplakia</b>	2	100.0%				
<b>Dermatophytosis</b>					5	100.0%
<b>Eczema</b>					1	100.0%
<b>Folliculitis</b>			2	50.0%	2	50.0%
<b>Herpes Simplex</b>			1	100.0%		
<b>Insect bite reaction</b>					1	100.0%
<b>Impetigo</b>			1	100.0%		
<b>Pruritus</b>			1	50.0%	1	50.0%
<b>Pruritic papular eruption</b>	6	28.6%	9	42.9%	6	28.6%
<b>Drug reaction</b>	4	23.5%	10	58.8%	3	17.6%
<b>Pityriais versicolor</b>	2	33.3%	1	16.7%	3	50.0%

**Table 4: Mucocutaneous manifestations seen in 125 PLWH on HAART- agewise.**

MCM	N	Mean age	Std. Deviation	One way ANOVA F-test
<b>Apthus</b>	2	29.00	9.899	F=1.11 P=0.35 significant
<b>Candidiasis</b>	61	39.59	10.503	
<b>Herpes Zoster</b>	1	45.00	.	
<b>Oral Hairy Leukoplakia</b>	2	38.50	3.536	
<b>Dermatophytosis</b>	5	30.00	10.677	
<b>Eczema</b>	1	37.00	.	
<b>Folliculitis</b>	4	31.50	4.041	
<b>Herpes Simplex</b>	1	39.00	.	
<b>Insect bite reaction</b>	1	38.00	.	
<b>Impetigo</b>	1	34.00	.	
<b>Pruritus</b>	2	33.50	2.121	
<b>Pruritic papular eruption</b>	21	35.14	7.059	
<b>Drug reaction</b>	17	41.35	11.079	
<b>Pityriais versicolor</b>	6	34.33	5.391	

We recorded 14 different MCM, which included both infective and non-infective. Candidiasis, Dermatophytosis, Pityriais versicolor, Herpes zoster, Herpes simplex, Impetigo and folliculitis were the infective diseases and eczema, insect bite reaction, pruritus, pruritic papular eruption, adverse drug reaction and oral hairy leukoplakia were the non-infective disease. We have also observed apthous ulcers in 2 of the 125.

CD4 count and mean age for the mucocutaneous manifestations observed in 125 PLWH on HAART having mucocutaneous manifestations are given in Figure 1.

Of the infective disease, Candidiasis and pityriasis versicolor and of the non-infective diseases, Pruritic papular eruption and adverse drug reaction were observed

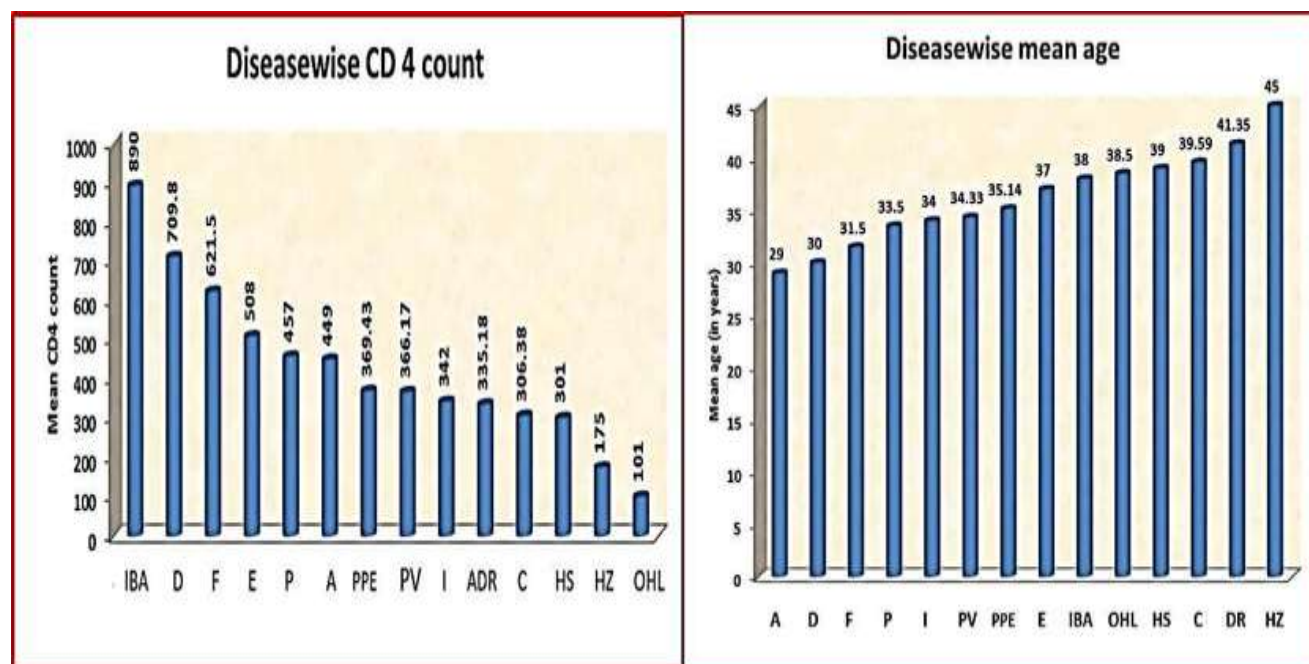
in all three categories. The details of diseases in different categories are given in Table 3.

The age wise distribution of mucocutaneous manifestations observed in our study is given in Table 4. Our study had one 12 year old male child and three adolescents.

Out of the 125 cases studied, 47 were in category I and 39 each in categories II and III. Comparison of mean CD4 count score for various are given in Table 5 and were found to be statistically significant.

**Table 5: Comparison of Mean CD4 count of manifestations seen in 125 PLWH on HAART.**

Mucocutaneous Manifestations	N	Mean	Std. Deviation	Oneway ANOVA F-test
Apthus	2	449.00	236.174	F=1.89 P=0.04 SIGNIFICANT
Candidiasis	61	306.38	283.113	
Herpes Zoster	1	175.00	.	
Oral Hairy Leukoplakia	2	101.00	97.581	
Dermatophytosis	5	709.80	130.552	
Eczema	1	508.00	.	
Folliculitis	4	621.50	188.878	
Herpes Simplex	1	301.00	.	
Insect bite reaction	1	890.00	.	
Impetigo	1	342.00	.	
Pruritus	2	457.00	362.039	
Pruritic papular eruption	21	369.43	252.214	
Drug reaction	17	335.18	172.445	
Pityriasis versicolor	6	366.17	201.324	
Total	125	356.86	265.080	



**Figure 1: CD4 count and mean age of manifestations observed in 125 PLWH on HAART.**

## DISCUSSION

There literature on mucocutaneous manifestations in HIV positive patients outnumbers those on studies exclusively with those receiving HAART. In HIV infected persons, decline in the CD4 cell count leads to many infections. This fall in CD4 count is the reason for many opportunistic infections observed in PLWH.<sup>7</sup> But one has to keep in mind that improvement in CD4 count with treatment, will lead to a paradigm shift in the mucocutaneous manifestations of PLWH from infective to non-infective diseases. In our study, patients with infective disorders were more in number when compared to those with non-infective diseases. Candidiasis was the most frequent infectious disease observed in our study as seen in many others.<sup>8-10</sup> Hoods et al have documented the reduction in oropharyngeal candidiasis subsequent to the introduction of HAART.<sup>11</sup> This explains that though candidiasis was the commonest infection seen in 61 patients out of 125, The number is lesser than what was observed in pre HAART era, it was also supported by the fact that which 52.5% of patients with candidal infection were seen in Category I. This observation is in concordance with the literature. The prevalence of dermatophytosis was observed only in 4% of our cases and all were seen in category III with CD4 count >500 indicating that there is not much of difference in the prevalence of dermatophyte infection in PLWH and general population.<sup>12</sup>

Nearly two fifth (37%) had presented with non-infectious diseases in our study. Seborrheic dermatitis, xerosis, atopic dermatitis, eosinophilic folliculitis, psoriasis, HIV-1-related pruritus and adverse drug reactions were classified as primary skin disorders of HIV the incidence of which is on the raise following HAART.<sup>13</sup> Many reports support the raising prevalence of these non-infective disorders in patients on HAART.<sup>14-20</sup> Among the non-infectious manifestations, pruritic papular eruption was found to be the most prevalent manifestation of PLWH on HAART.

Patients receiving HAART are more prone to develop drug induced reactions than the normal counter parts.<sup>21</sup> In our study, it was observed that all the 17 patients with adverse drug reaction had reacted to efavirenz and the reaction presented within the first three weeks after initiation of therapy. This is similar to a study conducted in Thailand where all the drug reactions were due to efavirenz.<sup>22</sup> According to Philips et al history of such reactions limit the choices of medications and in such cases where there is no systemic manifestation desensitisation should be ideally considered.<sup>23</sup>

Oral Hairy leukoplakia was seen in only two persons both having a CD4 count <200. This is in concordance with the literature.<sup>24</sup> We have not recorded Kaposi sarcoma in the 125 cases that we analysed. This may be due to the small sample size and out of which smaller group in category I.

Oral ulcers are not uncommon in patients with HIV. In a study of 124 HIV infected patients with oral manifestations carried out by Sontakke et al 4 patients had presented with aphthous ulcers of the mouth.<sup>25</sup> The observation of aphthous ulcers in two of our patients one each in category II and III is more or less similar to that observed in literature. However, we have not seen it occur in category I. This might give us a hope that HAART may reduce the incidence of aphthous ulcerations by improving the CD4 count.

## CONCLUSION

There has been a paradigm shift in the mucocutaneous manifestation of HIV infected persons receiving HAART. Due to increase in the CD4 count the incidence of opportunistic infections have come down while that of the non-infective diseases are increasing with Immune reconstitution inflammatory syndrome adding to this in some patients. Awareness about such a changing trend in the clinical manifestation is required for adequate management of these recalcitrant disorders.

## ACKNOWLEDGEMENTS

We acknowledge the laboratory staff of KMCH for helping us in this study.

*Funding: No funding sources*

*Conflict of interest: None declared*

*Ethical approval: The study was approved by the institutional ethics committee*

## REFERENCES

1. Laurance J. "Suniti Solomon". *The Lancet*. 2015;386:1818.
2. Sud N, Shanker V, Sharma, A, Sharma NL, Gupta M. Mucocutaneous manifestations in 150 HIV-infected Indian patients and their relationship with CD4 lymphocyte counts. *Int J STD AIDS* 2009;20:771-4.
3. Sivayathorn A, Srihra B, Leesanguankul W. Prevalence of skin disease in patients infected human immunodeficiency virus in Bangkok, Thailand. *Ann Acad Med Singapore*. 1995;24:528-33.
4. Wiwanitkit V. Prevalence of dermatological disorders in Thai HIV-infected patients correlated with different CD4 lymphocyte count statuses: a note on 120 cases. *Int J Dermatol*. 2004;43:265-8.
5. Foroughi M, Koochak HE, Roosta N, Paydary K, Khatami A, Shahriari S, et al. Prevalence of dermatologic manifestations among people living with HIV/ AIDS in Imam Khomeini Hospital in Tehran, Iran. *J AIDS HIV Res*. 2012;4:56-9.
6. HIV Classification: CDC and WHO Staging Systems. Available at <https://www.aidsctc.org/guide/hiv-classification->



- cdc-and-who-staging-systems. Accessed 20 November 2016.
7. Cedeno-Laurent F, Gomez-Flores M, Mendez N, Ancer-Rodriguez J, Bryant JL, Gaspari AA, Trujillo JR. New insights into HIV-1-primary skin disorders. *J Int AIDS Soc.* 2011;14:5.
  8. Azfar NA, Khan AR, Zia MA, Humayun A, Malik LM, Jahangir M. Frequency of mucocutaneous manifestations in HIV positive Pakistani patients. *J Pak Assoc Dermatol.* 2011;21:149–53.
  9. Spira R, Mingard M, Doutre MS, Molart P, Dabis F. Prevalence of cutaneous disorders in a population of HIV-infected patients. *Arch Dermatol.* 1998;134:1208–12.
  10. Berger TG, Greene I. Bacterial, viral, fungal, and parasitic infections in HIV disease and AIDS. *Dermatol Clin.* 1991;14:465–92.
  11. Hood S, Bonington A, Evans J, Denning D. Reduction in oropharyngeal candidiasis following introduction of protease inhibitors. *AIDS.* 1998;12(4):447–8.
  12. Özlem AA, Hayat KK, Ramazan K, Mehmet O, Özcan N. Mucocutaneous manifestations and the relationship to CD4 lymphocyte counts among Turkish HIV/AIDS patients in İstanbul, Turkey. *Turk J Med Sci.* 2015;45:89-92.
  13. Cedeno-Laurent F, Gómez-Flores M, Mendez N, Ancer-Rodríguez J, Bryant JL, Gaspari AA, et al. New insights into HIV-1-primary skin disorders. *J Int AIDS Soc.* 2011;24(14):5.
  14. Resneck JS Jr, Van Beek M, Furmanski L, Oyugi J, LeBoit PE, Katabira E, et al. Etiology of pruritic papular eruption with HIV infection in Uganda. *JAMA.* 2004;14:2614–21.
  15. Froschl M, Land HG, Landthaler M. Seborrheic dermatitis and atopic eczema in human immunodeficiency virus infection. *Semin Dermatol.* 1990;14:230–2.
  16. Ackerman AB. Histopathologic differentiation of eczematous dermatitides from psoriasis and seborrheic dermatitis. *Cutis.* 1977;14:619–23.
  17. Eisenstat BA, Wormser GP. Seborrheic dermatitis and butterfly rash in AIDS. *N Engl J Med.* 1984;14:189.
  18. Rowe A, Mallon E, Rosenberger P, Barrett M, Walsh J, Bunker CB. Depletion of cutaneous peptidergic innervation in HIV-associated xerosis. *J Invest Dermatol.* 1999;14: 284–9.
  19. Singh F, Rudikoff D. HIV-associated pruritus: etiology and management. *Am J Clin Dermatol.* 2003;14:177–88.
  20. Majors MJ, Berger TG, Blauvelt A, Smith KJ, Turner ML, Cruz PD Jr. HIV-related eosinophilic folliculitis: a panel discussion. *Semin Cutan Med Surg.* 1997;14:219–23.
  21. Todd G. Adverse cutaneous drug eruptions and HIV: a clinician's global perspective. *Dermatol Clin.* 2006;14:459–72.
  22. Punyaratabandhu P, Prasithsirikul W, Jirachanakul J. Skin Manifestation of Thai HIV Infected Patients in HAART Era. *J Med Assoc Thai.* 2012;95(4):497-504.
  23. Phillips EJ, Kuriakose B, Knowles SR. Efavirenz-induced skin eruption and successful desensitization. *Ann Pharmacother.* 2002;36(3):430-2.
  24. Khammissa RA, Fourie J, Chandran R, Lemmer J, Feller L. Epstein-Barr Virus and Its Association with Oral Hairy Leukoplakia: A Short Review. *Int J Dent.* 2016;4941783.
  25. Sontakke SA, Umarji HR, Karjodkar F. Comparison of oral manifestations with CD4 count in HIV-infected patients. *Indian J Dent Res.* 2011;22:732.

**Cite this article as:** Vijaya Anand M, Kumar P, Nandagopal K. Mucocutaneous manifestations among persons receiving highly active anti-retroviral therapy. *Int J Res Dermatol* 2017;3:124-9.