

Original Research Article

Relevance of patch testing and its correlation with clinical patterns of contact dermatitis of hand

Devaprabha Sendurpandian, M. R. Subashini*

Department of Dermatovenereology, Madurai Medical College, Madurai, Tamil Nadu, India

Received: 16 April 2019

Accepted: 03 May 2019

***Correspondence:**

Dr. M. R. Subashini,

E-mail: dr.suba91@gmail.com

Copyright: © the author(s), publisher and licensee Medip Academy. This is an open-access article distributed under the terms of the Creative Commons Attribution Non-Commercial License, which permits unrestricted non-commercial use, distribution, and reproduction in any medium, provided the original work is properly cited.

ABSTRACT

Background: Contact dermatitis of hand is a common dermatoses with different aetiological conditions and different morphologies. The aim of our study is to identify the clinical patterns, causative allergens and the relevance of patch testing for contact dermatitis of hand.

Methods: A total of 74 patients with hand eczema were included in our study after getting informed and written consent to do patch tests during December 2016 to May 2017 in our dermatology OPD. Patch test was done by using Indian standard series battery and the readings were taken at 48 hrs and 72 hrs. The results were interpreted according to International Contact Dermatitis Research Group (ICDRG) criteria.

Results: The incidence of hand eczema was 3.2 percent with male: female ratio of 1.55:1. The most common age group affected was 31-40 years. The most common morphological pattern observed in our study was fissured pattern (43%) followed by unspecified pattern (23%), hyperkeratotic (12%), lichenoid (10%), pompholyx (4%), fingertip eczema (1%), ring pattern (1%) and mixed morphology (6%). In our study, current relevance of 79% (31 allergens), doubtful relevance of 15% (6 allergens), and old relevance of 3% (one allergen) was noted. Cross sensitization was observed with one allergen (3%).

Conclusions: Patch testing is a very useful scientific diagnostic tool that unravels the cause of contact dermatitis of hand. Avoidance of the substances responsible for allergy can be advised to the patient.

Keywords: Hand eczema, Morphology, Patch test, Relevance

INTRODUCTION

Contact dermatitis of hand is an inflammatory response of skin to an exogenous substance. It can be allergic, irritant reactions and immediate contact reactions. It is usually multifactorial.¹ It is one of the commonest occupational disease. The morphological types of hand eczema are divided into hyperkeratotic, fissured, lichenoid, pompholyx, ring pattern, fingertip eczema, chronic acral dermatitis, recurrent focal palmar peeling and apron eczema. Endogenous eczema often diagnosed after excluding allergic and irritant contact dermatitis. The different morphological forms differ only in

clinically rather than histologically. The gold standard method for identifying the causative allergen is by patch testing and detailed history.

METHODS

Study place and period

The study was carried out in the department of Dermatology, Government Rajaji Hospital, Madurai Medical College, Madurai. A total of 74 patients with hand eczema who attended the dermatology OPD during December 2016 to May 2017 were included in our study

after getting consent to undergo patch testing and to take photograph.

Study group

Patients with acute dermatitis, on immunosuppressive therapy, with immune deficiency, pregnant and lactating mothers were excluded from our study.

Procedure

A thorough clinical history was elicited, regarding the nature and duration of symptoms, contact with any specific allergen with respect to their occupation, hobbies and present clinical scenario. Also history about associated medical illness, personal and family history of atopy was obtained.

A detailed dermatological examination was carried out. The morphological pattern, extent of skin lesions and the presence of oozing, crusting and lichenification were noted down.

Patients were subjected to routine blood investigations including complete hemogram, blood sugar, renal and liver function test. Patch test was performed for all 74 patients who were included in the study. For patients with acute eczema, patch test was done after 2 weeks when the lesions were completely cleared.

We did Patch test by using Indian standard series battery approved by CODFI (Contact and Occupational dermatoses forum of India), which was commercially available at Systopic laboratories. These allergens were applied on Finn chambers and strapped on the back of the patients with hypo allergenic tapes. The patches were kept undisturbed for 48 hours. Patients were advised to avoid strenuous hard work, showering and sunlight exposure. After 48 hours, the finn chambers were removed and the squares representing each chamber was marked using a marker pen. Reading and pictures were taken after half an hour. A second reading was taken after 72 hours to confirm the presence of allergic reaction. Patch test results were interpreted according to International Contact Dermatitis Research Group (ICDRG) criteria.

RESULTS

Age group and incidence

The incidence of our study was 3.2 per 100 cases. Out of 74 cases in our study, 61% were males (n=45) and 39% (n=29) were females with male to female ratio as 1.55:1. The youngest patient in our study was 18 years and the oldest was 70 years. Contact dermatitis (CD) of hand was observed highest in the age group of 31 to 40 years (28%). The mean age observed in the study was 42.3 years.

Correlation of occupation with contact dermatitis of hand

Among 74 cases, 22 were construction workers, 11 were industrial workers (plastic industry, incense sticks industry, vegetable oil industry, tyre industry, metal industry and binding work), 7 were painters, 8 were florists, 6 were health care workers (nurse, male nursing assistant and doctors), 4 were agricultural workers, a cook and a plumber one each. Miscellaneous workers were nine (photographer, police officer, fish seller, textile salesman, tailor, student, clerical work, software engineer and house maid) in our study (Figure 1).

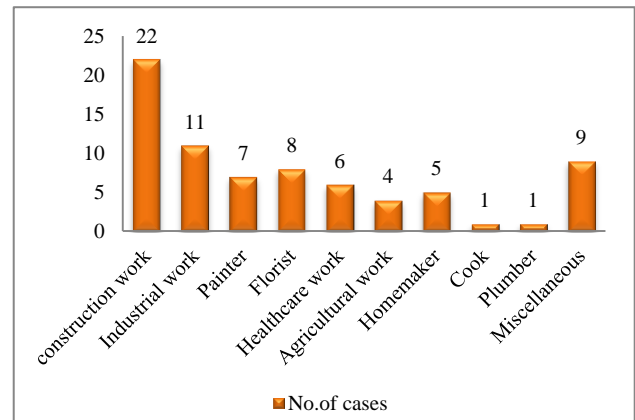


Figure 1: Correlation of occupation with contact dermatitis of hand.

Morphological patterns of contact dermatitis of hand

Fissured type of contact dermatitis of hand was observed in 32 cases (43%) which was the highest noted morphology in this study followed by unspecified in 17 cases (23%), hyperkeratotic in 9 cases (12%), lichenoid in 7 cases (10%) and pompholyx pattern in 3 cases (4%). One case (1%) each of ring eczema and fingertip eczema was noted. Combined lesions of fissured and lichenoid pattern was observed in three cases (4%), pompholyx and lichenoid pattern (2%) in one case (Figure 2).

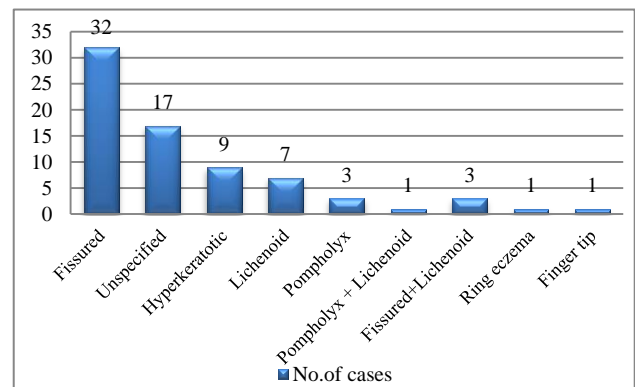


Figure 2: Morphological patterns of contact dermatitis of hand.

Patch test results

Among 74 cases, 31 cases (42%) showed allergic contact dermatitis, 41 cases (55%) did not show any positive reaction. Two cases (3%) had irritant reaction.

Table 1: Patch test results.

Allergens	Males	Females	Total
Potassium dichromate	12	2	14
PPD	4	1	5
Fragrance mix	0	4	4
Nickel	1	1	2
Parthenium	1	3	4
Epoxy resin	0	2	2
Thiuram mix	1	2	3
Colophony	2	0	2
Nitrofurazone	1	0	1
Formaldehyde	0	1	1
Neomycin	0	1	1

Among 39 positive patch test reactions, potassium dichromate was positive in 14 cases (36%) followed by paraphenylenediamine in 5 cases (13%), fragrance mix in 4 cases (10%), parthenium in 4 cases (10%), nickel in 2 cases (5%), epoxy resin in 2 cases (5%), thiuram mix in 3

cases (8%), colophony in 2 cases (5%), nitrofurazone in one case (2%), formaldehyde in one case (3%) and neomycin in one case (3%). Potassium dichromate was highest noted allergen in this study. Nitrofurazone, formaldehyde and neomycin was the least observed allergens in this study (Table 1).

Correlation of morphological patterns with allergen and its relevance

Out of 39 positive patch test reactions, fissured pattern was observed in 18 positive patch test reactions. Out of 18 positive reactions, 5 were potassium dichromate, 3 were paraphenylenediamine, 2 were parthenium, 2 were thiuram and one each of colophony, nickel, nitrofurazone, epoxy resin, neomycin and fragrance mix was noted. Lichenoid pattern was noted in one each of parthenium, potassium dichromate and thiuram mix positivity. Hyperkeratotic pattern was seen in two potassium dichromate positivity and in one PPD positivity. Pompholyx pattern was observed in one each of fragrance mix and formaldehyde sensitivity. Ring pattern was noted in nickel sensitivity. Both fissured and lichenoid pattern was observed in a mason with chromate positivity. Unspecified pattern was noted in following sensitivities, chromate (n-5), parthenium (n-1), fragrance mix (n-2), colophony (n-1), PPD (n-1) (Table 2 and Figure 3).

Table 2: Correlation of morphological patterns with allergen.

Morphological patterns	Total	Positive patch test reaction	Positive proportion (%)	Relevance			
				Current	Doubtful	Old	Cross sensitization
Fissured	32	18	56	12	5	-	1
Unspecified	17	10	58	9	-	1	-
Pompholyx	3	2	66	2	-	-	-
Lichenoid	7	3	42	3	-	-	-
Hyperkeratotic	9	3	33	2	1	-	-
Pompholyx+Lichenoid	1	0	-	-	-	-	-
Fissured+Lichenoid	3	1	33	1	-	-	-
Fingertip only	1	0	-	-	-	-	-
Ring pattern	1	1	100	1	-	-	-

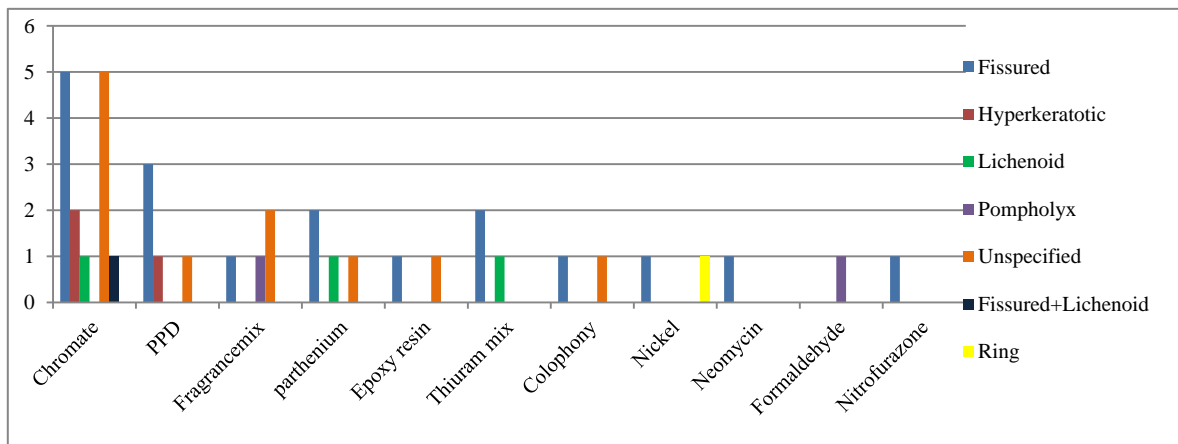


Figure 3: Correlation of morphological patterns with allergen.

Current relevance was 79% (31 allergens), doubtful relevance was 15% (6 allergens), and old relevance was 3% (one allergen) in our study. Cross sensitization was noted with one allergen (3%).

International Contact Dermatitis Research Group Criteria (ICDRG) grading of patch test

According to ICDRG criteria, out of 39 positive allergens, 83% (n-34) of reactions were 1+, followed by 2+ reactions in 12% (n-5). Irritant reaction (5%) was seen in two cases over nickel and potassium dichromate patch tested sites.

Frequency of positivity of allergens

Among 31 cases of ACD, 87% (27 cases) cases showed one allergen positivity, two allergens positivity was seen in one case (3%) followed by three allergens positivity in 2 cases (7%). Four allergens positivity was demonstrated in one case (3%) of Incense stick worker. Among 39 allergens, 37 allergens were read positive on 2nd day remaining two allergens (Nickel, Nitrofurazone) on the 4th day.

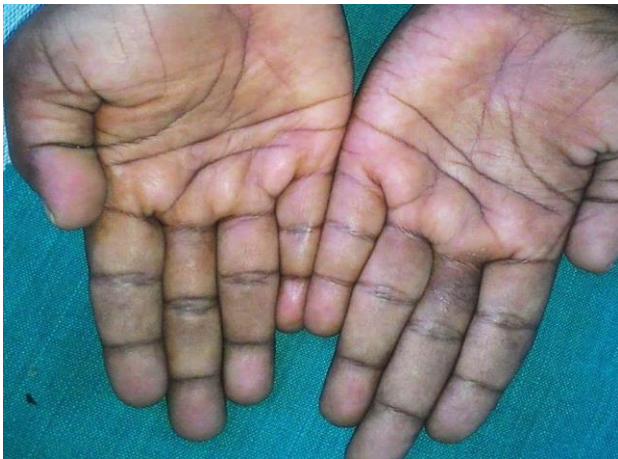

Figure 4: Nickel allergy with ring pattern.

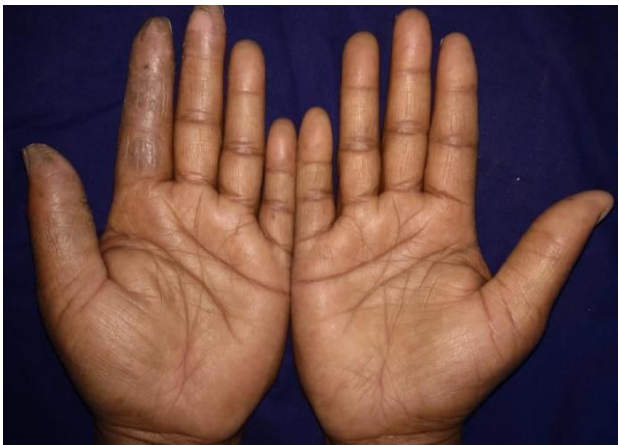

Figure 5: Fissured pattern in a florist.

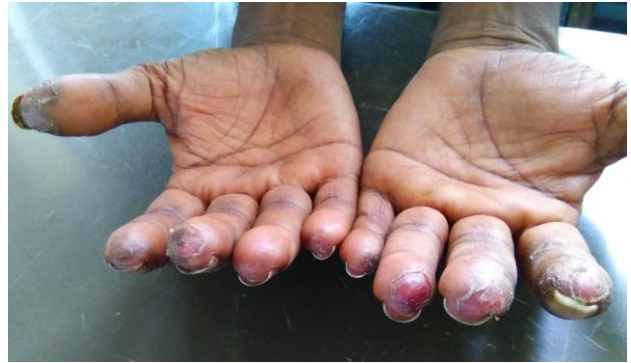

Figure 6: Fingertip eczema in a garlander.

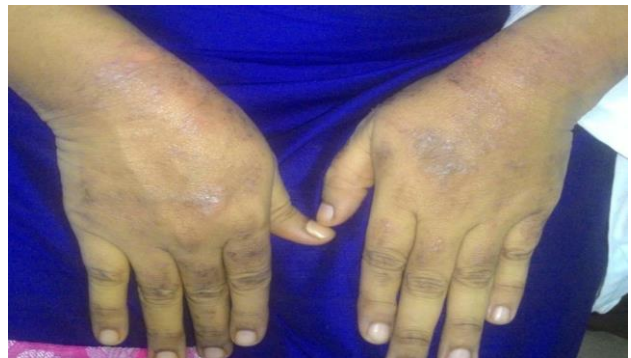

Figure 7: Latex rubber glove allergy with lichenoid pattern.

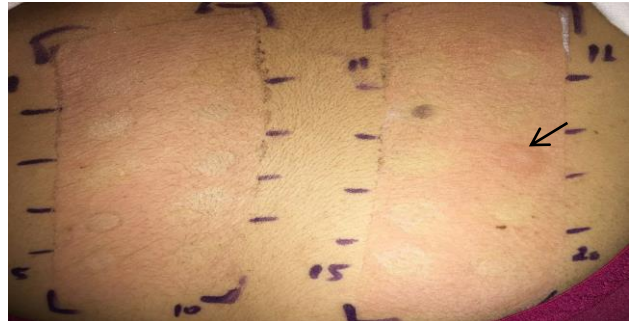

Figure 8: Thiuram mix positivity in a health care worker due to latex rubber glove allergy

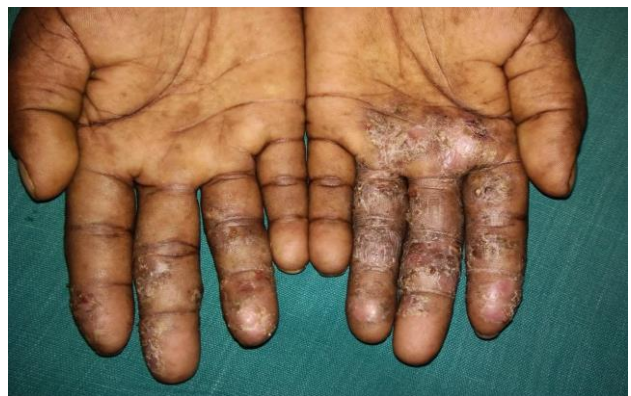

Figure 9: Unspecified eczema in a cement worker.

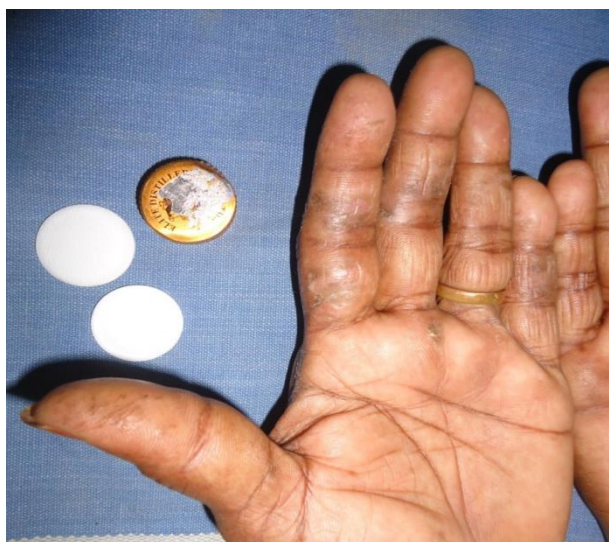

Figure 10: Epoxy resin sensitivity with unspecified pattern.

DISCUSSION

The incidence of contact dermatitis of hand among the total new adult patients who attended our OPD during the study period was found to be 3.2%.

The most common age group affected is 31-40 years, with a mean age of 42.3 years and standard deviation of 13.5 years. There was a male preponderance in this study, with a male: female ratio of 1.55:1. The male predominance in hand eczema was also noted by Kishore et al.²

Out of 74 cases, 34 cases had lesion only over dorsal aspect of hand of which 14 cases (45%) had ACD. Both dorsal and palmar involvement was seen in 25 cases out of which 11 cases (36%) had ACD. Fourteen cases had only palmar involvement of which six cases (19%) showed ACD. Our study is similar to Laxshmisha et al study in which the frequency of involvement of dorsa of hand were highest.³

Two patients with atopic diatheses showed positive patch tests. It was similar to study done by Laxsmisha et al (2%), and in contrast to Suman et al study where it was observed in 36%.⁴ The allergens associated with atopy were formaldehyde and thiuram mix showing morphological pattern as pompholyx and lichenoid respectively.

Out of 74 patients, potassium dichromate was positive in 14 cases (18.9%) followed by paraphenylenediamine (PPD) in 5 cases (6.75%), fragrance mix in 4 cases (5.4%), parthenium in 4 cases (5.4%), epoxy resin in 2 cases (2.7%), thiuram mix in 2 cases (2.7%), colophony in 2 cases (2.7%), nickel in 2 cases (5%) and one case each in nitrofurazone (1.3%), formaldehyde (1.3%) and neomycin (1.3%). Potassium dichromate was the highest

noted allergen whereas nitrofurazone, formaldehyde and neomycin were the least noted allergens in this study. Our observation is comparable to Handa et al study where the most common allergens yielding positive results were potassium dichromate (25%) followed by fragrance mix (16%), nickel sulphate (14%) and PPD (13%).

Out of 39 positive patch test reactions, fissured pattern was observed in 18 positive patch test reactions. Out of this 18, the patch test positivity for potassium dichromate was seen in 5, paraphenylenediamine in 3, parthenium in 2, thiuram mix in 2, one number of each noted in colophony, nickel, nitrofurazone, epoxy resin and fragrance mix. Lichenoid pattern was noted in one case each of parthenium, potassium dichromate and thiuram mix positivity. Hyperkeratotic pattern was seen in two potassium dichromate positivity and in one PPD positivity whereas in Kumar et al study where the allergens were fragrance mix, colophony, PPD and parthenium. Pompholyx pattern was observed in one each of fragrance mix and formaldehyde sensitivity. This pattern is highly noted with nickel in Handa et al study. Ring pattern was noted in nickel sensitivity.

The clinical pattern which cannot be classified under any category (Unspecified pattern) was noted in following sensitivities of chromate (n-5), parthenium (n-1), fragrance mix (n-2), colophony (n-1), PPD (n-1). Unspecified pattern was noted in 62 percent of patients in Handa et al study.⁵ Fingertip eczema was not associated with positivity to any allergen in our study.

Potassium dichromate sensitivity was noted in 14 cases (18.9%). Among 14 cases of potassium dichromate sensitivity, 11 cases (78%) were cement workers. Chromate sensitivity is noted high among male cement workers (9 cases) than females (2 cases). Potassium dichromate was the most common noted allergen in 35% of people which is almost similar to Handa et al study (25%). Potassium dichromate sensitivity was also noted in one each of painter, steel worker and clerical worker. Current relevance was observed in cement workers, painter and steel worker as the contact material contains potassium dichromate. The relevance could not be traced in clerical worker.

Fragrance mix sensitivity was observed in 5.4% (n-4). It is identified in two florists, one health care worker (cosmetic induced) and in one incense stick manufacturer. Current relevance is present in all four cases according to COADEX classification as the contact material contains fragrance mix as a component. Fragrance mix was highly noted allergen associated with cosmetics, detergents, soaps in Handa et al study.⁵

PPD contact sensitivity was noted in 6.75% (n-5) which is comparable with observations of Handa et al study (13%). Among 5 cases, four cases had current relevance as they all used hair dye recently. One case was classified as old relevance according to COADEX classification as

there was an exposure to hair dye in the past and developed dermatitis then. According to Pasricha, the most common cause of contact dermatitis due to cosmetics in India is hair dye.⁶

Thiuram mix allergy was 2.7% (n-2) in our study. It was relevant to current dermatitis in one obstetrician due to natural latex rubber gloves which contains thiuram mix as rubber accelerator. Thiuram mix is the one of the commonest sensitizer in rubber gloves.⁷ Other accelerators associated with glove allergy are mercaptobenzothiazole and carbamates. In this case, dermatitis was characteristically seen at both dorsum of hand with a sharp demarcation at the wrists.

Relevance of thiuram mix sensitivity could not be traced in the second case who was a cement worker though it was commonly reported in many studies where the workers used gloves for personal protection. In incense stick worker also relevance could not be traced.

Nickel sensitivity was noted in two cases (2.7%) in our study. The metal ring was the cause for the eczema in one patient and another who was a painter had also exposure to nickel containing objects (steel utensils) and hence the current relevance in both the cases. Nickel sensitivity was observed more among house wives (30%) in Handa et al study.

Epoxy resin positivity was 2.7% (2 cases) in our study. It was observed in female worker who works in beverage Bottle industry and her job was to remove inner covering of the lid which had current relevance. In another case who was working with incense stick, there were possibilities of exposure to epoxy resin (binder).

Parthenium sensitivity was observed in four cases (5.4%). Our observation was comparable with study done by Natarajan et al where it was 3.7%. Current relevance was noted in two cases of farmers and in one florist whom the dermatitis occurred mainly after contact with Artemisia genus which contains sesquiterpene lactone. In the incense stick worker relevance could not be traced for parthenium.

Neomycin sensitivity was identified in female staff nurse (1.3%). According to COADEX classification, relevance might be due to cross sensitization with kanamycin, soframycin, gentamycin as she could not recall about neomycin exposure in the past.

Nitrofurazone positivity (1.3%) was noted in a painter which was confirmed with retesting with that substance. Relevance was doubtful as patient could not recall about the details of topical medicine which he applied in the past.

In our study, special pattern was noted among florist. They (flower tiers/garlanders) had localization of dermatitis to the palmar aspect of thumb, index and

middle fingers of left hand and minimal lesion over right fingers. This correlates with contact material, flowers like jasmine, artemisia (Dhavanam or marikozhundu), marigold, nerium oleander which constantly comes in contact with left hand and intermittently over the right hand while tying the flowers.

In male flower garlanders, fingertip pattern of eczema was noted, the site in which the allergens come in contact.

According to ICDRG criteria, out of 39 positive patch test reactions, 87% (n-34) of reaction were 1+, followed by 2+ reactions in 13% (n-5). Irritant reaction (5%) was seen in two cases, one in nickel and another in potassium dichromate patch tested sites.

In our study, out of 31 ACD cases, 87% (27cases) showed single allergen positivity, 3% (one case) showed two allergens positivity and 7% (2 cases) showed three allergens positivity. Four allergens positivity was demonstrated in one case (3%) of incense stick worker. Among 39 patch test positive reactions, 37 were read positive on 2nd day, remaining two (Nickel, Nitrofurazone) on the 4th day.

In our study, current relevance of 79% (n-31), doubtful relevance of 15% (n-6), and old relevance of 3% (n-1) was noted. Cross sensitization was noted with one allergen (3%). In Handa et al study, 59.8% were relevant and in 40.2% the relevance could not be established.

Irritant reaction as follicular pustules were noted in two cases at the potassium dichromate and nickel patched sites. Patch test site erythema was noted in two cases. In our study 94% did not develop any adverse effects. This observation was closely similar to the results of the study done by Sudashree et al where 88.2% patients had no adverse reactions.⁸

CONCLUSION

Fissured pattern was the predominantly noted type followed by unspecified pattern in our study

Potassium dichromate was the most common allergen observed in our study as majority of our patients were cement workers and the second common allergen was paraphenylenediamine. Fissured pattern and unspecified pattern was noted more with potassium dichromate sensitivity. Two cases of atopic individuals showed positive patch test reactions. In our study 79% of patch test positivity had current relevance and 3% had old relevance and cross reaction noted with one allergen (3%). Fifteen percentage of doubtful relevance could be attributed to the common allergens which are present in various objects they handle in their day to day life or failure to recall the contact with the allergen containing substances. Patch testing is a very useful scientific diagnostic tool to identify the allergen responsible for

dermatitis. Patient can be advised to avoid the specific allergen or the alternative materials can be recommended.

Funding: No funding sources

Conflict of interest: None declared

Ethical approval: The study was approved by the institutional ethics committee

REFERENCES

1. Berth-Jones J. Eczema, lichenification, prurigo and erythroderma. In: Burns T, Breathnach S, Cox N, Griffiths C, editors. Textbook of Dermatology, 8 th ed. West Sussex: Wiley-Blackwell; 2010;23:13.
2. Kishore NB, Belliappa AD, Shetty NJ, Sukumar D, Ravi S. Hand eczema-clinical patterns and role of patch testing. Indian J Dermatol Venereol Leprol. 2005;71:207-8.
3. Laxmisha C, Kumar S, Nath AK, Thappa DM. Patch testing in hand eczema at a tertiary care centre. Indian J Dermatol Venereol Leprol. 2008;74:498-9.
4. Suman M, Reddy BS. Patterns of contact sensitivity in Indian patients with hand eczema. J Dermatol. 2003;30:649-54.
5. Handa S, Kaur I, Gupta T, Jindal M. Hand eczema: correlation of morphological patterns, atopy, contact sensitization and disease severity. Indian J Dermatol Venereol Leprol. 2009;75:136-41.
6. Pasricha JS. Contact dermatitis in India, General Features. The offsetters, New Delhi. 1988: 1-20.
7. Bhargava K, White IR, White JML. Thiuram patch test positivity 1980-2006: Incidence is now falling. Contact Dermatitis. 2009;60:222-3.
8. Sudhashree VP, Parasuramalu BG, Ranjana MS. A clinic-epidemiological study of allergens in patients with dermatitis. Indian J Dermatol Venereol Leprol. 2006;72:235-7.

Cite this article as: Sendurpandian D, Subashini MR. Relevance of patch testing and its correlation with clinical patterns of contact dermatitis of hand. Int J Res Dermatol 2019;5:498-504.