

Case Report

Acute methotrexate toxicity in psoriasis

Peram Karunakar*, Venkateswara Rao Garimella, Chinmai Yerram, Anusha Gogula

Department of Dermatology, Venereology and Leprosy, NRI Medical College and General Hospital, Chinakakani, Guntur, Andhra Pradesh, India

Received: 14 February 2019

Revised: 28 March 2019

Accepted: 02 April 2019

***Correspondence:**

Dr. Peram Karunakar,

E-mail: karunakarperam@gmail.com

Copyright: © the author(s), publisher and licensee Medip Academy. This is an open-access article distributed under the terms of the Creative Commons Attribution Non-Commercial License, which permits unrestricted non-commercial use, distribution, and reproduction in any medium, provided the original work is properly cited.

ABSTRACT

We describe two cases of low dose methotrexate (MTX) toxicity in patients with psoriasis. Patient was a 49-year-old male, known case of chronic plaque psoriasis from 10 years on and off. He was advised to take MTX 2.5 mg 2 days a week but patient took 2.5 mg twice daily (BD) for 6 continuous days following which he developed ulceration over psoriatic plaques and bone marrow suppression. MTX is safe and effective if adhered to standard treatment guidelines but inadvertent use may lead to its toxicity.

Keywords: Methotrexate, Psoriasis, Toxicity

INTRODUCTION

Methotrexate is a potential, toxic antimetabolite, anticancer drug which in low doses is effective and safe therapy for psoriasis if adhered to the recommended treatment guidelines. Acute MTX toxicity presents as pancytopenia, gastrointestinal (GI) mucositis, hepatotoxicity, pulmonary toxicity, acute renal failure.^{1,2} Here we describe a case of acute methotrexate toxicity who failed to adhere to the recommended guidelines.

CASE REPORT

A 49 year old male, known case of chronic plaque psoriasis from 10 years on and off, presented with ulceration of psoriatic plaques over forearms, elbows, abdomen, back and lower limbs since 5 days. He was advised to take T. MTX 2.5 mg 3 doses 12 hours apart per week but patient took 2.5 mg BD for 6 continuous days following which he developed ulceration over psoriatic plaques. Multiple erosions, ulcers seen over buccal mucosa, groins and scrotum. cutaneous

examination revealed multiple well defined ulcerated plaques seen over the anterior and posterior aspects of the trunk, right forearm, extensor aspect of both thighs and legs.

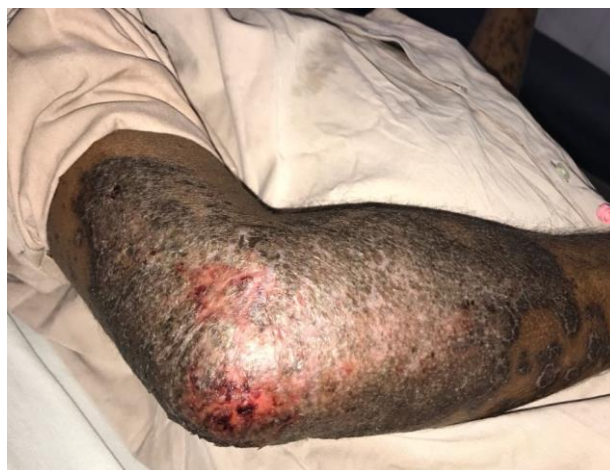

Figure 1: Ulcerated plaque over elbow.

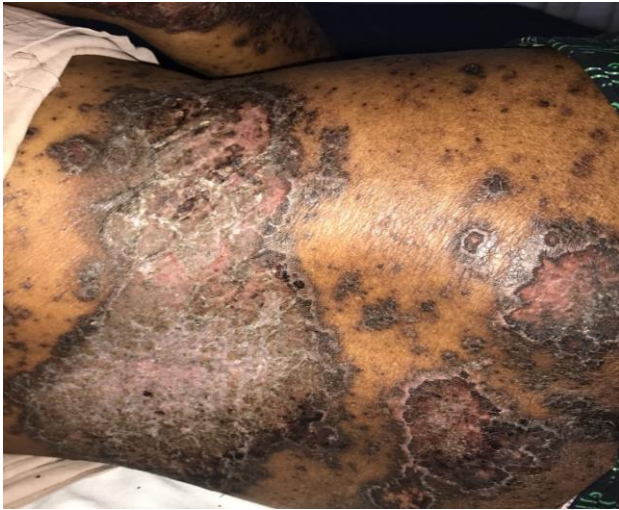

Figure 2: Multiple ulcerated plaques over the trunk.

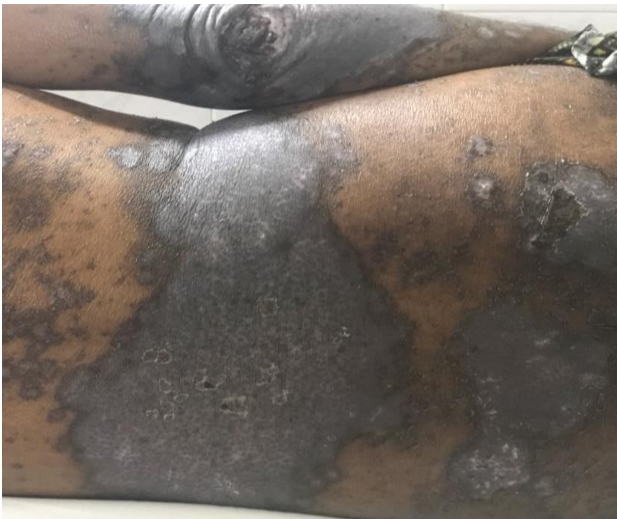

Figure 3: Healed lesions over the trunk.

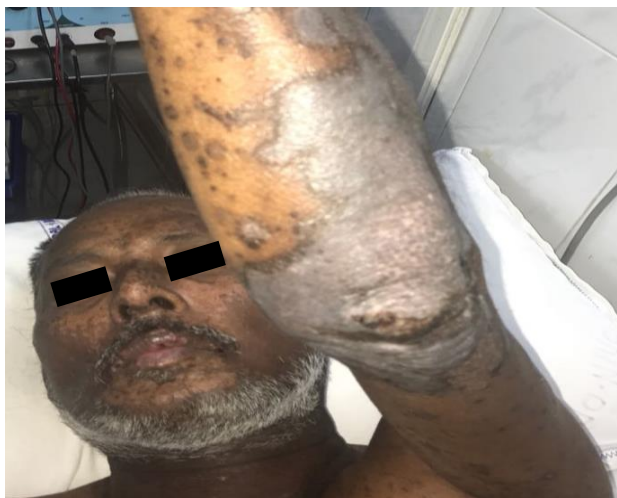

Figure 4: Healed lesions over the elbow.

Investigations revealed myelosuppression with Hb- 8.2 gm/dl, TC- 1200 cells/cu mm, platelet count- 0.60

lakhs/cumm, albumin- 2.1 gm/dl, urea - 63 mg /dl, Complete urine examination revealed plenty of pus cells. Based on the above clinical and laboratory findings, a diagnosis of Methotrexate toxicity was made. Patient was admitted in the hospital and was treated with IV fluids- 2 units NS and 1 unit of DNS @ 75 ml/hr, alkalization of urine with sodium bicarbonate (50 milliequivalents in 1 unit), Inj. Dexa 4 mg IV TID, Inj Pantop 40 mg OD, oral antibiotics were given.

Figure 1 and 2 shows ulcerated psoriatic plaques over the back of the trunk and forearm before treatment. Figure 3 and 4 were of after treatment.

DISCUSSION

Low dose MTX in psoriasis rarely produces toxicity, and most of such cases occur due to failure to adhere to the recommended guidelines.³ The risk of toxicity is greater if additional methotrexate is administered sooner than the usual scheduled weekly dose.⁴ In our case patient took 2.5 mg BD for 6 continuous days following which he developed ulceration over psoriatic plaques (Figure 1 and 2). Patient recovered on treatment with IV fluids, alkalinisation of urine and other supportive treatment (Figure 3 and 4) within 7-10 days. MTX toxicity has its impact on skin, gastrointestinal mucosa, liver, kidneys, and bone marrow. Ulcerations in skin due to MTX toxicity are restricted to the psoriatic plaques probably because of higher uptake of methotrexate by the hyperproliferative psoriatic plaques than normal skin.⁵ Methotrexate (4-amino-N¹⁰ methyl pteroylglutamic acid) is a potent competitive antagonist (inhibitor) of the enzyme dihydrofolate reductase. Inhibition of cell division, being specific for the S phase (DNA synthesis) of the normal cell cycle. Rapidly proliferating cells have a greater susceptibility to methotrexate because more cells are in the S phase, where methotrexate exerts its effect. Once absorbed, the level of MTX in the plasma has a triphasic reduction. First phase - occurs rapidly (0.75 h) and distribution of the drug occurs throughout the body. Second phase- plasma level reduction is represented by renal excretion and occurs over 2-4 hours. MTX is a weak organic acid excreted predominantly through the kidneys. Third phase- Terminal half-life varies between 10 and 27 hours. This phase is thought to reflect a slow release of MTX, primarily bound to dihydrofolate reductase, from the tissues. Approximately 50% of MTX is bound to plasma proteins, and the active portion of the drug is the free fraction (unbound) in the plasma. The drug is metabolized intracellularly, including by the liver, to polyglutamated forms. These metabolites, are also potent inhibitors of dihydrofolate reductase, are postulated to play a key role in MTX toxicity. The polyglutamated forms of MTX tend to be very persistent in various tissues.

Predisposing factors for developing MTX toxicity include acute renal failure, hypoalbuminemia, and concurrent use of drugs known to interact with MTX. Salicylates and

nonsteroidal anti-inflammatory drugs (NSAIDs) can decrease the renal elimination and the tubular secretion of MTX while trimethoprim/sulfamethoxazole (Septran®) can enhance the cytotoxic effects of MTX as trimethoprim is an antifolate reductase inhibitor.⁸ Concomitant use of MTX and NSAIDs, increase the risk of MTX toxicity as NSAIDs inhibits MTX clearance and displace MTX from protein binding sites.

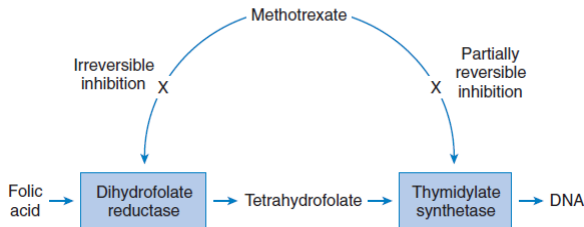


Figure 5: Methotrexate and folate metabolism.⁶

Table 1: Chronology of events in MTX toxicity.⁷

Acute toxicity	No of days after MTX use
Mucositis	3-5
Maculopapular rash	1-5
Hepatitis	1-10
Myelosuppression	7-10
Renal toxicity	1-3
Ocular irritation	1-3

Dermatological manifestations: Two patterns of skin ulceration in patients with psoriasis being treated with weekly methotrexate. Type I ulcers- wherein the psoriatic plaques eroded shortly after starting methotrexate. Type II ulcers- of the skin clinically not involved by psoriasis but affected by some other pathology such as scars. Mucositis: The mucosal cells are more sensitive to MTX than the precursor cells in the bone marrow because of greater accumulation and persistence of MTX in the intestinal epithelium. The presence of ulcerative stomatitis or severe diarrhea requires cessation of the MTX therapy. It has a rapid cell turnover time.

Hepatotoxicity: The potential for hepatotoxicity in a patient treated with long-term MTX is an important consideration. Alcohol intake and MTX is associated with an increased risk of hepatotoxicity. It can cause elevation of liver enzymes. Pulmonary toxicity: Pulmonary toxicity is idiosyncratic. MTX induced pneumonitis has infrequently been reported in psoriasis patients. Chest X-ray helps in diagnosis.

Treatment

Three broad targets are involved in managing acute MTX toxicity: folinic acid rescue, elimination of MTX from the body, organ specific care.

Folinic acid rescue: Folinic acid is antidote of choice for MTX toxicity. Serum MTX levels should be measured every 24 h until the levels fall below 0.2 µmol/l. The dose of IV folinic acid is adjusted as per MTX levels. Inj. Leucovorin calcium IV (15 mg/2 ml), 2 ml 6th hourly. Elimination of MTX from the body:

Hydration: Fluid input should be approximately 3 L/m²/day until MTX levels are 0.2 µmol/l or below to maintain urine output and facilitate MTX excretion. Aim for a urine output of approximately 2 l/m²/day until the MTX level has fallen to 0.2 µmol/l.

Alkalinization of urine: Urinary alkalinization with 40–50 mEq of sodium bicarbonate per liter of IV fluid reduces the risk of intratubular crystal formation. Urine pH must be >7 to promote MTX excretion and prevent MTX crystallization.

Managing delayed methotrexate excretion: Glucarpidase (carboxy-peptidase, CPDG2 enzyme) was approved by the US FDA for the treatment of increased plasma MTX concentrations (>1 µmol/l) in patients with delayed MTX clearance due to impaired kidney function.⁹

CONCLUSION

Improper dosage of methotrexate leads to toxicity as it has low therapeutic index. Therefore it is very important to ensure correct comprehension of prescription. Dispensing methotrexate in the weekly dosage pack communicating effectively with patients about unusual dosage regimens can reduce adverse effects. Clinicians should encourage feedback to ensure that the patient understands the weekly dosage schedule and that the medication should not be used “as needed” for symptom control.

Funding: No funding sources

Conflict of interest: None declared

Ethical approval: Not required

REFERENCES

- Bhatnagar A, Verma R, Vasudevan B, Saraswat N. Acute methotrexate toxicity presenting as ulcers in plaques of psoriasis vulgaris. Indian Dermatol Online J. 2015;6:232-3.
- Fridlington JL, Tripple JW, Reichenberg JS, Hall CS, Diven DG. Acute methotrexate toxicity seen as plaque psoriasis ulceration and necrosis: A diagnostic clue. Dermatol Online J. 2011;17:2.
- Roenigk HH, Jr., Maibach HI, Weinstein GD. Use of methotrexate in psoriasis. Arch Dermatol. 1972;105(3):363–5.
- Bleyer WA. Methotrexate: clinical pharmacology, current status and therapeutic guidelines. Cancer Treatment Rev. 1977;4(2):87–101.

5. Kaplan DL, Olsen EA. Erosion of psoriatic plaques after chronic methotrexate administration. *Int J Dermatol.* 1988;27(1):59–62.
6. Wolverton SE. Comprehensive dermatologic drug therapy. In: Callen JP, Kulp-Shorten CL, eds., 3rd edition; Roubush VA Medical Center, Indianapolis, IN, USA: Elsevier; 2013: 169-219.
7. Madke B, Singh AL. Acute methotrexate toxicity. *Indian J Drugs Dermatol.* 2015;1:46-9.
8. Bourré-Tessier J, Haraoui B. Methotrexate drug interactions in the treatment of rheumatoid arthritis: A systematic review. *J Rheumatol.* 2010;37:1416-21.
9. Rattu MA, Shah N, Lee JM, Pham AQ, Marzella N. Glucarpidase (Voraxaze), a carboxypeptidase enzyme for methotrexate toxicity. *Pharm Ther.* 2013;38:732-44.

Cite this article as: Karunakar P, Garimella VR, Yerram C, Gogula A. Acute methotrexate toxicity in psoriasis. *Int J Res Dermatol* 2019;5:652-5.