

## Original Research Article

# Combined treatment modalities in atrophic acne scars: a prospective study

Saravanan Narayanan, Kamalanathan Nallu\*, Sridhar Venu, Arul Raja Ganapathi

Department of Dermatology, Venereology and Leprosy, Chengalpattu Medical College and Hospital, Tamil Nadu, India

**Received:** 08 February 2019

**Accepted:** 25 February 2019

**\*Correspondence:**

Dr. Kamalanathan Nallu,

E-mail: [nkamalmd@gmail.com](mailto:nkamalmd@gmail.com)

**Copyright:** © the author(s), publisher and licensee Medip Academy. This is an open-access article distributed under the terms of the Creative Commons Attribution Non-Commercial License, which permits unrestricted non-commercial use, distribution, and reproduction in any medium, provided the original work is properly cited.

### ABSTRACT

**Background:** Atrophic acne scars are one of the sequelae that follows acne vulgaris. These scars are big cosmetic concern presenting with varied morphology like ice-pick, rolling and boxcar scars and it needs multimodal approach to treat effectively rather than a single modality. Our main aim is to study the efficacy of combination therapy using subcision, micro-needling and trichloro acetic acid chemical reconstruction of skin scars (TCA CROSS) in a sequential manner for the management of atrophic acne scars.

**Methods:** Total 30 patients of either sex with grade 2, 3, and 4 atrophic acne scars were graded using Goodman and Baron qualitative grading and were enrolled in the study. After single sitting of subcision, micro-needling and 50% TCA CROSS were performed alternatively at 3 weeks interval for a total of 3 sessions of each. Grading of acne scars were done by taking photographs at pre-treatment, post treatment, 1st and 3rd month after last treatment session.

**Results:** Out of 14 patients with grade 4 acne scars, 9 (64.3%) patients improved to grade 2 and 5 (35.7%) patients improved to Grade 3. Out of 10 patients with Grade 3 scars, 6 (60%) patients improved to grade 1, and 4 (40%) patients were improved to grade 2 at the end of study. All 5 patients with Grade 2 scars showed significant improvement from baseline.

**Conclusions:** Subcision, micro-needling and TCA CROSS, if they are combined and adequately done in proper manner will have excellent response in all types of atrophic acne scars.

**Keywords:** Subcision, Micro-needling, TCA CROSS, Goodman and Baron qualitative grading

### INTRODUCTION

Acne vulgaris is a disorder of the pilosebaceous unit, seen in adolescents and young adults. Acne sequelae can be life-long with atrophic, hypertrophic scar or keloid formation.<sup>1</sup>

Atrophic acne scars result from loss of tissue and classified into ice-pick, rolling and boxcar scars and are not amenable to medical treatment. Surgical and procedural options include punch excision, punch elevation, elliptical excision, subcision, dermabrasion, percutaneous collagen induction by micro-needling,

chemical peels. Newer treatment options include various ablative, non-ablative lasers and light energies. Treatment has to be individualised according to patients's needs, goals along with physicians assessment and skill.<sup>2,3</sup>

Subcision (Subcutaneous incision less surgery) - a minor surgical procedure described by Orentreich and Orentreich in 1995. It is performed by inserting tri-bevelled hypodermic needle subcutaneously under the depressed scars, thereby breaking the fibrotic strands which tether scar to the underlying sub cutis. It is mainly used in the treatment of rolling scars.<sup>4</sup>

Percutaneous collagen induction using dermapen remodels the skin by creating thousands of microscopic channels through the epidermis into papillary dermis. This artificial injury initiates the normal process of wound healing with release of several growth factors. This stimulates migration and proliferation of fibroblasts resulting in increase in collagen production.<sup>4-6</sup>

Chemical reconstruction of skin scars (CROSS)- consists of focal application of higher concentration of trichloroacetic acid even up to 100%, by pressing hard on the entire depressed area of atrophic acne scars using a sharpened wooden applicator. This technique has the advantage of reconstructing acne scars by focussing on the dermal thickening and collagen production. Repeated CROSS application can normalise deep rolling, boxcar scars and icepick scars.<sup>7-9</sup>

The purpose of our study was to evaluate the efficacy of combination therapy using subcision, dermapen and 50% TCA CROSS for the management of atrophic acne scars. The rationale for combining these three minimally invasive procedures was their additive action on various

types of acne scars by different mechanism. Subcision releases the scars from the underlying adhesions which should be the first step for any treatment for acne scars. Micro-needling with dermapen causes collagen induction. Fifty percent TCA CROSS acts by focussing on the dermal thickening, collagen production and improvement in skin texture. Hence by combining these three minimally invasive modalities one can release the scars, enhance collagen induction and resurface the skin.<sup>10</sup>

**METHODS**

Thirty patients with atrophic acne scar presenting to the outpatient department of dermatology, venereology, leprosy in a tertiary care centre were, enrolled for the study based on inclusion and exclusion criteria. It was a prospective study. The study period was from October 2017 to December 2018. Patients were explained about the procedure and written informed consent were obtained. Detailed history, clinical examination and pre-treatment photography were taken for all the patients. Acne scar grading was done using Goodman and Baron qualitative grading system.

**Table 1: Goodman and Baron grading system for acne scars.<sup>11,12</sup>**

Grade	Level of disease	Characteristics
1	Macular	Erythematous, hyper or hypo pigmented flat marks visible to patient or observer irrespective of distance
2	Mild	Mild atrophy or hypertrophy that may not be obvious at social distances of 50cm or greater and may be covered adequately by makeup or the normal shadow of shaved beard hair in males or normal body hair if extra facial
3	Moderate	Moderate atrophic or hypertrophic scarring that is obvious at social distances of 50 cm or greater and is not covered easily by make up or the normal shadow of shaved beard hair but is still able to be flattened by manual stretching of the skin
4	Severe	Severe atrophic or hypertrophic scarring that is obvious at social distances of 50 cm or greater that is not covered easily by makeup or shadow of shaved beard hair in males or body hair if extra facial and not able to flattened by manual stretching of skin

**Inclusion criteria**

Inclusion criteria were grade 2, 3 or 4 atrophic acne scars; patients in the age group of 18-39 years; no previous treatment for acne scars; patient willing to give consent for the treatment

**Exclusion criteria**

Exclusion criteria were active acne; pregnancy and lactation; active herpes labialis; patients on systemic retinoids; evidence or history of keloid scars; h/o coagulation disorders.

Patients were explained in detail about the prognosis and possible side effects of the treatment. Standardised digital photographs were taken pre-procedure and at each subsequent sitting. Patients were primed using topical

sunscreen with a minimum SPF of 30 for 2 weeks before procedure. Before procedure face was cleaned gently with saline and antibiotic solution and topical anaesthetic cream EMLA (eutectic mixture of lidocaine 2.5% and prilocaine 2.5%) was applied under occlusion for one hour.

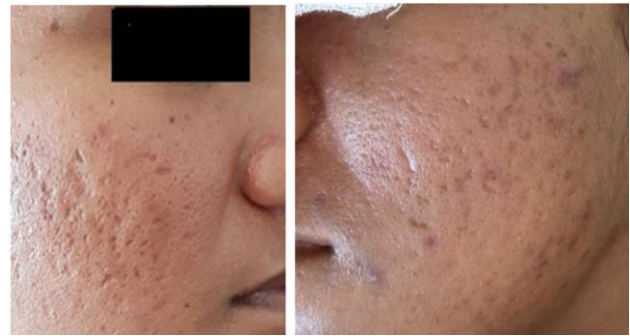At first visit, subcision was performed using 24G needle. Three weeks after subcision, patient was called for micro-needling using dermapen with 12 needles of needle diameter size 0.3 mm. Treatment was performed by gliding the dermapen over affected area until uniform pin point bleeding occurred. Then the area was covered with saline soaked gauze and washed after 5 minutes. Three weeks after micro-needling patient was called for 50% TCA CROSS. 50% TCA was applied on selected scar using sharpened wooden applicator. Appearance of speckled white frosting was taken as the end point of the

treatment. After using dermapen and 50% TCA CROSS, patients were instructed to use sunscreen regularly. Thereafter, dermapen and 50% TCA CROSS were repeated, alternatively after every 3 weeks for 3 sessions of each. Patients were followed up over a period of 3 months to note the improvement. Antibiotics were given when required. Any adverse effects after treatment were noted. Patient graded their response to treatment as poor, good, very good or excellent with 0-24%, 25-49%, 50-74% and 75-100% improvement respectively.

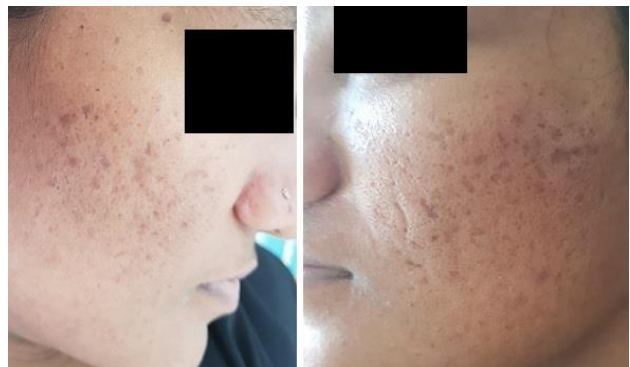**RESULTS**

A total of 30 patients were included in the study, 17 (56.6%) were male and 13 (43.4%) were female. Most of the patients (73%) were between 21-30 years of age, 17% were between 18-20 years of age and 10% patients were between 31-40 years of age. Out of 30 patients 29 completed the treatment. 14 patients had grade 4, 10 patients had grade 3 and 5 patients had grade 2 scars before treatment. The physician’s assessment of response to treatment based on Goodman and Baron qualitative scar grading is summarised in Table 2. In patients with Grade 4 scars, 9 patients (64.3%) showed improvement by 2 grades (Figure 1 and 2) and 5 patients (35.7%) showed improvement by 1 grade. In 10 patients with grade 3 scars, 6 patients (60%) showed improvement by 2 grades and 4 patients (40%) showed improvement by 1 grade. All 5 patients with grade 2 scars improved significantly. Hence all 29 patients showed improvement in their scars from baseline.

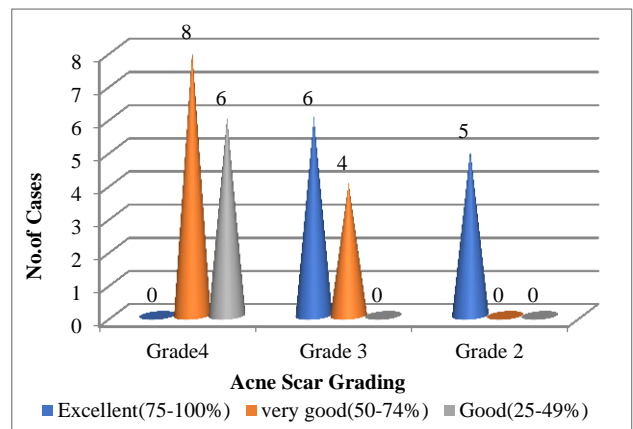
In patients with grade 4 scars, 8 patients (57.1%) graded their response to treatment as very good with 50-74% in their acne scars and 6 (42.9%) patients had good improvement in their acne scars with 25-49% improvement. In patients with grade 3 scars, 6 (60%) patients graded their response as excellent with 75-100% improvement in their scars and 4 patients (40%) reported the response as very good with improvement between 50-74%. All 5 patients (100%) patients with grade 2 scars graded their response to treatment as excellent with improvement between 75-100%. Poor response with 0-24% improvement was reported by none of the patients. There is a significant improvement in scar grading in all patients who underwent treatment.



**Figure 1: Grade 4 acne scar (before treatment).**



**Figure 2: Acne scars (after treatment).**



**Figure 3: Patient’s assessment of response to treatment.**

**Table 2: Physician’s assessment of response to treatment based on Goodman and Baron qualitative scar grading system.**

Pre-treatment grade of acne scars	No. of patients	Post-treatment reduction of scars by 3 grades	Post-treatment reduction of scars by 2 grades	Post-treatment reduction of scars by 1 grade
<b>Grade 4</b>	14	0 (0%)	9 (64.3%)	5 (35.7%)
<b>Grade3</b>	10	0 (0%)	6 (60%)	4 (40%)
<b>Grade2</b>	5	Not applicable	5 (100%)	0 (0%)

All three types of atrophic scars are amenable to treatment, by these in combined modalities. Side effects

following these procedures were mild, transient and usually self limiting. Following subcision, erythema and

edema lasted for 1-3 days and erythema following micro-needling lasted for 24-48 hours and resolved without dyspigmentation. Transient hyperpigmentation following TCA CROSS was present in 4 patients for 7-12 days. Only one patient developed intense edema following subcision, which warranted topical hydrocortisone cream and resolved after 7 days without dyspigmentation.

## DISCUSSION

Atrophic acne scars require multimodalities approach to address each type of scars. In our study we choose subcision, micro-needling and TCA CROSS, as subcision is very effective for rolling scars with fibrotic strands, micro-needling takes care of boxcar, superficial rolling scars and TCA CROSS works better for ice-pick scar with deep component in the dermis. In our study, 8 out of 14 patients with grade 4 scar were improved to grade 2 and 6 out of 10 patients with grade 3, were improved to have grade 1. This shows the efficacy of this combination in atrophic acne scars, which was shown in previous studies.<sup>13,14</sup> All the patients tolerated the procedure well with mild stinging and burning during TCA CROSS alone. Post- procedure complication is seen in only one patient followed subcision. Post inflammatory pigmentation following TCA CROSS was not significant in our study, owing to application of 50% concentration in our study.

## CONCLUSION

Hence these time tested procedures like Subcision, Micro-needling and TCA CROSS on combination are effective, safe, economic, with short downtime and fewer side effects for all grades of atrophic acne scars.

*Funding: No funding sources*

*Conflict of interest: None declared*

*Ethical approval: The study was approved by the institutional ethics committee*

## REFERENCES

1. Pandey SS. Epidemiology of acne vulgaris. Indian J Dermatol. 1983;3:109-10.
2. Rivera AE. Acne scarring: A review and current treatment modalities. J Am Acad Dermatol. 2008;59:659-76.

3. Khunger N. IADVL Task Force. Standard guidelines of care for acne surgery. Indian J Dermatol Venereol Leprol. 2008;74:28-36.
4. Orentreich DS, Orentreich N. Subcutaneous incisionless (subcision) surgery for the correction of depressed scars and wrinkles. Dermatol Surg. 1995;21:543-9.
5. Alam M, Han S, Pongprutthipan M, Disphanurat M, Kakar R, Nodzenski M, et al. Efficacy of a needling device for the treatment of acne scars. A randomized clinical trial. JAMA Dermatol. 2014;150:844-9.
6. Aust MC, Fernandes D, Kolokythas P, Kaplan HM, Vogt PM. Percutaneous collagen induction therapy. An alternative treatment for scars, wrinkles, and skin laxity. Plast Reconstr Surg. 2008;121:1421-9.
7. Fabbrocini G, Cassiapouti S, Fardella N, Pastore F, Monfrecola G. CROSS technique: chemical reconstruction of skin scars method. Dermatol Ther. 2008;21(3):529-3213.
8. Khunger N, Bhardwaj D. Evaluation of CROSS technique with 100% TCA in the management of ice pick scars in darker skin types. J Cosmet Dermatol. 2010;10:51-5714.
9. Lee JB, Chung WG, Kwahck H, Lee KH. Foal treatment of acne scars with trichloroacetic acid: Chemical reconstruction of skin scars method. Dermatol Surg. 2002;28:1017-21.
10. Goodman GJ, Baron JA. The management of postacne scarring. Dermatol Surg. 2007;33:1175-88.
11. Goodman GJ, Baron JA. Postacne scarring: A Qualitative global scarring grading system. Dermatol Surg. 2006;32:1458-66.
12. Jacob CI, Dover JS, Kaminer MS. Acne scarring : A classification system and review of treatment options. J Am Acad Dermatol. 2001;45:109-17.
13. Garg S, Baveja S. Combination therapy in the Management of of Atrophic Acne Scars. J Cutan Aesthet Surg. 2014;7(1):18-23.
14. Badheka AD, Mansuri UU, Solanki RB, A study of efficacy of subcision, micro-needling and carbon dioxide fractional laser for treatment of acne scars. Int J Res Med Sci. 2016;4:2623-9.

**Cite this article as:** Narayanan S, Nallu K, Venu S, Ganapathi AR. Combined treatment modalities in atrophic acne scars: a prospective study. Int J Res Dermatol 2019;5:243-6.