

Original Research Article

A mycological study of clinically normal nails and waistbands and their role as sources of infection in patients with tinea corporis

Asritha Reddy¹, Noyal Maria Joseph², Subuh Parvez Khan³, Shuaeb Bhat^{4*}

¹CC Shroff Memorial Hospital, Hyderabad, India

²Department of Microbiology, Mahatma Gandhi Medical College and Research Institute, Pondicherry, Tamil Nadu, India

³Department of Haematopathology, Sher E Kashmir Institute of Medical Sciences, Srinagar, Jammu and Kashmir, India

⁴Department of Pathology, Government Medical College, Anantnag, Jammu and Kashmir, India

Received: 21 December 2018

Accepted: 07 February 2019

*Correspondence:

Dr. Shuaeb Bhat,
E-mail: shuaeb4@gmail.com

Copyright: © the author(s), publisher and licensee Medip Academy. This is an open-access article distributed under the terms of the Creative Commons Attribution Non-Commercial License, which permits unrestricted non-commercial use, distribution, and reproduction in any medium, provided the original work is properly cited.

ABSTRACT

Background: Dermatophytosis is a superficial fungal infection of keratinized tissue caused by keratophilic fungi-dermatophytes. Inanimate objects and infected nails favour the spread of infection. Purpose of this study was to identify the role of waist bands and uninvolved nails as sources of infection in patients with tinea corporis.

Methods: A study was carried out on 50 patients with tinea corporis during the period of December 2010 to June 2012 at Tertiary Care Centre at Pondicherry. Nail clippings, waist band cuttings and scrapings were subjected to direct microscopy with 10% KOH and culture.

Results: Laboratory analysis showed positive culture in 18% of patients, of which dermatophytes were isolated from all three samples in 12% of patients, while in 6% of the patients growth was seen only in the skin scrapings and waist bands.

Conclusions: Waist bands and uninvolved nails harbour dermatophytes and play an active role in the spread and recurrence of infection.

Keywords: Dermatophytosis, Nails, Tinea corporis

INTRODUCTION

Dermatophytes are a group of keratophilic fungi which cause ringworm infection. There are three genera of dermatophytes, recognised by the nature of their macroconidiae (asexual spores):

- Trichophyton.
- Microsporum.
- Epidermophyton.

Spread of infection is through contact with infected person or fomites or animals.¹

Despite proper treatment some patients come back with recurrences. The causes for recurrence could be a common source of infection from close relative with dermatophyte infection at home, inanimate objects like towels and clothing or the patient himself if he has tinea unguium. Few studies have been done to implicate inanimate objects as sources of infection. Waist band is

believed to be a sacred thread which is worn around the waist region of children and adult males. Use of waistbands is a common practice in South India which is believed to ward off bad omens. However they are rarely seen as pockets that harbour microbes. Studies show that tinea unguium could be a source of infection in patients with tinea corporis, but whether uninvolved/clinically normal nails in patients with tinea corporis carry dermatophytes is not known. Hence this study was done to determine the role of waist bands and uninvolved nails as sources of infection in patients with tinea corporis.

Aims and objectives were (a) to determine if the dermatophytes responsible for skin infections could be isolated from clinically normal nails and waist bands of patients with tinea corporis and (b) to prove/disprove that waist band and uninvolved nails are sources of infection in tinea corporis.

METHODS

This was a descriptive study conducted in the department of dermatology, venereology and leprology at Mahatma Gandhi Medical College and Research Institute, a tertiary care teaching hospital in Pondicherry. This study was approved by the Institute Research and Ethical committee. All the patients with tinea corporis, both recurrent and newly diagnosed cases attending the department of DVL during the period of December 2010 to June 2012 were included in the study. Patients who had used topical or systemic antifungal preparation in the preceding 4 weeks, those who were on systemic steroids and other immunosuppressants and those with clinically involved nails were excluded from the study group. A detailed history was taken, general and dermatological examinations were done. Nail clippings, waist band cuttings and scrapings from the lesions were taken using a sterile blade. Skin specimen was collected by scraping across the inflamed margin of lesion into the apparently healthy tissue. Nail specimen was collected by taking clippings of the infected part and scrapings beneath the nail. The samples were put in three separate packs and sent to the department of Microbiology for mycological examination. This included both direct microscopy in 10% potassium hydroxide (KOH) and culture. The observations were made and tabulated and statistical analysis of the results was done.

RESULTS

A total of 50 patients with clinically suspected dermatophyte infection were involved in the study. Out of the 50 patients, the maximum were seen in the age group of 21-40 (44%) followed by the age group of less than 20 (32%) (Table 1). Among them 48 patients were males while only 2 patients were females (Table 2). Laboratory analysis of the clinical samples showed positive direct microscopy in 52% of patients (Figure 1) and positive culture in 18%, while 1 case was negative by KOH but yielded growth on culture (Table 3). In 12% of

the patients dermatophytes grew in all three samples (uninvolved nail clippings, waist band and scrapings from the lesions), while in 3 (6%) patients growth was seen only in the skin scrapings and waist band (Table 4, 5, 6). Tinea corporis was the most frequent clinical type (46%) followed by concurrent tinea corporis and tinea cruris (36%), while 18% had tinea cruris alone (Table 7). The following species were seen on culture-*Trichophyton schoenleinii* (Figure 2), *T. Equinum* (Figure 3), *Microsporum nanum* (Figure 4), *T. mentagrophytes*, *T. verrucosum*.

Table 1: Distribution of patients based on age.

Age (in years)	Number of patients	%
Below 20	16	32
21-40	22	44
41-60	9	18
61-80	3	6

Table 2: Distribution of patients based on gender.

Sex of patient	Number of patients	%
Male	48	96
Female	2	4

Table 3: KOH positivity of skin scraping.

KOH mount	Number of Patients	%
Positive	26	52
Negative	24	48

Table 4: Culture results of skin scraping.

Skin scraping culture	Number of patients	%
Positive	9	18
Negative	41	82

Table 5: Culture of nail clippings.

Nail clippings culture	Number of patients	%
Positive	6	12
Negative	44	88

Table 6: Culture results of waist band cuttings.

Waist band cuttings culture	Number of patients	%
Positive	9	18
Negative	41	82

Table 7: Concurrent fungal infection with tinea cruris or tinea corporis.

Dermatophyte infection	Number of patients	%
T. corporis alone	23	46
T. cruris alone	9	18
T. corporis and T. cruris	18	36

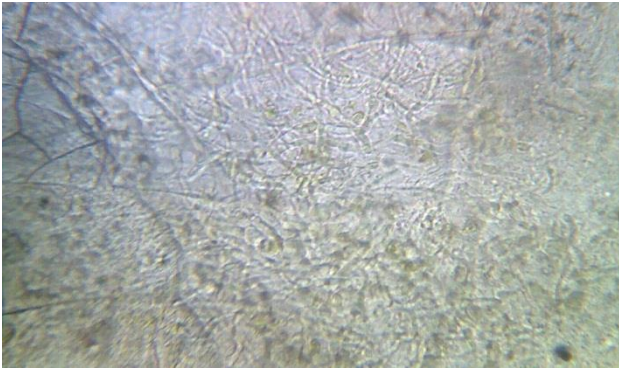


Figure 1: Dermatophytes in KOH mount.

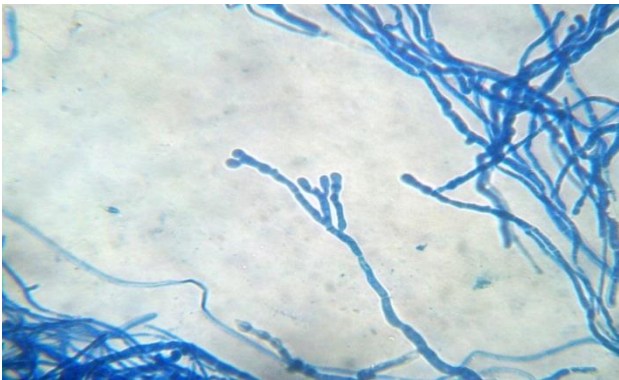


Figure 2: Trichophyton schoenleinii-antelar hyphae.

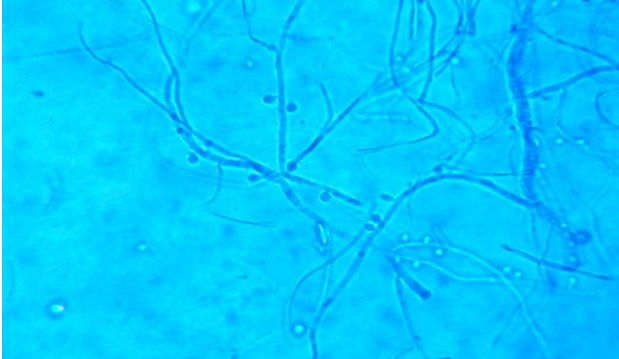


Figure 3: Trichophyton equinum.

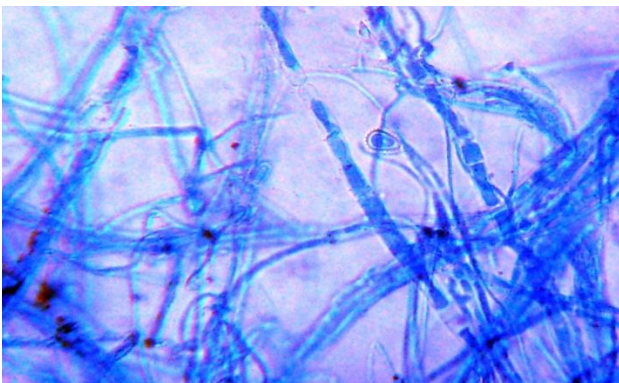


Figure 4: Microsporium nanum.

DISCUSSION

In our study the maximum numbers of patients were seen in the third and fourth decade in the age group of 21- 40 years. Similar findings have been reported in a study conducted by Kamothi where 39% of the patients were seen in the age group of 21-30 years.² The reason for higher prevalence of ringworm infections in this age group could be due to greater physical activity and increase sweating.

The number of male patients outnumbered the female patients in our study. Similarly Hassan et al in his study observed a male preponderance of dermatophyte infection, with a male:female ratio of 2:1.³ Another study carried out Kumar et al found that the percentage of males affected with ringworm infections was only marginally higher than females.⁴ However in our study the reason for male preponderance is that, waist bands were commonly worn by the males.

In our study samples from clinically suspected cases showed positive direct microscopy by 52% and positive culture by 18%. Study conducted by Pakshir et al yielded similar results, in which the culture positivity was 23.2% and KOH positivity was 25.5%.⁵

The present study confirms that waist bands are a source of infection in patients with dermatophyte infection. Of the 50 collected waist band clippings 18% were positive for the growth of dermatophyte colonies. We could not isolate dermatophytes in majority of the samples though the patients clinically had typical features of ringworm infection and we observed improvement in the lesions with treatment during follow up of the patients. The reason for the low percentage of culture isolation of dermatophytes could be the low sensitivity of the culture media used by us. Levitt et al carried out a pooled analysis in which they found that sensitivities for KOH smear and culture was 73.3% and 41.7% respectively.⁶ Nweze in his study noticed, that there was a difference between the number of positive samples by microscopy and the actual number of isolates recovered by culture in his study.⁷ He attributed it to the non-viability of arthroconidia and hyphae which are recognised microscopically. Waist band is constantly worn by the patients throughout the day. They are not changed for months together. Following a bath patients tend to put on clothes even before the waist band dries up. The moisture in the waist band along with sweat will favour the growth of dermatophytes. In addition wearing of tight pants makes the area more occluded and less aerated. All these factors make this site more prone for infection. In our study we found that tinea corporis was the commonest clinical type accounting for 46% of the cases, followed by concurrent infection with tinea corporis and tinea cruris in 36% of patients. Concurrent infection of tinea cruris or tinea corporis with other dermatophytosis was noted in 42.2% of the cases by Kim et al at a Korean Institute.⁸ In majority of our patients with tinea corporis

we observed that waist was the commonest site involved. The lesions were arranged in a band like pattern around the waist and the band was in contact with the lesions. In this study we also found that clinically normal nails carry dermatophytes in patients with ring worm infection. The percentage of culture positivity of uninvolved nails in our study was 12%.

It is a known and proved fact that tinea unguium is a source of infection and recurrence in patients with tinea corporis. The high vulnerability of the crural region for sweat retention causes pruritis, therefore reflex scratching of the crural region with tinea unguium can cause autoinoculation. Similarly, tinea corporis might be acquired by patients with tinea unguium due to scratching.⁸ Alteras et al in his study reported that 85% of the patients with tinea faciei also had nail involvement.⁹ If infected nails could transmit infection to the skin, so could infected skin do to nails. Since dermatophytosis is a symptomatic disease and has scales, scratching of the lesions could result in deposition of scales in the subungual region. Over a period, if the patient leaves it unattended, it would result in tinea unguium. The following species were seen on culture in our study- *Trichophyton schoenleinii*, *T. equinum*, *Microsporum nanum*, *T. mentagrophytes*, *T. verrucosum* and *T. audonii*. Surprisingly in our study we isolated the same organisms from the skin scrapings, waist band cutting and nail clippings of each patient with positive culture except in one patient where the nail clipping grew different organism. Similarly Kim et al in their study cultured fungi from each lesion of the patients with concurrent infections of tinea cruris and/or tinea corporis with other dermatophytoses and obtained the same causative organisms in all lesions of each patient.⁸

CONCLUSION

Waist bands harbor dermatophytes and play an active role in the spread and recurrence of dermatophyte infections. Hence patients who present with dermatophytic infections, either for the first time or recurrently should be asked if a waist band is worn by them and if present should be asked to remove till treatment is complete. Also, in patients with dermatophyte infections clinically normal looking nails may harbor the microbes. Though the nails look normal, they may be in a stage of subclinical infection, where they appear normal but still carry the causative organisms. Hence the treatment for dermatophyte infections may be prolonged for another

week or two. This may be more applicable in patients with recurrent and chronic infection.

Funding: No funding sources

Conflict of interest: None declared

Ethical approval: The study was approved by the institutional ethics committee

REFERENCES

1. Hay RJ, Moore MK. Burns T, Breathnach S, Cox N, Griffiths C. Rook's textbook of Dermatology, vol. 2. 7th ed. Massachusetts: Blackwell Publishers; 2004: 31.19-31.27.
2. Kamothi MN. Prevalence of dermatophyte infection in district Rajkot. Electronic j pharmacol therapy. 2010;3:1-3.
3. Hassan AS, Moses OE. Distribution and Microbiological characterization of dermatophytes infection among primary school children in Ago Iwoye, Ogun state, Nigeria. Researcher. 2010;2(6):95-9.
4. Kumar K, Kindo AJ, Kalyani J, Anandan S. clinic-Mycological profile of dermatophytic skin infections in tertiary care center- A cross sectional study. Sri Ramachandra J Medicine. 2007;1:12-5.
5. Pakshir K, Hashemi J. Dermatophytosis in Karaj, Indian J Dermatol. 2006;51:262-4.
6. Levitt JO, Levitt BH, Akshavan A, Yanofsky H. The Sensitivity and Specificity of Potassium Hydroxide Smear and Fungal Culture Relative to Clinical Assessment in the Evaluation of Tinea Pedis: A Pooled Analysis. Dermatol Res Practice. 2010;2010:1-8.
7. Nweke EI. Dermatophytosis among children of Fulani/Hausa herdsmen living in southeastern Nigeria. RevIberoam Micol. 2010;27(4):191- 4.
8. Kim YP, Lee HH. Studies on dermatophytes infection. Kor J Dermatol. 1979;17:57-64.
9. Alteras I, Sandbank M, David M, Segal R. 15-year survey of tinea faciei in the adult. Dermatologica. 1988;177(2):65-9.

Cite this article as: Reddy A, Joseph NM, Khan SP, Bhat S. A mycological study of clinically normal nails and waistbands and their role as sources of infection in patients with tinea corporis. Int J Res Dermatol 2019;5:239-42.