

Original Research Article

A clinical study of various cutaneous manifestations in neonates

Shams Zia Usmani¹, Kshitij Saxena^{1*}, Venkatarao Koti¹, Shrish Bhatnagar²,
Gaurav Paliwal¹, Shivani Yadav¹, Anukriti Singh¹

¹Department of Dermatology, Venereology and Leprosy, ²Department of Pediatrics, Era's Lucknow Medical College and Hospital, Lucknow, Uttar Pradesh, India

Received: 10 December 2018

Revised: 25 December 2018

Accepted: 26 December 2018

***Correspondence:**

Dr. Kshitij Saxena,

E-mail: drkshitijsaxena@live.com

Copyright: © the author(s), publisher and licensee Medip Academy. This is an open-access article distributed under the terms of the Creative Commons Attribution Non-Commercial License, which permits unrestricted non-commercial use, distribution, and reproduction in any medium, provided the original work is properly cited.

ABSTRACT

Background: Cutaneous manifestations are common in neonates. Transient and pathological neonatal dermatoses should be differentiated to avoid unnecessary treatment and thus considering the variable nature and severity of neonatal skin lesions, it is important to be aware of the transient skin lesions in newborn and to differentiate these from other serious conditions which will avoid unnecessary therapy to the neonates and the parents can be assured of good prognosis of these skin manifestations. The present study has been carried out to study the clinical pattern of cutaneous lesion in neonatal period.

Methods: A total of 255 neonates from Department of Dermatology in collaboration of Department of Pediatrics, Era's Lucknow Medical College and Hospital were evaluated for cutaneous manifestations. A detailed assessment regarding history, clinical examination and investigations were recorded and analyzed.

Results: Out of 255 neonates, 138 (54.1%) were males and 117 (45.9%) were females. The sex ratio (M:F) was 1.18. The most common dermatoses were physiological desquamation (54.1%) and mongolian spots (37.6%) followed by milia (19.6%), miliaria (14%), epstein pearls (10.2%).

Conclusions: The physiological and transient cutaneous lesions are common are in neonates. Physiological cutaneous manifestations were quite frequent apart from birthmarks/congenital cutaneous manifestations. An understanding of these manifestations helps in managing and deciding the appropriate manifestation.

Keywords: Neonate, Cutaneous lesions, Mongolian spot, Miliaria, Birthmark

INTRODUCTION

World Health Organization defines a baby from the time of birth to 28th day of extrauterine life as a "neonate".¹ It is a period that experiences a sudden transition from the intrauterine life to the external environment.²

Neonatal skin provides physical protection and assists in fluid balance, immunosurveillance, and thermoregulation; thus, playing a vital role in the newborn's transition from an aqueous to an air-dominant environment.³

The skin of a newborn differs from that of an adult in many ways: there is a higher skin surface area to weight ratio; less strong connection between the dermis and the epidermis; thinner and less elastic skin; higher permeability of the stratum corneum; not well developed epidermal barrier; dense but less active sweat glands and the higher pH of the skin surface.^{4,5}

A newborn's skin may exhibit a variety of changes during the first four weeks of life. Most of the skin disorders in neonates are transient such as benign lesions, pustular and vesicular infections and limited to the first days or

weeks of life. However, there are other conditions having long-term impact viz. "birthmarks" (vascular and various other skin conditions).³

Dermatoses are quite frequent in a neonate and incidence may vary from 96% to 99.3% of all newborn babies, and the range may vary from benign diseases to life-threatening ones.^{6,7} A number of factors are responsible for the high incidence of the dermatoses in the newborn. Heredity, race, gestational age, maternal health, hygiene, socioeconomic status, climate, customs and mode of delivery are also responsible for cutaneous changes in the skin of the new born.⁸

The dermatoses of the newborn can be classified as "Transient skin disorders, Congenital disorders, Acquired skin disorders specific to the neonatal period and Iatrogenic dermatologic complications".⁹

METHODS

A cross sectional, observational study on cutaneous manifestations presenting in neonates was conducted between November 2016 to May 2018 in the Department of Dermatology in collaboration with Department of Pediatrics, Era's Lucknow Medical College and Hospital (ELMC&H), Lucknow. After obtaining permission from Institutional Ethics Committee a total of 604 consecutive neonates were examined out of which 255 neonates had cutaneous manifestations.

Parents of all the neonates were invited to participate in the assessment. Non-consenting parents were excluded. Details regarding neonatal age, sex, gestational age at birth, were noted. Following this all neonates were thoroughly examined in broad day light and relevant clinical details regarding morphology, distribution, colour and configuration of lesions noted.

A provisional clinical diagnosis was proposed which was confirmed by relevant investigation wherever indicated like Gram staining, KOH smear and Tzanck smear. Neonates in whom diagnosis of transient skin lesions was made were subsequently followed up to confirm the transient nature of the lesions.

Classification of neonatal dermatoses was done in four groups:

- Transient skin disorders.
- Congenital disorders.
- Acquired skin disorders specific to the neonatal period (infection).
- Iatrogenic dermatologic complications.

The data was collected on a semi-structured questionnaire. Photographic records of all the cases were maintained. The data so collected was fed into computer using MS Excel 2013. The data was represented in

frequency and percentage terms using Statistical Package for Social Sciences version 21.0.

RESULTS

A total of 604 neonates were examined out of which 255 neonates had cutaneous manifestations. In 255 neonates, 138 (54.1%) were males and 117 (45.9%) were females (Figure 1). Among different types of cutaneous manifestations physiological cutaneous lesions were most commonly seen in 176 (69%) cases followed by birthmarks/congenital in 101 (39.6%), transient non-infective lesions in 66 (25.9%), eczematous eruptions in 17 (6.7%) and infectious lesions in 2 (0.8%) cases (Table 1) (Figure 2 and 3).

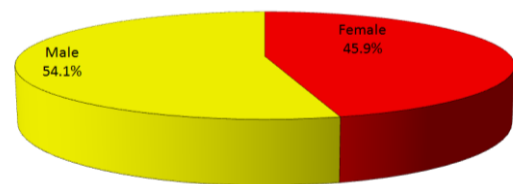


Figure 1: Pie diagram showing distribution of neonates according to gender.

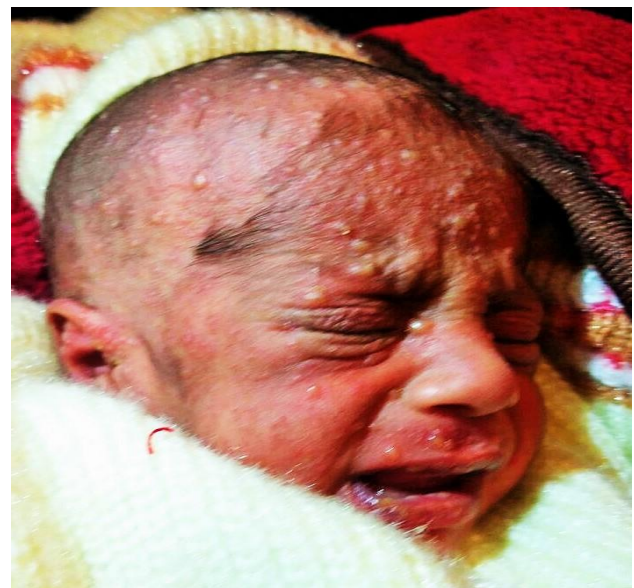

Figure 2: Neonatal herpes.

The birthmarks/congenital cutaneous manifestations included 96 (37.6%) cases with Mongolian spot, 4 (1.6%) cases with strawberry hemangioma and 2 (0.8%) cases with aplasia cutis (Figure 4 and 5).

Among physiological cutaneous manifestations, most common was physiological desquamation (peeling) (n=138; 54.1%) followed by milia (n=50; 19.6%), Epstein pearls (n=26; 10.2%), hypertrichosis lanugosa (n=13; 5.1%) and cutis marmorata (n=3; 1.2%) respectively (Figure 6).

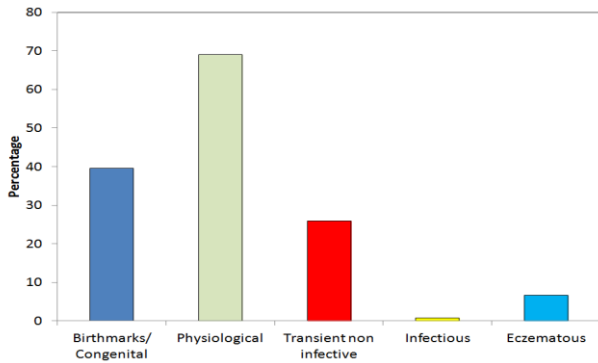


Figure 3: Pattern of various skin disorders.

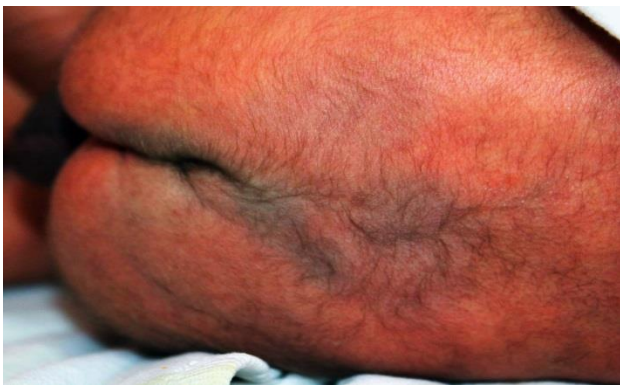

Figure 4: Mongolian spot with lanugo hairs.

Table 1: Pattern of various skin disorders.

SN	Variables	No. of patients	%
1.	Birthmarks/congenital	101	39.6
	Mongolian spot	96	37.6
	Strawberry hemangioma	4	1.6
	Aplasia cutis	2	0.8
2.	Physiological cutaneous lesions/changes	176	69.0
	Milia	50	19.6
	Epstein pearls	26	10.2
	Physiological desquamation (peeling)	138	54.1
	Hypertrichosis lanugosa	13	5.1
	Cutis marmorata	3	1.2
3.	Transient noninfective lesions	66	25.9
	Erythema toxicum neonatorum	21	8.2
	Neonatal acne	5	2.0
	Miliaria	43	16.9
4.	Infectious lesions	2	0.8
	Neonatal herpes	1	0.4
	Neonatal candidiasis	1	0.4
5.	Eczematous eruptions	17	6.7
	Nappy rash	10	3.9
	Cradle cap	7	2.7

*Multiple conditions possible.

Among transient non-infective lesions; miliaria (n=43; 16.9%) was most common followed by erythema toxicum neonatorum (n=21; 8.2%) and neonatal acne (n=5; 2%) respectively (Figure 7). There were only 2 cases with infectious lesions – 1 each of neonatal herpes and neonatal candidiasis. Among eczematous eruptions, nappy rash (n=10; 3.9%) was more common than cradle cap (n=7; 2.7%) (Figure 8).

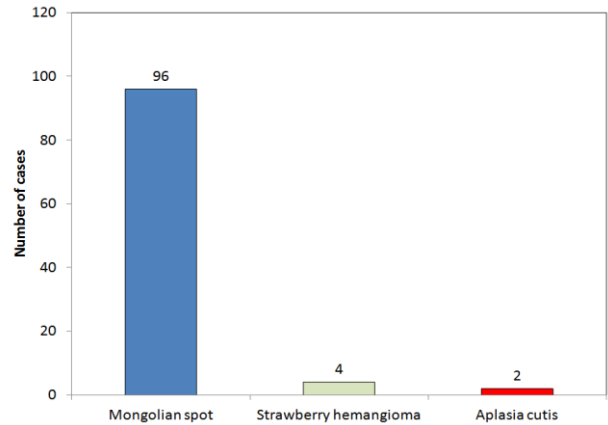


Figure 5: Different birthmarks/congenital cutaneous manifestations in study population.

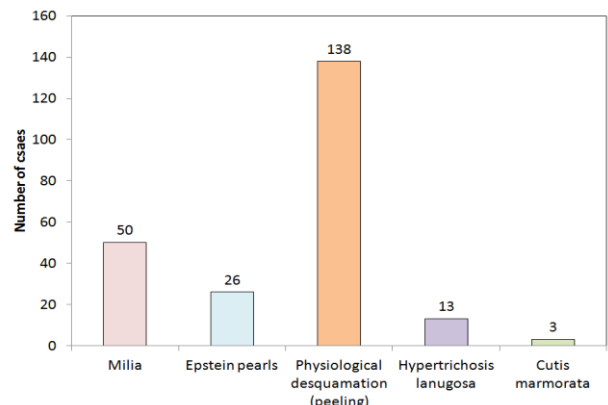


Figure 6: Different physiological cutaneous manifestations in study population.

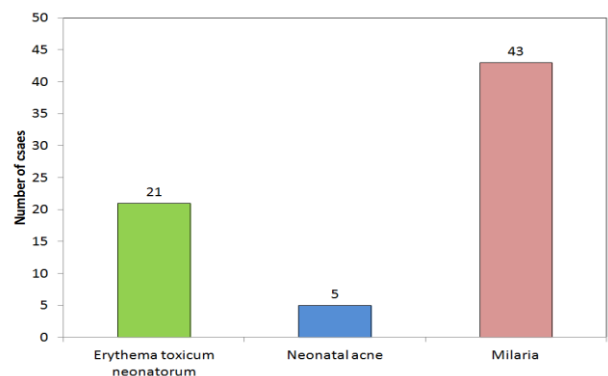


Figure 7: Different transient non-infective lesions in study population.

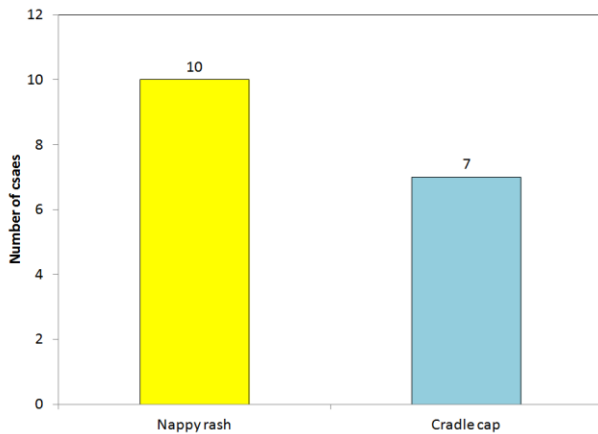


Figure 8: Different eczematous eruptions in study population.

DISCUSSION

The neonatal period constitute the first 4 weeks of extra-uterine life. A total of 255 newborns aged <28 days were enrolled in the study. Majority of them were males (54.1%). The sex ratio (M:F) was 1.18. This is similar to sex ratio of Lucknow population, which stands at 1.18.

Among these, majority of cases were aged <7 days (69.8%), and preterm babies were 79.6%. Similar to present study, Jain et al. who also included newborns <28 days of age, reported 79% of their study population to be aged <5 days, however, the proportion of preterm newborns was 26% in their study.¹⁰ This underlines the fact that with increasing proportion of term neonates without complication, the proportion of those with age >7 days shows a considerable decline. In present study, we have assessed birthmarks/congenital cutaneous manifestations, physiological cutaneous manifestations, transient non-infectious cutaneous manifestations, infectious lesions and eczematous eruptions. Overall incidence of different cutaneous manifestations was 95.3%. Incidence of different cutaneous manifestations has shown a considerable variability in different studies dependent upon the criteria of assessment, inclusion criteria and exposure to different risk factors. However, most of the studies have reported it to be above 90%, viz. Ferahbas et al (95.7%), Sachdeva et al (94.8%), Ahsan et al (94%), Agarwal et al (95.2%), Sandeep et al (96.1%) and Asha et al (92.1%). Although, some studies have reported a much lower incidence, viz. El-Moneim et al who reported skin disorders in only 40% newborns.¹¹⁻¹⁷ However, it could be owing to a stricter inclusion criteria with inclusion of cases within 4 days of birth, thus lowering the incidence of cutaneous manifestations owing to environmental exposure.

Javed too in their study reported this incidence as 34.75%, however, they did not specify the inclusion criteria. Shehab et al also reported this incidence as 74.6% but they also included the newborns up to first 7 days of birth.^{18,19} These findings in turn show that early

assessment might influence the incidence of cutaneous manifestations owing to a probable lack of environmental and other risk factor exposure.

In present study, among different types of cutaneous manifestations physiological cutaneous lesions were most common seen in 176 (69%) cases followed by birthmarks/congenital in 101 (39.6%), transient non-infective lesions in 66 (25.9%), eczematous eruptions in 17 (6.7%) and infectious lesions in 2 (0.8%) cases. With respect to independent manifestations, physiological desquamation/peeling was most common (54.1%) followed by mongolian spot (37.6%), milia (19.6%), miliaria (16.9%) and epstein pearls (10.2%) were most common manifestations affecting 10% or above of the studied newborns.

CONCLUSION

The findings of present study show that newborn cutaneous manifestations have a diversified manifestation. In our settings, physiological cutaneous manifestations were quite frequent apart from birthmarks/congenital cutaneous manifestations. An understanding of these manifestations helps in managing and deciding the appropriate manifestation. The present study did not find a high burden of infectious or malignant cutaneous manifestations.

Funding: No funding sources

Conflict of interest: None declared

Ethical approval: The study was approved by the institutional ethics committee, Era's University

REFERENCES

1. World Health Organization: Manual of the International Statistical Classification of Diseases, Injuries and Causes of Death. Sixth Revision, Adopted 1948.
2. Sarkar R, Basu S, Agarwal RK, Gupta P. Skin Care for the Newborn. *Indian Pediatr.* 2010;47:593-8.
3. Conlon JD, Drolet BA. Skin lesions in the neonate. *Pediatr Clin North Am.* 2004;51(4):863-88.
4. Sarkar R. Care of the skin In:Gupta P, editor. *Essential Pediatric Nursing.* New Delhi: CBS Publishers and Distributors; 2007: 217-226.
5. Ramasastry P, Downing DT, Pochi PE, Strauss JS. Chemical composition of human skin surface lipids from birth to puberty. *J Invest Dermatol.* 1970;50:139-44.
6. Moosavi Z, Hosseini T. One year survey of cutaneous lesions in 1000 consecutive Iranian newborns. *Pediatr Dermatol.* 2006;23:61-3.
7. Rivers JK, Frederiksen PC, Dibdin C. A prevalence survey of dermatoses in the Australian neonate. *J Am Acad Dermatol.* 1990;23:77-81.
8. Nobby B, Chakrabarty N. Cutaneous manifestations in the new born. *Indian J Dermatol Venereol Leprol.* 1992;58:69-72.

9. Parikh DA. Neonatal skin disorders. In: Valia RG, Valia AR editors. IADVL textbook of dermatology. 3rd ed. Bombay: Bhalani Publishing House; 2001: 160-170.
10. Jain N, Rathore BS, Krishna A. Dermatoses in Indian neonates: A clinical study. *Egypt J Dermatol Venerol.* 2014;34:86-92.
11. Ferahbas A, Utas S, Akcakus M, Gunes T, Mistik S. Prevalence of cutaneous findings in hospitalized neonates: A prospective observational study. *Pediatr Dermatol.* 2009;26:139-42.
12. Sachdeva M, Kaur S, Nagpal M, Dewan S P. Cutaneous lesions in new born. *Indian J Dermatol Venereol Leprol.* 2002;68:334-7.
13. Ahsan U, Zaman T, Rashid T, Jahangir M. Cutaneous manifestations in 1000 Pakistani newborns. *J Pakistan Assoc Dermatol.* 2010;20:199-205.
14. Agarwal G, Kumar V, Ahmad S, Goel K, Goel P, Prakash A, et al. A Study on Neonatal Dermatitis in a Tertiary Care Hospital of Western Uttar Pradesh India. *J Community Med Health Educ.* 2012;2:169.
15. Sandeep B, Susheela C, Keerthi S. Cutaneous Lesions in Newborn Babies: A Hospital-based Study. *Int J Sci Study.* 2016;4(5):43-9.
16. Asha GS, Shilpa VK, Ramesh M, Revathi TN. Clinical Study on Prevalence of Cutaneous Lesions in New Born Babies in India. *J Clin Exp Dermatol Res.* 2016;7:370.
17. El-Moneim AA, El-Dawela RE. Survey of skin disorders in newborns: clinical observation in an Egyptian medical centre nursery. *Eastern Mediterranean Health J.* 2012;18(1):49-55.
18. Javed M. Clinical spectrum of neonatal skin disorders at Hamdard University Hospital Karachi, Pakistan. *Our Dermatol Online.* 2012;3:178-80.
19. Shehab MM, Youssef DM, Khalil MM. Prevalence of cutaneous skin lesions in neonatal intensive care unit: A single center study. *J Clin Neonatol.* 2015;4:169-72.

Cite this article as: Usmani SZ, Saxena K, Koti V, Bhatnagar S, Paliwal G, Yadav S, Singh A. A clinical study of various cutaneous manifestations in neonates. *Int J Res Dermatol* 2019;5:8-12.