

## Case Report

# Discoid lupus erythematosus in acro-orificial vitiligo

Yogesh Devaraj\*, Belagola Dasegowda Sathyanarayana, Mukunda Ranga Swaroop,  
Sowmya Shree H., Mithila Ravindranath, Avik Ghosh

Department of Dermatology, Adichunchanagiri Institute of Medical Sciences, Mandya, Karnataka, India

**Received:** 30 May 2018

**Revised:** 06 July 2018

**Accepted:** 09 July 2018

### \*Correspondence:

Dr. Yogesh Devaraj,

E-mail: [yogeshdevaraj86@gmail.com](mailto:yogeshdevaraj86@gmail.com)

**Copyright:** © the author(s), publisher and licensee Medip Academy. This is an open-access article distributed under the terms of the Creative Commons Attribution Non-Commercial License, which permits unrestricted non-commercial use, distribution, and reproduction in any medium, provided the original work is properly cited.

## ABSTRACT

Discoid lupus erythematosus (DLE) is an autoimmune disease characterized by atrophic and discoid plaques over sun-exposed areas of skin and is the most common form of chronic cutaneous lupus erythematosus. Vitiligo is also an autoimmune disease known to be associated with other autoimmune conditions. However coexistence of DLE and vitiligo has been reported uncommonly. We report a case of a 60-year-old lady who developed DLE lesions over pre-existing vitiligo lesions.

**Keywords:** Discoid lupus erythematosus, Vitiligo, Autoimmune, Co-existence

## INTRODUCTION

Discoid lupus erythematosus (DLE) is an autoimmune disease characterized by atrophic and discoid plaques over sun-exposed areas of skin and is the most common form of chronic cutaneous lupus erythematosus. Vitiligo is an autoimmune disease resulting from progressive loss of melanocytes presenting as depigmented or achromic milky white sharply demarcated macules often associated with leukotrichia.<sup>1</sup> Vitiligo being an autoimmune disease, is known to be associated with other autoimmune conditions such as thyroid disease, diabetes mellitus, and alopecia areata.<sup>2</sup> However coexistence of DLE and vitiligo has been reported uncommonly. We report a case of a 60-year-old lady who developed DLE lesions over pre-existing vitiligo lesions.

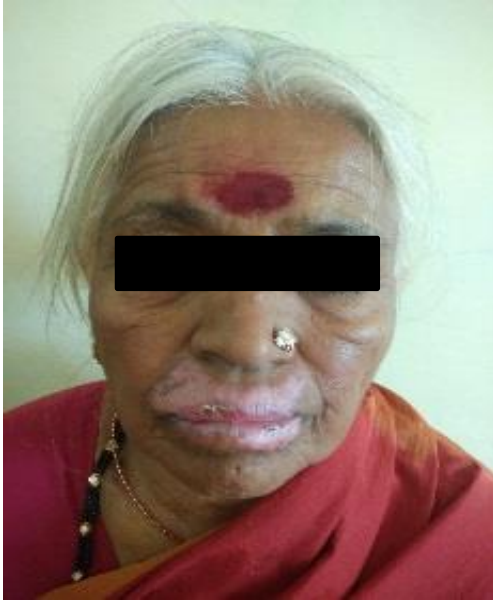## CASE REPORT

A 60-year-old lady presented with white lesions on legs, which started two years ago and then progressed gradually to involve both the palms, soles, nipple, areola, lips and peri-oral areas over a period of one year. Six

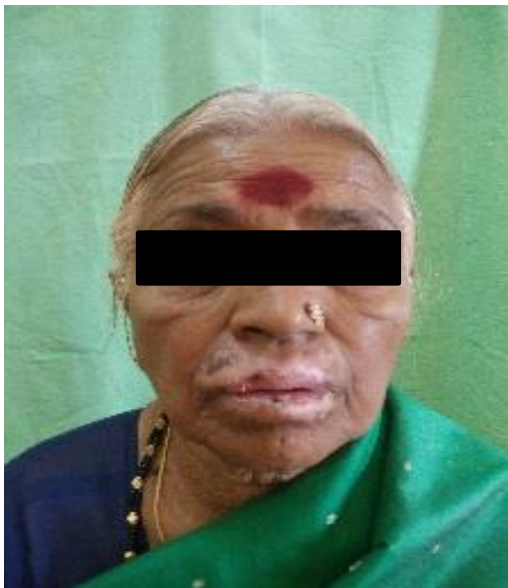month ago, patient developed raised scaly lesions over the vertex of scalp and on the whitish patch around the mouth. Patient subsequently developed scaling on the lips and erosions in the oral cavity. Lesions on the scalp and perioral region were associated with burning sensation on exposure to sunlight. There was no history of multiple joint pain, fever, thyroid dysfunction or diabetes mellitus. Patient is hypertensive since one year and on regular treatment. There was no history of vitiligo, collagen vascular disease, diabetes mellitus and thyroid disorder in the family.

On examination, multiple depigmented patches were present over the lips, peri oral areas (Figure 1), right nipple, left mammary region involving nipple areola complex, right loin, antero-lateral aspect of both the legs and plantar aspect of both feet. There were few depigmented macules on the dorsum of both feet. Depigmented macules were also present over the extensor aspect of both forearm and proximal nail folds of great toes bilaterally. A single erythematous plaque with adherent scales was present over the vertex of scalp. Erythematous plaques with adherent scales were also

present over, both upper and lower lips and the area above the upper lip superimposed on the depigmented patch. A single depigmented discoid plaque measuring 0.5×0.5 cm with adherent scales and surrounding rim of hyperpigmentation was present over the left side of dorsum of nose. Scaly plaques with crusts and fissure were seen on the lips. Oral cavity showed a single shallow ulcer on the hard palate. Great toe nails were dystrophic. Other nails were normal.

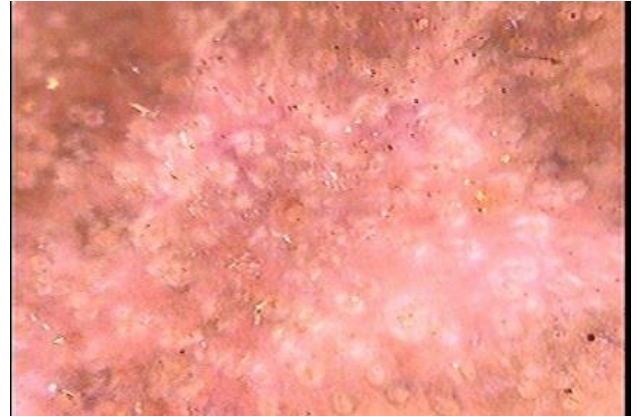


**Figure 1: Erythematous plaques with adherent scales present over, both upper and lower lips and the area above the upper lip superimposed on the depigmented patch.**

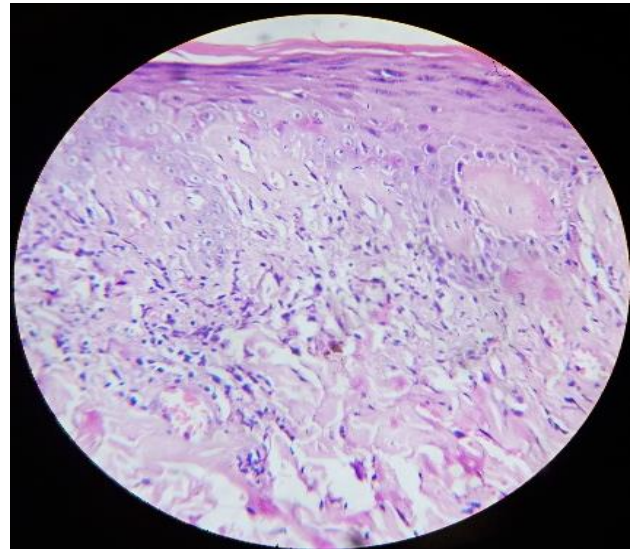


**Figure 2: Lesion around the mouth showed resolution with decrease in erythema and scaling and the underlying vitiligo lesion around the mouth stood exposed.**

Punch biopsy was done from the lesion over the scalp which showed thinned out epidermis with follicular plugging, hyperkeratosis, mild spongiosis, basal cell degeneration and dermo-epidermal junction showed band of chronic inflammatory cells comprising of lymphocytes and plasma cells extending around the follicles suggestive of discoid lupus erythematosus (Figure 4).



**Figure 3: Dermoscopy (polarised; 10X): Yellow arrow indicates follicular plugging, blue arrow indicates peri follicular halo, red arrow indicates telangiectasia, black circle indicates structure-less white area and blue triangle indicates structure-less brown area.**



**Figure 4: Shows hyperkeratosis, mild spongiosis, basal cell degeneration and dermo-epidermal junction showed band of chronic inflammatory cells comprising of lymphocytes and plasma cells.**

Dermoscopy (polarised mode, 10X magnification) revealed branching vessels, focal keratin plugs, perifollicular whitish halo and structure-less white and brown areas (Figure 3).

ANA and anti-dsDNA were negative. Complete hemogram, liver function test, renal function test, thyroid profile and random blood sugar levels were within

normal limits. Haemoglobin 11.9 g%, Total count 6300 cells/mm<sup>3</sup>, Differential count N<sub>40</sub> L<sub>50</sub> E<sub>1</sub>, ESR 15 mm/hour, RBC count 4.16 million/mm<sup>3</sup>, Platelet count 2.69 lakhs/mm<sup>3</sup>, PCV 35.3%, MCV 85.9 fL, MCH 28.6 pg, MCHC 33.7%, serum creatinine 0.9 mg/dL, serum urea 17 mg/dL, Total bilirubin 0.5 mg/dL, Direct

bilirubin 0.1 mg/dL, Total protein 6.8 g/dL, Albumin 3.7 g/dL, Globulin 3.1 g/dL, SGOT 57 U/L, SGPT 44 U/L, Alkaline phosphatase 218 U/L, TSH 2 iIU/ml. Based on clinical and histopathological features a diagnosis of Chronic Cutaneous Lupus erythematosus over pre-existing vitiligo (acro-orificial/lip-tip vitiligo) was made.

**Table 1: Case reports of discoid lupus erythematosus associated with vitiligo and other diseases.**

Author	Year	Association	Treatment
Temine and Tramler	1961	DLE + vitiligo	None
Chowdhary and Banerjee	1968	DLE + vitiligo	None
Forestier et al	1981	DLE + vitiligo	None
Jeffrey and Callen	1984	DLE+ vitiligo + autoimmune thyroiditis	Oral hydroxychloroquine + topical steroids + thyroid hormone
Pavithran	1986	DLE + vitiligo + alopecia areata	None
Nath et al	1988	Vitiligo + drug induced DLE	PUVA
Khosravi et al	2000	DLE+ Vitiligo + Chronic dermatophytoses	Topical and systemic corticosteroids+ Chloroquine + topical and systemic antifungals
Khosravi et al	2003	DLE + vitiligo + malignant melanoma + urticaria	Oral chloroquine +oral steroids + topical steroids
Ulker et al	2005	DLE + vitiligo	None
Johnson et al	2008	DLE+ vitiligo	Oral hydroxychloroquine + topical steroids
Monsálvez V et al	2010	Cutaneous lupus erythematosus + vitiligo	None
Jeon et al	2012	Disseminated DLE + lip-tip vitiligo	None
Sharma et al	2013	Lip-tip vitiligo + disseminated discoid lupus erythematosus + hypothyroidism.	Oral hydroxychloroquine + topical steroids
Present case	2018	DLE + vitiligo	Topical steroids

Patient was prescribed topical mid-potent corticosteroid for lesions around lips and nose, to be applied twice daily. Topical super-potent corticosteroids with salicylic acid twice daily application was prescribed for the lesion on scalp. She was also given broad spectrum sunscreen lotion to be applied in all the photo-exposed areas. Ten days later, lesions on the nose and scalp flattened with decrease in scaling and erythema (Figure 2). Lesion around the mouth also showed resolution with decrease in erythema and scaling and the underlying vitiligo lesion around the mouth stood exposed.

## DISCUSSION

Chronic cutaneous lupus erythematosus (CCLE) is an inflammatory and photosensitive dermatosis that likely stems from a poorly understood immune dysregulation with an autoimmune reaction in genetically predisposed individuals. CCLE occurs more frequently in women and is often characterized by erythematous, scaling plaques but may exhibit clinical variability, such as hypertrophic or lichenoid features. Around 5% of patients with DLE may progress to SLE. Vitiligo is also an autoimmune disorder with underlying genetic susceptibility and around 30% of patients with generalised vitiligo have associated autoimmune diseases.<sup>2</sup> However, the

pathogenesis of concurrence of vitiligo and CCLE has not been fully understood.<sup>3</sup>

In our patient, DLE lesions developed over the vitiligo lesions two years after the onset of vitiligo. Coexistence of two or more autoimmune diseases such as lupus erythematosus and vitiligo has been uncommonly reported in literature. The co-existence of DLE and vitiligo must be differentiated from post-inflammatory depigmentation left behind after resolution of DLE lesions. Forestier et al described two patients, one with discoid lupus who developed vitiligo-like lesions and one with vitiligo whose clinical course was complicated by the appearance of lesions of discoid lupus.<sup>4</sup> Both these patients presented with elevated antinuclear antibodies, while all other autoantibodies were negative. This was in contrast to our case wherein ANA and anti ds-DNA were negative. Other authors have subsequently reported further, isolated cases of patients with lupus who developed vitiligo over the course of their disease.<sup>5</sup> In two cases reported by Forestier et al., DLE occurred within the vitiliginous skin on both exposed and non-exposed surfaces.<sup>3</sup> A similar occurrence was reported by Jeffrey and Callen, Temine and Tramier, Chowdhury and Banerjee, Forestier et al and Johnson et al.<sup>2,4,6-8</sup> Table 1

shows a few case reports of patients who had coexisting vitiligo and DLE and their treatment. Most of these patients resided in regions of potential sun exposure, such as India and Southern Europe.<sup>3-6,9-11</sup>

It has been observed that the autoimmune disorders are significantly elevated in vitiligo probands: Vitiligo itself, autoimmune thyroid disease, pernicious anemia, Addison's disease, systemic lupus erythematosus, and probably inflammatory bowel disease. Ying Jin et al identified several chromosomal regions that appear to contribute to this epidemiologic association, including one on chromosome 17p13.<sup>5</sup>

Based on a review of the literature, we believe that the coexistence of these two autoimmune diseases is not as common as might be expected for these autoimmune processes. Recent data show an autoimmune genetic basis that might further our understanding of the coexistence of the two conditions.

Treatment of vitiligo in the presence of DLE is mainly local and systemic corticosteroid. However, it is known that lip-tip vitiligo would not respond much to topical and systemic corticosteroids. The presence of one disorder may affect the therapy of the other, as photochemotherapy which would be a good alternative for lip-tip vitiligo cannot be given in the presence of DLE so one has to cautiously treat the two.

Ultraviolet light exposure and chronic inflammation play a role in development of squamous-cell carcinoma (SCC) over a pre-existing lesion of CCLE. While SCC formation in long-standing vitiligo is rare, it has been associated with PUVA photochemotherapy and with intense sun exposure.<sup>2</sup> Squamous-cell carcinomas, sometimes multiple, have been described as arising in lesions of CCLE. Hence there is a need for regular follow up of patients with vitiligo with co-existent DLE, as the exposure to ultra violet radiation may potentiate the development of SCC over the DLE lesions.

*Funding: No funding sources*

*Conflict of interest: None declared*

*Ethical approval: Not required*

## REFERENCES

1. Stanca BA, Richard SA, David NA. Vitiligo. In: Goldsmith LA, Katz SI, Gilchrist BA, Paller AS, Leffel DJ, Wolff K, editors. Fitzpatrick's dermatology in general medicine. 8th ed. McGrawHill; 2012: 792.
2. Johnson H, Bossenbroek N, Rosenman K, Meehan SA, Robbles M, Pomeranz MK. Chronic cutaneous Lupus Erythematosus in Vitiligo. Dermatol Online J. 2014;14(10):10.
3. Jeon SY, Hong JW, Song KH, Kim KH. Vitiligo developed in a patient with discoid lupus erythematosus. Korean J Dermatol. 2012;50(9):830-3.
4. Forestier JY, Ortonne JP, Thivolet J, Souteyrand P. Association of lupus erythematosus and vitiligo. Ann Dermatol Venerol. 1981;108:33-8.
5. Sharma S, Sarkar R, Garg VK, Bansal S. Coexistence of lip-tip vitiligo and disseminated discoid lupus erythematosus with hypothyroidism: Need for careful therapeutic approach. Indian Dermatol Online J. 2013;4(12):112-4.
6. Callen JP. Discoid lupus erythematosus in a patient with vitiligo and autoimmune thyroiditis. Int J Dermatol. 1984;23:203-4.
7. Temime P, Tramier G. Symmetrical lupus erythematosus on vitiligo of the hands. Bull Soc Fr Dermatol Syphiligr. 1961;68:91-2.
8. Chowdhury DS, Banerjee AK. Development of discoid lupus erythematosus in vitiligo. Bull Calcutta Sch Trop Med. 1968;16:111-2.
9. Khosravi AR, Mansouri P, Moazzeni M. Case report: Chronic dermatophyte infection in a patient with vitiligo and discoid lupus erythematosus. Mycoses. 2000;43:317-9.
10. Pavithran K. Alopecia areata and discoid lupus erythematosus in a patient with vitiligo. Indian J Dermatol Venereol Leprol. 1986;52:115-6.
11. Monsálvez V, Garía-Cano I, Fuertes L, Llamas R, Vanaclocha F. Cutaneous Lupus Erythematosus and Vitiligo. Actas Dermosifiliogr. 2010;101(4):375-7.

**Cite this article as:** Devaraj Y, Sathyanarayana BD, Swaroop MR, Sowmya Shree H, Ravindranath M, Ghosh A. Discoid lupus erythematosus in acro-orificial vitiligo. Int J Res Dermatol 2018;4:456-9.