

Original Research Article

Pigmentary demarcation lines: a clinical profile of 50 subjects and report of new pattern of pigmentation observed

Anju Antony^{1*}, Pramod Kumar²

Department of Dermatology, ¹Karuna Medical College, Palakkad, Kerala, ²Kasturba Medical College, MAHE Hospital, Attavar, Mangalore, Karnataka, India

Received: 02 May 2018

Revised: 16 May 2018

Accepted: 17 May 2018

***Correspondence:**

Dr. Anju Antony,

E-mail: anju_antony94@yahoo.co.in

Copyright: © the author(s), publisher and licensee Medip Academy. This is an open-access article distributed under the terms of the Creative Commons Attribution Non-Commercial License, which permits unrestricted non-commercial use, distribution, and reproduction in any medium, provided the original work is properly cited.

ABSTRACT

Background: Pigmentary demarcation lines (PDL) correspond to a border of abrupt transition between the more deeply pigmented skin of the outer surfaces and the lighter inner surfaces. On the basis of their location they have been classified into eight types, type A to type H. The present study is an attempt to obtain a better understanding of the clinical types of pigmentary demarcation lines in Indians, and to report any previously undescribed patterns of pigmentation.

Methods: Patients attending the Outpatient Department for various complaints were examined for the presence of pigmentary demarcation lines, and those with pigmentary demarcation lines were analysed further.

Results: 50 subjects of Fitzpatrick skin types 4 and 5, with pigmentary demarcation lines were examined in detail. The various types of pigmentary demarcation lines seen were Type A (38%), Type B (14%), Type C (24%), Type F (22%), Type G (4%), Type H (4%). All types were more common in females with the exception of Type C, which was observed only in males. Type D and Type E PDL were not observed in any of the subjects screened.

Conclusions: The most common type of PDL observed in our study was Type A PDL, followed by Type C PDL. The youngest subject was 2 years old, the oldest was aged 75. The majority were seen in adults; Type A and Type C PDL were the common types seen in children. A family history of PDL was present in 5 (10%) and all were females. A hitherto undescribed pigmentary demarcation line is also described along with this study.

Keywords: Pigmentary demarcation lines, PDL, Pigmentation

INTRODUCTION

Pigmentary demarcation lines correspond to a border of abrupt transition between the more deeply pigmented skin of the outer surfaces and the lighter inner surfaces.¹ They indicate a duality in the population of melanocytes which may be related to underlying neural influence and perhaps to actinic stimulation which, at least phylogenetically, would be more pronounced over the more exposed extensor surfaces.²

On the basis of their location they have been classified into eight types, Type A to Type H, including the recently described facial pigmentary demarcation lines.³⁻⁵

In a study in India, by Somani et al, facial PDLs, especially types F and G, were observed regularly in other family members, pointing to a genetic predisposition.⁶

Types of pigmentary demarcation lines

Type A: It is most apparent over the anterior brachial surfaces. The other sites where it can be seen include the anterior aspect of the forearm, the upper border of the axilla, the trans-pectoral region, and the posterior brachial region.³

Type B: It is most apparent over the inner thigh, and can also spiral down the leg, extending to the inner ankle or to the lateral malleolus.

Type C: It is most apparent over the pre and para sternal region; it is also seen over the abdominal midline.³

Type D: This is most apparent over the posteromedial area of the spine, and is the rarest of the PDLs.⁷

Type E: They are slightly hypopigmented streaks, wider bands, or lanceolate areas, and are located within a zone from the mid one-third of the clavicle to the peri-areolar skin.^{2,3}

Type F: This was first described in Indians by Malakar as sharply demarcated lines separating a relatively darker zone from a lighter area over the face and these lines are almost always bilateral.⁵

Type G: It has been described as two inverted cones lying in close proximity, looking like the letter ‘W’, with a faint strip of normal pigmentation in between.

Type H: This is seen as symmetrical bands of linear hyperpigmentation extending from just below the angle of the mouth to the lateral aspects of the chin.⁶

Objectives

The present study is an attempt to obtain a better understanding of the clinical types of pigmentary demarcation lines in an Indian subpopulation, and to describe any unusual patterns of pigmentation observed.

METHODS

This was a cross-sectional study conducted in the Outpatient department of Dermatology, KMC Hospital,

Attavar and Wenlock District Hospital, Mangalore, between December 2010 and October 2012.

Patients attending the Outpatient Department for various complaints were randomly selected and examined for the presence of pigmentary demarcation lines, and those with PDLs were analysed further. Those having cutaneous lesions over the sites of PDLs were excluded from the study. Patients of all age groups were included in the study after taking informed consent and a detailed history regarding the onset, duration and sites of pigmentation, along with a family history of similar complaints was sought for. Examination was done in natural light to look for the presence of pigmentary demarcation lines.

The approval of the Institute’s Time Bound Research Ethics Committee was obtained on December 13, 2010.

Statistical analysis was done using Statistical Package for Social Sciences, and Chi-square test and Fisher’s exact test were used; p value was calculated and considered to be significant if <0.05.

RESULTS

Of the fifty subjects noted to have at least one type of PDL, 20 (40%) were males and 30 (60%) were females. Age of patients with pigmentary demarcation lines ranged from 2 to 75 years. 31 (62%) were above the age of 18, and of these, 22 (44%) were females and 9 (18%) were males. Only three subjects were in the adolescent age group (13-18 years), while 16 (32%) were children (below 12 years). Among children, PDLs were slightly more common in males (18%) than in females (14%).

Pigmentary demarcation lines were noticed by 14 (28%) of the total number of subjects with PDL, and all were females. Using Fishers exact test, p value was calculated and it was found to be highly significant (p=0.003).

Duration of PDL as observed by the patient was between 6 to 10 years in 7 (14%); between 1 to 5 years in 5 (10%), and less than 1 year in 2 (4%) patients. In 3 patients the PDLs appeared around puberty. Change in intensity of pigmentation with progressive darkening was seen in 10 (20%) while 4 (8%) patients reported no significant change in intensity of pigmentation.

Table 1: Age distribution of the various pigmentary demarcation lines.

PDL type	Total number of PDLs	Percentage (%)	Age group <12 years	Age group 13-18 years	Age group >18 years
Type A	19	38	9	0	10
Type B	7	14	0	0	7
Type C	12	24	7	2	3
Type F	11	22	0	1	10
Type G	2	4	0	0	2
Type H	2	4	0	0	2

Table 2: Sex distribution of the various types of pigmentary demarcation lines.

PDL type	Males (%)	Females (%)	Total
Type A	3 (15.7)	16 (84.2)	19
Type B	2 (28.5)	5 (71.4)	7
Type C	12 (100)	0	12
Type F	3 (27.2)	8 (72.7)	11
Type G	-	2 (100)	2
Type H	-	2 (100)	2
Co-Existing Type A, Type B	-	2 (100)	2
Co-existing Type G, Type B	-	1 (100)	1

Medications including topical skin lightening agents, sunscreens and chemical peels were used by patients who noticed an increase in the intensity of pigmentation. A family history of PDL was present in 5 (10%) of the 50 subjects and all were females.

The various pigmentary demarcation lines we observed were distributed among various age groups as shown in (Table 1). Majority of patients had only one type of PDL, while 3 patients had co-existing PDLs.

As shown in (Table 2), PDL Type A, Type B, and Type F were more common in females than males, and were seen in (32% vs 6%), (10% vs 4%) and (16% vs 6% respectively. Using Chi square test, p value was calculated, and was found to be very highly significant ($p < 0.001$). PDL Type C was seen in 12 (24%) males, while Type G and Type H were seen in 2 (4%) females each.

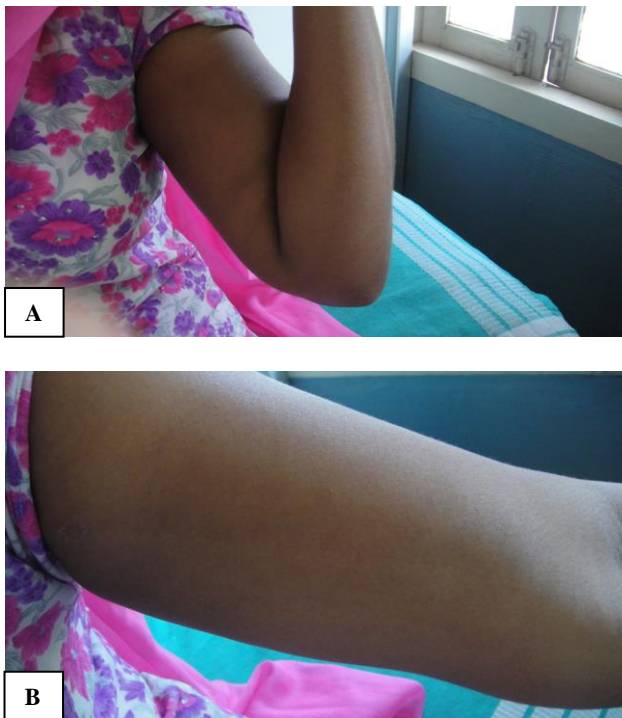

Figure 1: (A) Type A pigmentary demarcation line over the left forearm; (B) Type A pigmentary demarcation line over the left arm.

Type A PDL (Figure 1) was bilaterally symmetrical in 17 (89.4%) out of the 19 subjects who had this type of PDL and 2 (11.7%) were males and 15 (88.2%) were females.

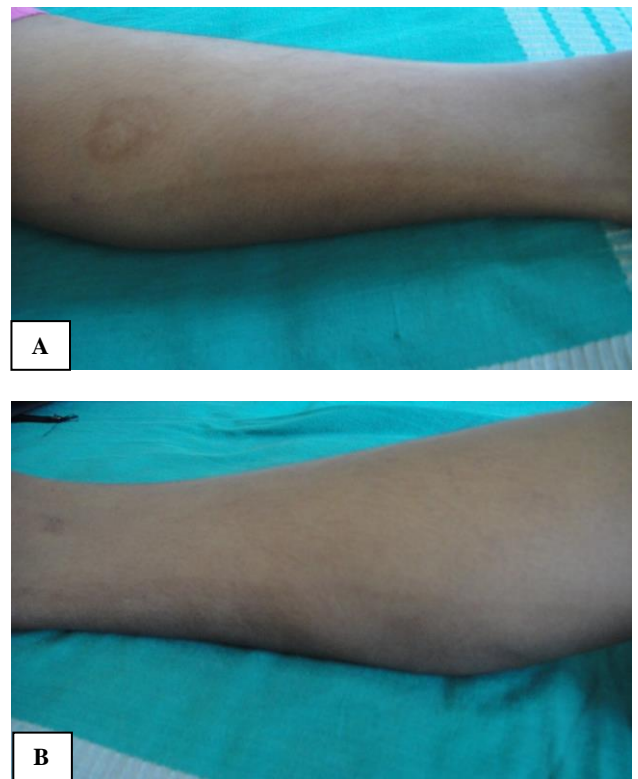

Figure 2: (A) Type B PDL, present bilaterally over the lower limbs; (B) Type B PDL seen over the right lower limb.

Type B PDL (Figure 2) was found to be bilaterally symmetrical in 85.7%. It was seen unilaterally in one female patient.

Pigmentary demarcation lines Type C, F, G and H were observed to be bilaterally symmetrical in all patients in whom these PDLs were observed. The intensity of pigmentation was uniform in (96%), and of the 2 patients who had uneven pigmentation, both were females, and they had the facial PDLs Type F and Type G.

New pattern of pigmentation observed

An unusual linear hypopigmentation was observed in a 35 year old man. As the patient was unaware of the pigmentation, a detailed history could not be elicited. On examining him we found that he had two hypopigmented lines in the pectoral area, which were obliquely oriented and bilaterally symmetrical, extending downward from the periareolar area (Figure 3A).

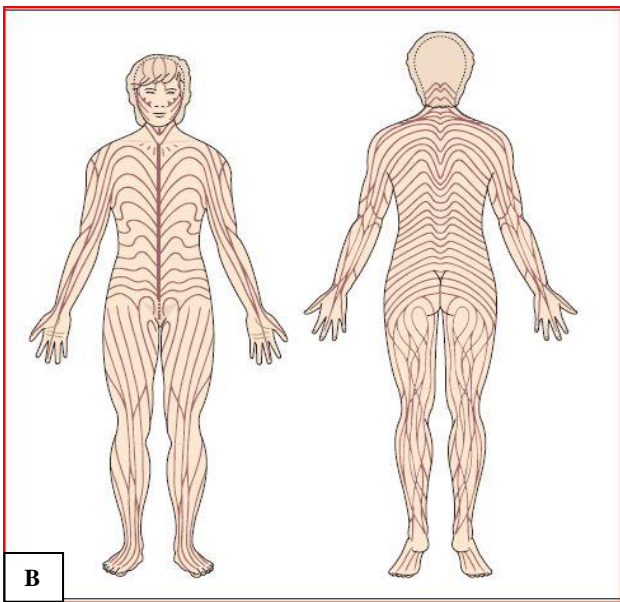
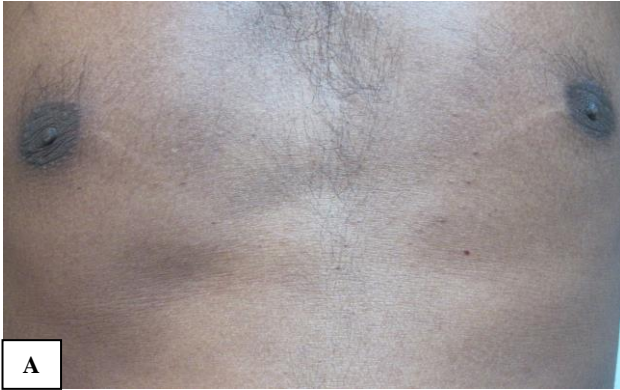

Figure 3: (A) Bilaterally symmetrical, obliquely oriented hypopigmented lines seen over the pectoral area, extending downwards from the peri-areolar area; (B) Blaschko's lines: as seen here, the pigmentary lines observed in our patient corresponds well with the lines of Blaschko.¹³

The hyperpigmented lines did not have any loss of sensation, and the surrounding skin appeared normal. He did not have any other pigmentary demarcation lines elsewhere. Although this linear pigmentation did not correspond to any of the previously described PDLs, we would like to propose that it could be a new subtype of Type E PDL for the following reasons:

Location: The proximity of this linear pigmentation to Type E PDL which is well-described as located within a zone from the mid one-third of the clavicle to the periareolar skin prompted us to consider it as a subtype of Type E PDL. They have been described as hypopigmented streaks, wider bands or lanceolate area, which tend to be bilaterally symmetrical and obliquely oriented as was the case with our patient.² Type E PDL has been divided into three subtypes:

Type 1: Subclavicular, Type 2- Midway between mid-clavicle and nipple, Type 3-peri-areolar.³

Pigmentation follows lines of Blaschko

The pattern of pigmentation observed in our patient corresponds well with Blaschko's lines (Figure 3b). Blaschko's lines refer to a system of lines on the surface of the human body which the linear naevi and dermatoses follow. Krivo who reviewed the subject of pigmentary demarcation lines, considers that PDLs follow the Lines of Blaschko, and they represent a common form of mosaicism most easily visible in dark-skinned people.⁸

Therefore, in view of its proximity to Type E PDL and due to the fact that it follows Blaschko's lines, we would like to propose that it could be a new subtype of Type E PDL.

DISCUSSION

In this study, done in the Indian subpopulation, females outnumbered males among the patients found to have pigmentary demarcation lines. Among the Japanese, PDLs were found to be more common in females than in males.^{3,9} In Caucasians, PDLs are more common in women.⁷ Among Indians, facial PDLs were found to be more common in females, which compares well with this study.⁶

The presence of PDLs was noticed by 14 subjects (5.6%) and all were females. In a study conducted by Somani et al, 25% of the patients had noticed the pigmentary demarcation lines.⁶

Duration of pigmentary demarcation line as observed by the subject was between 6 to 10 years in 7 (50%); between 1 to 5 years in 5 (35.7%), and less than 1 year in 2 (14.2%). In the study conducted by Somani et al, all patients reported that the PDL appeared around puberty.⁶ In this study, in 3 patients the PDLs appeared around puberty.

A family history of PDLs was present in 5 (2%). An autosomal dominant mode of inheritance of PDLs was suggested by Ito, in a survey of PDLs in the Japanese.¹⁰ In previous studies among those with facial pigmentary demarcation lines, a family history was positive in 35% and 65%.^{6,11} However, patients cannot be relied upon for

diagnosing PDLs in their relatives and this could account for the variations seen.¹²

In a study by James et.al, done in Americans, Type A was found to be more common in females, which correlates well with this study done in the Indian subpopulation.⁷

In a study by Somani et al, Type F, G and H were more common in females, and only a negligible number of males (0.74%) had these PDLs, which compares well with this study.⁶

In a study by James et al, a higher number of females had Type B PDL, which compares well with our study. Type C was more common in males in the above study, which is comparable with this study.⁷

In our study, Type D PDL was not seen in any patient. This has been reported to be the least common PDL, only rarely seen in the Japanese population and the least common type in a study by James et al.^{3,7}

Pigmentary demarcation lines generally do not need treatment. However, in patients who find it cosmetically unacceptable, the various treatment modalities that have been tried include:

- 1) Kligman regimen: This was used as a modality of treatment in patients with facial PDLs.⁶ However, only a negligible change in colour was reported.
- 2) Glycolic acid peels. This was used in 15 patients not responding to treatment with Kligman regimen. There was about 10% reduction in skin pigmentation and after stopping the treatment the pigmentation recurred.⁶
- 3) Q-switched Alexandrite laser has been satisfactorily used to treat Type A PDLs with no adverse effects.¹²

CONCLUSION

We observed that the females outnumbered males among the patients found to have pigmentary demarcation lines. The presence of PDLs was noticed by 14 subjects (5.6%) and all were females. Duration of pigmentary demarcation line as observed by the subject was between 6 to 10 years in 7 (50%); between 1 to 5 years in 5 (35.7%), and less than 1 year in 2 (14.2%). In this study, in 3 patients the PDLs appeared around puberty. A family history of PDLs was present in 5 (2%). The most common type of PDL observed in our study was Type A PDL, followed by Type C PDL. The youngest subject was 2 years old, the oldest was aged 75. The majority were seen in adults; Type A and Type C PDL were the common types seen in children.

This study describes the various types of PDLs including both truncal and facial PDLs seen in an Indian

subpopulation, and describes a hitherto undescribed pigmentary demarcation line.

Funding: No funding sources

Conflict of interest: None declared

Ethical approval: The study was approved by the institutional ethics committee

REFERENCES

1. Matzumoto S. Uber eine eigentumliche Pigmentverteilung an den Voigtschen Linien, (Beitrag zur Kenntnis der Voigtschen Grenzen). *Arch Dermatol Syph* (Berlin). 1913;118:157-64.
2. Selmanowitz VJ, Krivo JM. Pigmentary demarcation lines-Comparison of Negroes with Japanese. *Br J Dermatol.* 1975;93:371-7.
3. Miura O. On the demarcation lines of pigmentation observed among the Japanese, on inner sides of their extremities and on anterior and posterior sides of their medial regions. *Tohoku J Exp Med.* 1951;54:135-40.
4. Miura O. A supplement to the demarcation lines of pigmentation observed among the Japanese, on inner sides of their extremities and on anterior and posterior sides of their medial regions. *Tohoku J Exp Med.* 1952;56:1-2.
5. Malakar S, Dhar S. Pigmentary Demarcation Lines over the face. *Dermatol.* 2000;200:85-6.
6. Somani VK, Razvi F, Sita VNV. Pigmentary Demarcation Lines over the face. *Indian J Dermatol Venereol Leprol.* 2004;70:336-41.
7. James WD, Carter JM, Rodman OG. Pigmentary demarcation lines: A population survey. *J Am Acad Dermatol.* 1987;16:584-90.
8. Krivo JM. How common is pigmentary mosaicism? *Arch dermatol.* 1997;133:527-8.
9. Ito K. The peculiar demarcation of pigmentation along the so-called Voigt's line among the Japanese. *Dermatol Int.* 1965;4:45-7.
10. Al-Samary A, Al-Mohizea S, Bin-Saif G, Al-Balbeesi A. Pigmentary demarcation lines on the face in Saudi women. *Indian J Dermatol Venereol Leprol.* 2010;76(4):378-81.
11. Vollum DI. Skin markings in Negro children from the West Indies. *Br J Dermatol.* 1972;86:260-3.
12. Bukhari IA. Effective Treatment of Fitcher's lines with Q-switched alexandrite laser. *J Cosmet Dermatol.* 2005;4(1):27-8.
13. Irvine AD, Mellow JE. Genetics and Genodermatoses. In: Tony B, Stephen B, Neil L. Rook? *Textbook of Dermatology* 8th edn. Blackwell; 2010: 15-17.

Cite this article as: Antony A, Kumar P. Pigmentary demarcation lines: a clinical profile of 50 subjects and report of new pattern of pigmentation observed. *Int J Res Dermatol* 2018;4:323-7.