

Case Report

Lingua plicata in pustular psoriasis: a rare case report

Saurabh Sharma^{1*}, Anika Goel¹, Roopam Bassi²

¹Department of Dermatology, Venereology, & Leprosy, ²Department of Physiology, Sri Guru Ram Das Institute of Medical Sciences & Research, Amritsar, Punjab, India

Received: 11 April 2018

Revised: 02 July 2018

Accepted: 05 July 2018

*Correspondence:

Dr. Saurabh Sharma,

E-mail: drsaurabhsharma@yahoo.co.in

Copyright: © the author(s), publisher and licensee Medip Academy. This is an open-access article distributed under the terms of the Creative Commons Attribution Non-Commercial License, which permits unrestricted non-commercial use, distribution, and reproduction in any medium, provided the original work is properly cited.

ABSTRACT

Lingua plicata also referred to as scrotal tongue, furrowed tongue, grooved tongue, and plicated tongue is a relatively uncommon condition. It is characterized by multiple asymptomatic fissures or grooves over the tongue, resembling the surface of the brain due to the appearance of sulci and gyri, hence, it has also been referred to as cerebriform tongue. Despite being an asymptomatic condition, lingua plicata is a cause for concern as it can progress to secondary complications due to trapping of food in the fissures. Lingua plicata has been reported in association with pemphigus vegetans of the neumann variety and very rarely with other dermatological conditions such as psoriasis. Pustular psoriasis is an uncommon form of Psoriasis that may be localized or generalized. Acute generalized pustular psoriasis also known as Von Zumbusch disease, is a condition in which the patient characteristically shows features of toxicity, high grade fever and acute generalized pustules over an erythematous base and may be associated with oral mucosal changes in the form of erythema or geographic tongue. This case report describes a 33 year old male presenting with generalized pustular psoriasis and lingua plicata. The patient was treated with intravenous steroids and oral acitretin following which the psoriatic lesions and lingua plicata remitted.

Keywords: Lingua plicata, Scrotal tongue, Pustular psoriasis

INTRODUCTION

Lingua plicata was first reported in patients of Neuman type of pemphigus vegetans.¹ This is a rare form of pemphigus, in which there is a progression of preexisting lesions of pemphigus vulgaris into vegetative lesions, involving intertriginous sites.² Other associations of lingua plicata include Melkersson-Rosenthal syndrome, Acrodermatitis continua of Hallopeau, Bazex-Dupre-Christol syndrome, Cowden syndrome, Down syndrome and Pachyonychia congenita.³ Uncommonly, this benign, asymptomatic condition may be a physiological finding in healthy elderly individuals.⁴ Lesions appear as furrows over the dorsal and lateral aspect of the tongue. These grooves become a store house for bacterial and fungal microorganisms, leading to secondary infections, halitosis, and focal glossitis.

Differential diagnoses of scrotal tongue are amyloid infiltration, geographic tongue, lymphedema, lymphangioma, macroglossia, mucosal neuroma, and syphilitic glossitis.³ Generalized pustular psoriasis was first described by Leo Ritter von Zumbusch in 1910, it is a rare form of pustular psoriasis which begins as generalized erythema, followed by yellow to white colored sterile pustules, which eventually become confluent. The pustular lesions resolve and result in desquamation and further may precipitate erythroderma due to extensive body surface area involvement.⁵ It is a highly debilitating condition and associated with high grade fever, electrolyte imbalance, excessive loss of protein from the body causing the patient to appear severely toxic.⁶ Commonly, acute generalized pustular psoriasis can also involve the oral mucosa in the form of geographic tongue or erythematous areas. Other variants

of generalized pustular psoriasis include annular, localized, exanthematic types, and impetigo herpetiformis.⁷ Interestingly, there are no prior case reports relating the presence of lingua plicata and pustular psoriasis.

CASE REPORT

This is a report of a 33 year male that presented with the chief complaint of generalized itching, redness, and scaling over the body, in association with fever for one month. The lesions began over bilateral dorsae of hands, gradually extending to involve dorsae of feet, followed by abdomen, back, buttocks, scalp, face, bilateral arms and legs. Examination revealed the patient to be in erythroderma, with generalized pustular lesions over an erythematous base and scaly plaques (Figure 1) with only relative sparing of the chest. The oral mucosa showed presence of lingua plicata (Figure 2). No present or past history of pain or erythema in the oral mucosa and no history of any gastrointestinal disturbance. There was no present or past history of scalp scaling. There was no past history of similar lesions.

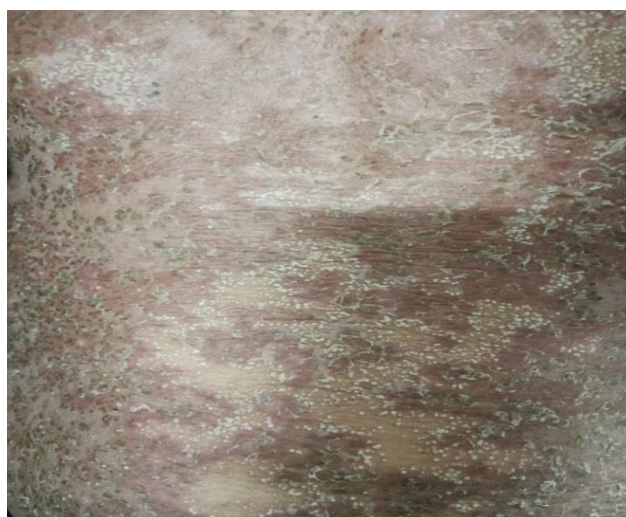

Figure 1: Generalized pustular lesions over an erythematous base and scaly plaques.

Biopsy from the pustule over the abdomen revealed hyperkeratosis, orthokeratosis, parakeratosis, munro's microabscesses. Biopsy from the dorsal aspect of tongue revealed acanthosis and papillomatosis. Routine investigations were carried out- complete blood count, serum electrolytes, blood sugar, blood urea, serum creatinine, liver function tests, and abdominal ultrasonography, all of which were within normal limits. The biopsy findings aided in the confirmation of the diagnosis of pustular psoriasis.

Pyostomatitis vegetans was ruled out through history, there was no associated bowel complaint, further ruling out inflammatory bowel disease.

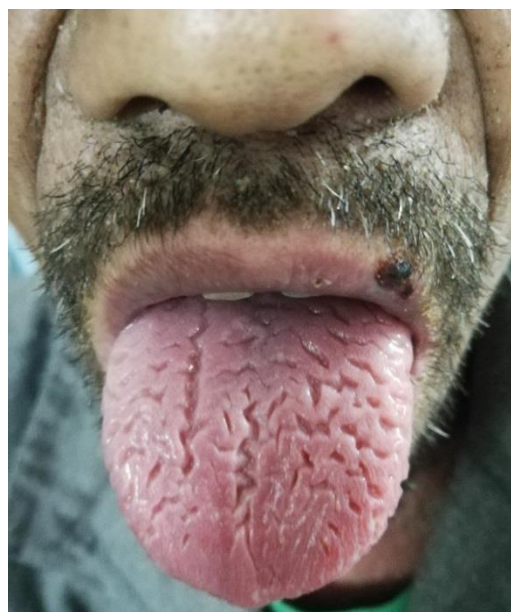


Figure 2: Lingua plicata.

The patient was treated with intravenous dexamethasone 4 mg twice a day and oral acitretin 25 mg twice a day following which there was rapid and almost complete clearance of cutaneous lesions and significant improvement in lingua plicata within one week.

DISCUSSION

This case is being reported for its rarity, the association of lingua plicata with acute generalized pustular psoriasis. The presence of oral lesions in psoriasis itself has been reported to be controversial and it is believed by some that the oral mucosal changes may be independent of the disease.⁸ However, other investigators have come to a definite conclusion that acute generalized pustular psoriasis may have oral mucosal changes, which further supports our findings. oral mucosal lesions that have been reported in psoriasis include- benign migratory glossitis, diffuse oral and tongue erythema, hairy tongue, rhomboid glossitis, and depapillated tongue.⁹ Lingua plicata is generally benign and asymptomatic, however, due to the presence of fissures, food lodge in to the grooves leading to poor hygiene, secondary infections by bacterial and fungal colonization, halitosis, and focal glossitis, further leading to social embarrassment and psychological distress for the patient.

Some cases of lingua plicata may spontaneously resolve, although there is no definite treatment, prevention of secondary complications is crucial. This may be done by brushing of the dorsa of tongue and good oral hygiene.¹⁰

Funding: No funding sources

Conflict of interest: None declared

Ethical approval: Not required

REFERENCES

1. Madke B, Nayak C. Eponymous signs in dermatology. *Indian Dermatol Online J*. 2012;3:159-65.
2. Son YM, Kang HK, Yun JH, Roh JY, Lee JR. The Neumann Type of Pemphigus Vegetans Treated with Combination of Dapsone and Steroid. *Ann Dermatol*. 2011;23:310-3.
3. Jackson SM. The Diagnosis. In: Jackson SM, Nesbitt LT, Differential Diagnosis for the Dermatologist. Illustrated ed. Springer Science & Business Media; 2008: 1109.
4. Nisa L, Giger R. Lingua Plicata. *CMAJ*. 2012;184:241.
5. Neema AM, Upadya G, Kumar P, Kuruvila M. Exfoliative Dermatitis Secondary to Acute Generalized Pustular Psoriasis in a Child: A Case Report. *Clin Pediatr Dermatol*. 2016;2:2.
6. Zelickson BD, Muller SA. Generalized Pustular Psoriasis: A review of 63 Cases. *Arch Dermatol*. 1991;127:1339-45.
7. Baker H, Ryan TJ. Generalized Pustular Psoriasis. *British J Dermatol*. 1968;80:771-93.
8. Buchner A, Begleiter A. Oral Lesions in Psoriatic Patients. *Oral Surgery, Oral Medicine, Oral Pathol*. 1976;41:327-32.
9. Daneshpazhooh M, Moslehi H, Akhyani M, Etesami M. Tongue lesions in psoriasis: a controlled study. *BMC Dermatol*. 2004;4:16.
10. Avhad G, Jerajani HR. Lingua Plicata. *Indian Dermatol Online J*. 2014;5(3):361.

Cite this article as: Sharma S, Goel A, Bassi R. Lingua plicata in pustular psoriasis: a rare case report. *Int J Res Dermatol* 2018;4:450-2.