

## Case Report

# Hailey Hailey disease-a rare case report

**Kumar Prateek\*, Meena Rinoo Banwarilal, Shyam Sundar Chaudhary, Meenakshi Garg**

Department of Dermatology, Rajendra Institute Of Medical Sciences, Ranchi, Jharkhand, India

**Received:** 21 July 2016

**Accepted:** 01 August 2016

**\*Correspondence:**

Dr. Kumar Prateek,

E-mail: [prateekdoppleganger@gmail.com](mailto:prateekdoppleganger@gmail.com)

**Copyright:** © the author(s), publisher and licensee Medip Academy. This is an open-access article distributed under the terms of the Creative Commons Attribution Non-Commercial License, which permits unrestricted non-commercial use, distribution, and reproduction in any medium, provided the original work is properly cited.

### ABSTRACT

Hailey-Hailey disease is an autosomal dominant acantholytic disorder relatively uncommon in India. It is characterized by painful, pruritic, foul smelling vesicles and bullous lesions with erosions in intertriginous areas such as the neck, axillae, inframammary areas and groin. The defect in ATPC2 gene leads to calcium channel dysfunction which results in defect in epidermis. Fungal infection, intertrigo, psoriasis, extramammary Paget's disease, acanthosis nigricans, pemphigus vegetans and Darier's disease are some of the dermatosis from which it needs to be differentiated. Histopathology has a key role in diagnosis of Hailey-Hailey disease with characteristic 'dilapidated brick wall' appearance. Hailey-Hailey disease can be easily misdiagnosed by general physicians due to lack of knowledge of this uncommon disease as it resembles dermatosis involving intertriginous areas. Due to its relapsing and remitting course there is a need to have effective treatment options. We report a case of 45 year old middle aged female who presented with on and off itchy papules & vesicles over right inframammary region around the umbilicus & medial aspect of right thigh. Skin biopsy revealed a diagnosis of Hailey-Hailey disease. This case is being reported due to its rare occurrence.

**Keywords:** ATPC2 gene, Dilapidated brick wall appearance, Hailey Hailey disease

### INTRODUCTION

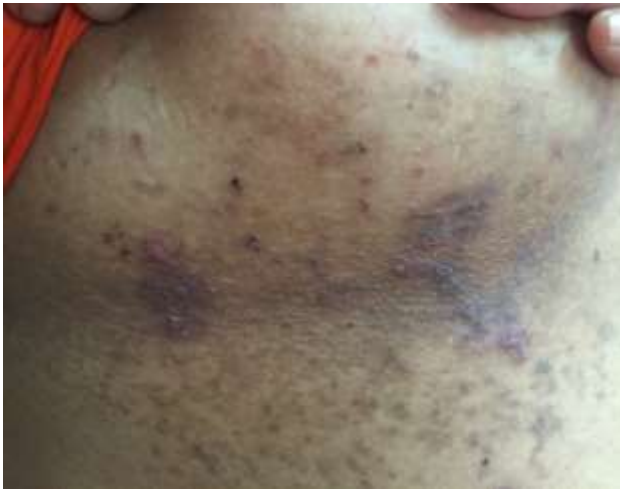Hailey-Hailey disease (HHD) is a rare autosomal dominant acantholytic disorder which recurs with remitting and relapsing episodes.<sup>1</sup> The defect in ATPC2 gene leads to calcium channel dysfunction which results in defect in epidermis. It is characterized by painful, pruritic, foul smelling vesicles and bullous lesions with erosions in intertriginous areas. Lesions get aggravated by friction, ultraviolet radiation, warmth, moisture and superficial bacterial, viral or fungal infections.<sup>2</sup> Histopathology has a key role in diagnosis of Hailey-Hailey disease. Topical modalities of treatment are antibiotics, steroids, tacalcitol another vitamin D3 derivative and tacrolimus while systemic treatment includes antibiotics, steroids, cyclosporine, dapsone, methotrexate and thalidomide. A case of Hailey-Hailey disease is presented here with characteristic

histopathological features to highlight the importance of early diagnosis.

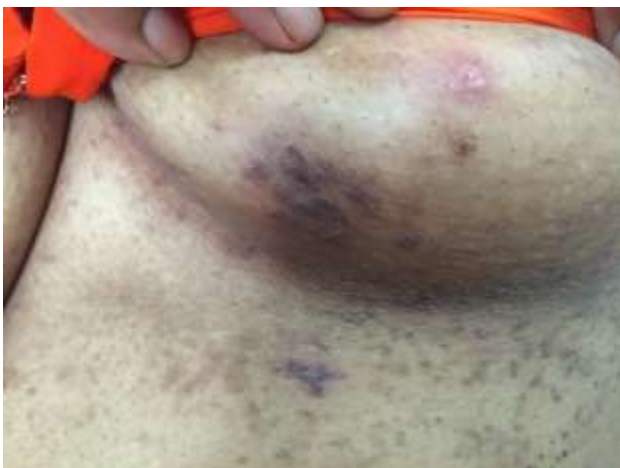### CASE REPORT

A 45 year old married female presented to our skin OPD with itchy, erythematous papules and vesicles mainly over the flexural areas on and off since 15 years. The first episode was 15 years back when she noticed sudden appearance of 8-10 itchy vesicles over erythematous base in the periumbilical region. It healed in 2-4 days with crusting and hyperpigmentation. On and off similar lesions used to occur on abdomen in the inframammary region and medial aspect of thigh, for which she was prescribed oral/topical medications. She got temporarily relieved of her symptoms. The lesions aggravated in the rainy seasons. Since last 2 years she has observed increase in size of vesicles to bulla which burst forming

Shallow ulcers with subsequent crusting. Such lesions appeared over the years every 2 months approximately. No history of fever, oral/genital lesions, involvement of nails, family history. Multiple itchy erythematous papules and thin roofed vesicles were found over hyperpigmented base on inframammary and groin region, also multiple hyperpigmented macules as shown in Figure 1 and 2 of healed previous lesions are also present. All her blood and urine routine examinations were within normal limits.



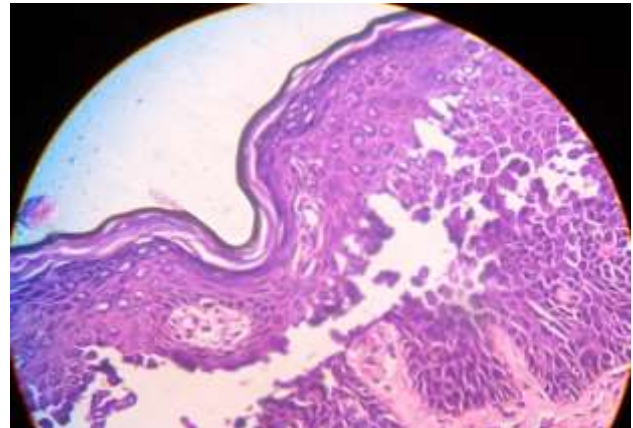
**Figure 1: Multiple erosions, a few vesicles noted over hyperpigmented base and hyperpigmentation due to earlier lesions over right inframammary area.**



**Figure 2: Multiple papules over a hyperpigmented base, a 1.5 by 1 cm ulcer secondary to rupture of a bullae over left breast and multiple brown discrete/confluent hyperpigmented macules over left inframammary region.**

On histopathological examination widespread partial loss of cohesion between suprabasal keratinocytes are present, few keratinocytes are linked by few intact intercellular bridges-dilapidated brick wall appearance, the acantholytic cells have well defined nuclei and sharply lined cytoplasm, hyperkeratosis and moderate

lymphocytic infiltration of dermis is present as in Figure 3.



**Figure 3: HPE 40 X showing most of the suprabasal keratinocytes are acantholytic except a few with intact intercellular ridges forming dilapidated brick wall appearance; lymphocytic infiltration of dermis seen.**

## DISCUSSION

Hailey-Hailey disease also known as familial benign chronic pemphigus is a relatively uncommon disease in India. Family history is obtained in about two-thirds of the patients. Incidence is 1 in 50,000 and appears in the third decade of life.<sup>3,4</sup> It is rarely found genodermatosis having an autosomal dominant mode of inheritance.<sup>5</sup> It was first described in 1939 by dermatologist brothers Hailey and Hailey.<sup>6</sup> HHD occurs due to defect in  $Ca^{2+}/Mn^{2+}$ -ATPase protein 1 (hSPCA1) due to mutation in ATPC2.<sup>7</sup> resulting in lack of  $Ca^{2+}$ -signaling, irregular sorting and glycosylation of desmosomal proteins in keratinocytes which leads to epidermal defects. Lesions commonly occurs over intertriginous areas such as the neck, axillae, inframammary areas and groin. Generalized or disseminated forms are observed but are extremely rare, usually induced by superficial bacterial skin infection or even rarely drugs.<sup>8,9</sup> Lesions are initially flaccid vesicles and papules with erythematous base which may turn into macerated or crusted erosions, have tendency to spread peripherally and turn into chronic, moist, painful, malodorous vegetations with painful fissures. They leave behind postinflammatory hyperpigmentation without scarring. Although mucosal involvement is not common, oral, esophageal, vulvar and conjunctival involvement can occur.<sup>10,11</sup> Longitudinal white lines on the fingernails and fine palmer pits are observed. Atypical variants are hyperkeratotic, verrucous, lichenified, papular, papulovesicular and vesiculopustular forms. Aggravating factors are trauma, heat, sweating, UV light, and infections caused by scabies, bacteria, herpes virus and yeasts. It has tendency of remission and exacerbations. Rare consequence of HHD is squamous-cell carcinoma.<sup>12</sup> The differential diagnoses of Hailey-Hailey disease included fungal infection, intertrigo, psoriasis, extramammary Paget's disease, acanthosis

nigricans, pemphigus vegetans and Darier's disease. Histopathology of early lesions shows lacunae formed by suprabasilar clefting with acantholytic cells either singly or in clumps lining the clefts. The lacunae progress to broad, acantholytic vesicles and bullae. Intercellular oedema leads to partial acantholysis and gives rise to areas with characteristic dilapidated brick wall appearance. Acantholytic, dyskeratotic cells are found within the epidermis.<sup>13</sup>

### Treatment

Simple measures should be tried to reduce skin friction and keep flexures dry, including weight loss if appropriate, loose cool clothing and absorbent pads in skin folds. Combinations of moderate to potent topical corticosteroids with antibacterial and/or antifungal agents may be effective, particularly if topical steroids are applied promptly to early lesions, but no controlled trials have been performed.<sup>14</sup> The potency of topical corticosteroids should be reduced as soon as possible to prevent atrophy.<sup>15</sup> Systemic corticosteroids have been recommended for widespread disease.<sup>16-18</sup> Treatment may up-regulate SPCA1 expression either indirectly through an effect on cytokine production or by a direct effect on keratinocytes.<sup>19,20</sup>

The role of antiseptics, antibiotics and/or topical antifungal agents as steroid-sparing agents is unproven, but long-term antimicrobial treatment appears to be helpful.<sup>14,16,21</sup> Topical tetracyclines, aminoglycosides, fusidic acid or imidazoles may be added to a topical corticosteroid. Topical aminoglycosides may have the added benefit of reversing the effects of pathogenic nonsense mutations by inducing read through of stop mutations.<sup>22</sup> Low-dose oral tetracyclines, erythromycin or flucloxacillin should also be entertained. Oral treatment of herpes simplex should be considered in patients with unresponsive, painful disease. Without controlled trials the evidence base for the efficacy of any of the following is poor: ciclosporin topically and orally (3–4 mg/kg/day), topical tacrolimus, topical vitaminD3 analogues, oral retinoids and etanercept.<sup>23-33</sup> Botulinum toxin (axillary or inframammary) may help by reducing sweating, as may breast reduction.<sup>34-36</sup> Although ultraviolet light may exacerbate Hailey–Hailey disease, PUVA was apparently effective in some patients. Suberythematous UVB controlled both psoriasis and co-existing Hailey–Hailey disease in another patient. Superficial radiotherapy may produce temporary benefit. The long-term benefit of any surgical approach is equally uncertain, but many have been recommended for recalcitrant disease including: cryosurgery, excision with or without grafting, dermabrasion, electrodesiccation, various forms of laser surgery and photodynamic therapy.<sup>6,25,35</sup>

*Funding: No funding sources*

*Conflict of interest: None declared*

*Ethical approval: Not required*

### REFERENCES

- Persi c-Vojinovi c S, Milavec-Pureti c V, Dobri c I, Rados J, Spoljar S. Disseminated Hailey-Hailey disease treated with topical tacrolimus and oral erythromycin: Case report and review of the literature. *Acta Dermatovenerol Croat.* 2006;14:253–7.
- Schirren H, Schirren CG, Schluppen EM, Volkenandt M, Kind P. Exacerbation of the Hailey-Hailey disease with herpes simplex virus. Detection with polymerase chain reaction. *Hautarzt.* 1995;46:494-7.
- Valia AR, Ramesh V, Jerajani HR, Fernandez RJ. In: R G Valia, Ameet R Valia, eds. *IADVL Textbook of Dermatology Blistering Disorder.* 3<sup>rd</sup> Ed, Vol 1, Bhalani Publishers; 2008: 1127-1128.
- Sangoram SS, Indurkar VA, Amin-Hon VS, Nishigandh. Hailey-Hailey Disease- A Case Report. *Pravara Med Rev.* 2010;2:31-2.
- Cheng TS, Jong KK. A man with familial flexural rash: a case of Hailey-Hailey; Disease. *Hong Kong J Dermatol Venereol.* 2005;13:98-100.
- Michel B. "Familial benign chronic pemphigus" by Hailey and Hailey, April 1939. Commentary: Hailey-Hailey disease, familial benign chronic pemphigus. *Arch Dermatol.* 1982;118:774-83.
- Warycha M, Patel R, Meehan S, Merola JF. Familial benign chronic pemphigus (Hailey- Hailey disease). *Dermatol Online J.* 2009;15:15.
- Mashiko M, Akiyama M, Tsuji-Abe Y, Shimizu H. Bacterial infection-induced generalized HaileyHailey disease successfully treated by etretinate. *Clin Exp Dermatol.* 2006;31:57-9.
- Chlebicka I, Jankowska-Konsur A, Maj J, Plomer-Niezgoda E, Cezary Szepletowski J. Generalized Hailey-Hailey disease triggered by nonsteroidal antiinflammatory drug-induced rash: case report. *Acta Dermatovenerol Croat.* 2012;20(3):201-3.
- Thapa DP, Jha AK, Pudasaini S, Kharel C, Shrestha S. Genital Hailey-Hailey disease: A case report. *Our Dermatol Online.* 2013;4:87-8.
- Botvinick I. Familial benign pemphigus with oral mucous membrane lesions. *Cutis.* 1973;12:371-3.
- Holst VA, Fair KP, Wilson BB, Patterson JW. Squamous cell carcinoma arising in Hailey- Disorders of epidermal maturation and keratinization. In: Weedon D. *Skin Pathology* 2nd ed. Churchill Livingstone; 2002: 298-299.
- Weedon D. Disorders of epidermal maturation and keratinization. In: Weedon's, *Skin Pathology.* David Weedon (Ed) 2nd ed. Edinburgh, London, New York, Oxford, Philadelphia, St. Louis, Sidney, Toronto: Churchill Livingstone; 2002: 298-299
- Burge SM. Hailey–Hailey disease: The clinical features, response to treatment and prognosis. *Br J Dermatol.* 1992;126:275-82.
- Ikeda S, Suga Y, Ogawa H. Successful management of Hailey–Hailey disease with potent topical steroid ointment. *J Dermatol Sci.* 1993;5:205–11.

16. Galimberti RL, Kowalczyk AM, Bianchi O, Bonino MV, Garcia Garcia A. Chronic benign familial pemphigus. *Int J Dermatol.* 1988;27:495–500.
17. Marsch W, Stüttgen G. Generalized Hailey–Hailey disease. *Br J Dermatol.* 1978;99:553–60.
18. Defresne C, Adam C, De Marneffe K. Pemphigus chronique benin familial de Hailey–Hailey. *Dermatologica.* 1982;165:624–6.
19. Mayuzumi N, Ikeda S, Kawada H, Ogawa H. Effects of ultraviolet B irradiation, proinflammatory cytokines and raised extracellular calcium concentration on the expression of ATP2A2 and ATP2C1. *Br J Dermatol.* 2005;152:697–701.
20. Mayuzumi N, Ikeda S, Kawada H, Ogawa H. Effects of drugs and anticytokine antibodies on expression of ATP2A2 and ATP2C1 in cultured normal human keratinocytes. *Br J Dermatol.* 2005;152:920–4.
21. Leyden J, Marples R. Superinfection induced by antibiotics in familial benign chronic pemphigus. *Acta Derm Venereol (Stockh).* 1973;53:61–4.
22. Kellermayer R, Szigeti R, Keeling KM, Bedekovics T, Bedwell DM. Aminoglycosides as potential pharmacogenetic agents in the treatment of Hailey–Hailey disease. *J Invest Dermatol.* 2006;126:229–31.
23. Jitsukawa K, Ring J, Weyer U, Kimmig W, Radloff H. Topical cyclosporine in chronic benign familial pemphigus (Hailey–Hailey disease). *J Am Acad Dermatol.* 1992;27:625–6.
24. Cecchi R, Bartoli L, Brunetti L. Pemfigo familiare benigno (malattia di Hailey–Hailey) trattato con ciclosporina A orale. *G Ital Dermatol Venereol.* 1993;128:615–7.
25. Berth Jones J, Smith SG, GrahamBrown RAC. Benign familial chronic pemphigus (Hailey–Hailey disease) responds to cyclosporin. *Clin Expt Dermatol.* 1995;20:70–2.
26. Umar SA, Bhattacharjee P, Brodell RT. Treatment of Hailey–Hailey disease with tacrolimus ointment and clobetasol propionate foam. *J Drugs Dermatol.* 2004;3:200–3.
27. Rocha Paris F, Fidalgo A, Baptista J, Caldas LL, Ferreira A. Topical tacrolimus in Hailey–Hailey disease. *Int J Tissue React.* 2005;27:151–4.
28. Bianchi L, Chimenti MS, Giunta A. Treatment of Hailey–Hailey disease with topical calcitriol. *J Am Acad Dermatol.* 2004;51:475–6.
29. Rajpara SM, King CM. Hailey–Hailey disease responsive to topical calcitriol. *BrJ Dermatol.* 2005;152:816–7.
30. Hunt MJ, Salisbury EL, Painter DM, Lee S. Vesiculobullous Hailey–Hailey disease: successful treatment with oral retinoids. *Australas J Dermatol.* 1996;37:196–8.
31. Mashiko M, Akiyama M, Tsuji-Abe Y, Shimizu H. Bacterial infection-induced generalized Hailey–Hailey disease successfully treated by etretinate. *Clin Exp Dermatol.* 2006;31:57–9.
32. Berger EM, Galadari HI, Gottlieb AB. Successful treatment of Hailey–Hailey disease with acitretin. *J Drugs Dermatol.* 2007;6:734–6.
33. Norman R, Greenberg RG, Jackson JM. Case reports of etanercept in inflammatory dermatoses. *J Am Acad Dermatol.* 2006;4:139–42.
34. Lapiere JC, Hirsh A, Gordon KB, Cook B, Montalvo A. Botulinum toxin type A for the treatment of axillary Hailey–Hailey disease. *Dermatol Surg.* 2000;26:371–4.
35. Konrad H, Karamfilov T, Wollina U. Intracutaneous botulinum toxin A versus ablative therapy of Hailey–Hailey disease—a case report. *J Cosmet Laser Ther.* 2001;3:181–4.
36. Kang NG, Yoon TJ, Kim TH. Botulinum toxin type A as an effective adjuvant therapy for Hailey–Hailey disease. *Dermatol Surg.* 2002;28:543.

**Cite this article as:** Prateek K, Banwarilal MR, Chaudhary SS, Garg M. Hailey Hailey disease-a rare case report. *Int J Res Dermatol* 2016;2:36-9.