

Original Research Article

Randomized comparative study of combination of low dose oral isotretinoin with pulsed azithromycin and low dose oral isotretinoin alone in the management of moderate to severe acne

Rashmi Jindal, Samarjit Roy*, Akanksha Jain

Department of Dermatology, Himalayan Institute of Medical Sciences, Dehradun, Uttarakhand, India

Received: 09 November 2017

Revised: 02 January 2018

Accepted: 03 January 2018

***Correspondence:**

Dr. Samarjit Roy,

E-mail: roysamarjit2017@gmail.com

Copyright: © the author(s), publisher and licensee Medip Academy. This is an open-access article distributed under the terms of the Creative Commons Attribution Non-Commercial License, which permits unrestricted non-commercial use, distribution, and reproduction in any medium, provided the original work is properly cited.

ABSTRACT

Background: Oral isotretinoin and azithromycin are two important drugs used in management of acne. Their mode of action is different and thus theoretically the combination of these two should have a synergistic effect.

Methods: In this randomized comparative trial 100 patients were randomized into two groups. One received oral isotretinoin (0.3 mg/kg/day) alone and the other group received pulsed azithromycin (500 mg/day for three days in a week for 8 weeks) in addition to oral isotretinoin. Improvement in acne was noted as percentage improvement in mean acne score.

Results: No statistically significant difference was noted in the improvement in mean acne score of both the groups.

Conclusions: Addition of pulsed azithromycin to low dose oral isotretinoin does not offer a better treatment outcome in patients of moderate to severe acne.

Keywords: Isotretinoin, Azithromycin, Acne

INTRODUCTION

Acne is a common skin disease, which predominantly affects adolescents and young adults. Approximately 85% of teenagers develop acne and long-term sequel such as permanent scarring are associated with significant psychosocial and physical morbidity.¹ Oral retinoids and azithromycin are important drugs in the armamentarium for treatment of acne. Azithromycin acts by directly inhibiting the propionibacterium acnes (PA) by binding to the 50s subunit of bacterial ribosomes.² Retinoids on the other hand have an indirect inhibitory effect on PA by decreasing sebum production. Thus theoretically a combination of azithromycin and retinoid should have a synergistic effect. Further this combination might result in decreasing the dose of oral retinoid with fewer side

effects. There are some open label trials suggesting the beneficial effect of addition of azithromycin in a pulse dose to oral retinoid but randomized controlled trials for the same are lacking. This study has been planned to test the hypothesis, that addition of pulsed azithromycin to low dose oral isotretinoin improves the treatment outcome in patients with moderate to severe acne.

METHODS

This prospective randomized comparative study was carried out in the Department of Dermatology at Himalayan Institute of Medical Sciences, Dehradun. The study period was from February 2015 to August 2016. Patients with grade 3 (predominant pustules, nodules, abscesses) and 4 (mainly cysts, abscesses, widespread scarring) acne were included in the study, after obtaining

written informed consent. Ethical clearance was obtained from the institutes ethics committee. Patients were randomized into two groups using block randomization method. One group received oral isotretinoin (group A) and other received pulsed azithromycin in addition to oral isotretinoin (group B). Isotretinoin was given at a dose of 0.3 mg/kg. Azithromycin was given at a dose of 500 mg/day on three consecutive days every week for initial eight weeks. Fifty patients were taken in each group. Pregnant and lactating patients and those having other contraindications to use of isotretinoin or azithromycin were excluded. Baseline blood counts, liver function tests and lipid profiles were assessed in every patient. LFTs and lipid profile measurements were repeated every month during the treatment period. Response to treatment was assessed at monthly intervals using percentage improvement in global acne score using the global acne grading system (Table 1).³ Treatment was continued until complete clearance of lesions or 24 weeks, which ever was later. Those not responding to treatment ($\leq 50\%$ reduction in disease severity) protocol after 16 weeks were switched to standard dose isotretinoin and were not included in final analysis. Data analysis was done using SPSS software version 20.0 and Microsoft Excel software. Evaluation of response in two groups was done using independent sample t-test.

Table 1: The global acne grading system.³

Location	Factor
Forehead	2
Right cheek	2
Left cheek	2
Nose	1
Chin	1
Chest and upperback	3

Each type of lesion is given a value depending on severity; No lesions=0, comedones=1, papules=2, pustules=3, nodules=4; The score for each area (local score) is calculated as local score= Factor \times grade (0-4); Global score is the sum of local scores.

RESULTS

There were 50 patients in each group. Out of these 8 patients in group A and 10 patients in group B were either lost to follow up or were shifted to high dose isotretinoin because they failed to respond to therapy even after 16 weeks (Figure 1). Thus for final analysis there were 42 patients in group A and 40 patients in group B. The demographic data of patients in both groups including age, sex and initial mean acne score is depicted in Table 2. 81% patients in group A and 82.5% patients in group B had more than 80% reduction in their mean acne score at the end of study period.

Evaluation of response as mean acne score reduction at each follow up visit in the two groups did not show any statistically significant difference (Table 3) using independent sample t-test. Thus addition of pulsed azithromycin didn't have any statistically significant

improvement in treatment outcome in our study. Side effect profile in both the treatment groups was comparable (Table 4). Cheilitis was reported by 88% patients in-group A and 87.5% patients in group B. Acute flares were seen in 21.4% patients in group A and 10% patients in group B. Relapse rates could not be calculated as majority of patients were lost to follow up.

Table 2: Demographic and clinical profile of patients.

S. No.	Variable	Treatment group A	Treatment group B
1.	Total number of patients	42	40
2.	Mean age (years)	19.35 \pm 3.34	19.72 \pm 2.97
3.	Male (%)	25 (59.5%)	27 (67.5%)
4.	Female (%)	17 (40.5%)	13 (32.5%)
5.	Mean initial acne load	23.36 \pm 4.74	23.80 \pm 4.26

Table 3: Response evaluation as mean acne score reduction at each follow-up visit.

Time duration (weeks)	Group A Mean acne score	Group B Mean acne score	P value
0	23.36	23.80	-
4	18.79	18.98	0.319
8	14.05	14.45	0.987
12	9.40	10.13	0.858
16	6.71	6.95	0.941
20	4.31	4.73	0.671
24	3.07	3.13	0.964

P<0.05 taken as significant.

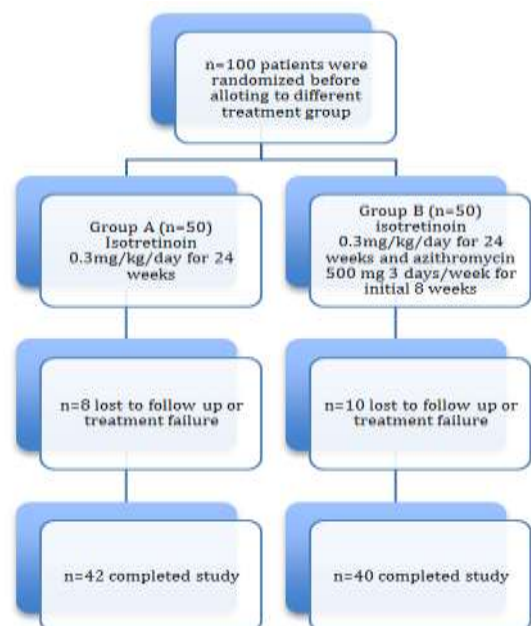


Figure 1: Flowchart of patients participating in the study.

Table 4: Frequency of side effects.

S. No.	Side effects	Group A (n=42) (%)	Group B (n=40) (%)
1.	Cheilitis	37 (88.1)	85 (87.5)
2.	Xerosis	7 (16.7)	3 (7.5)
3.	Facial dermatitis	4 (9.5)	8 (20)
4.	Acute flares	9 (21.4)	4 (10)
5.	Deranged liver function test	2 (4.8)	0
6.	Deranged lipid profile	1 (2.4)	1 (2.5)

DISCUSSION

Isotretinoin has been in use for treatment of acne for more than thirty years. Traditionally it was used for severe nodulo-cystic acne in dose of 1-2 mg/kg/day.⁴⁻⁷ In the recent years however a number of investigators have found it to be useful even in relatively low doses ranging from 0.3 to 0.5 mg/kg/day.⁸⁻¹² It has been seen that there is dose dependent decrease in sebum production with oral isotretinoin.¹³ Though isotretinoin is effective in acne even in low doses but there are significantly higher chances of relapses and need of retreatment. The advocates of low doses state that decreasing the dose also decreases the side effects. There are also studies to find out the synergistic effect of oral azithromycin in addition to low dose isotretinoin. De and Kanwar in their study of 62 patients treated with low dose oral isotretinoin (0.3 mg/kg/d) and pulsed oral azithromycin (500 mg/day for 3 days/2 weeks) reported complete clearance in 93.9% patients.¹⁴ In another study by Hasibur and Meraj 82 teenagers with moderate to severe acne received a combination of low dose isotretinoin (0.3 mg/kg/day) and pulsed azithromycin (500 mg/day for 3 days/week for 1 month).¹⁵ 97.56% patients had complete clearance and only 2.43% relapsed in the six month follow up period. Thus a combination of low dose isotretinoin and pulsed azithromycin was found to be effective in moderate to severe acne.

In our study also both the treatment groups showed significant improvement in mean acne scores at follow up visits. More than eighty percent reduction in mean acne score was seen in 81% patients in group A and 82.5% patients in group B. However on comparing there was no statistical difference in the treatment outcome ($p > 0.05$). Side effects profile in the two groups was also comparable. Thus in our study no beneficial effect of addition of oral azithromycin to oral isotretinoin was seen. The cost of therapy though was increased in Group A.

CONCLUSION

Addition of pulsed azithromycin to low dose isotretinoin increases the cost of therapy but doesn't improve the

treatment outcome. Thus addition of azithromycin to all cases receiving oral isotretinoin seems unjustified and it can be decided on a case-to-case basis. Probably patients presenting with more number of pustules will be benefited. However, more studies with higher number of patients are required to confirm this finding.

Limitations

Small sample size is the main limitation of our study. Further absence of good follow-up prevented us from calculating the relapse rates.

Funding: No funding sources

Conflict of interest: None declared

Ethical approval: The study was approved by the institutional ethics committee

REFERENCES

- Bhate K, Williams HC. Epidemiology of acne vulgaris. Br J Dermatol. 2013;168:474-85.
- Aenglein AL, Pathy AL, Schlosser BJ, Alikhan A, Baldwin HE, Berson DS, et al. Guidelines of care for the management of acne vulgaris. J Am Acad Dermatol. 2016;74:945-73.
- Doshi A, Zaheer A, Stiller MJ. A comparison of current acne grading systems and proposal of a novel system. Int J Dermatol. 1997;36:416-8.
- Akman A, Durusoy C, Senturk M, Koc CK, Soyuturk D, Alposy E. Treatment of acne with intermittent and conventional isotretinoin: A randomised controlled multicenter study. Arch Dermatol Res. 2007;299:467-73.
- Cunliffe WJ, van de Kerkhof PC, Caputo R, Cavicchini S, Cooper A, Fyrand OL, et al. Roaccutane treatment guidelines: results of an international survey. Dermatology. 1997;194:351-7.
- Peck GL, Olsen TG, Yoder FW, Downing DT, Pandya M, et al. Prolonged remissions of cystic and conglobate acne with 13-cis-retinoic acid. N Engl J Med. 1979;300:329-33.
- Farrell LN, Strauss JS, Stranieri AM. The treatment of severe cystic acne with 13-cis-retinoic acid. Evaluation of sebum production and the clinical response in a multiple-dose trial. J Am Acad Dermatol. 1980;3:602-11.
- Goulden V, Clark SM, Cunliffe WJ. Post adolescent acne: A review of clinical features. Br J Dermatol. 1997;136:66-70.
- Hermes B, Praetel C, Henz BM. Medium dose isotretinoin for the treatment of acne. J Eur Acad Dermatol Venereol. 1998;11:117-21.
- Geissler SE, Michelsen S, Plewig G. Very low dose isotretinoin is effective in controlling seborrhoea. J Dtsch Dermatol Ges. 2003;1:952-8.
- Amichai B. Long term mini doses of isotretinoin in the treatment of relapsing acne. J Dermatol. 2003;30:572.

12. Sardana K, Garg VK, Sehgal VN, Mahajan S, Bhushan P. Efficacy of fixed low-dose isotretinoin (20 mg, alternate days) with topical clindamycin gel in moderately severe acne vulgaris. *J Eur Acad Dermatol Venereol.* 2009;23:556-60.
13. Jones DH, King K, Miller AJ, Cunliffe WJ. A dose-response study of 13-cis-retinoic acid in acne vulgaris. *Br J Dermatol.* 1983;108:333-43.
14. De D, Kanwar AJ. Combination of Low-Dose Isotretinoin and Pulsed Oral Azithromycin in the Management of Moderate to Severe Acne. A Preliminary Open-Label, Prospective, Non-Comparative, Single-Centre Study. *Clin Drug Investig.* 2011;31:599-604.
15. Hasibur MR, Meraj Z. Combination of low-dose isotretinoin and pulsed oral azithromycin for maximizing efficacy of acne treatment. *Mymensingh Med J.* 2013;22:42-8.

Cite this article as: Jindal R, Roy S, Jain A. Randomized comparative study of combination of low dose oral isotretinoin with pulsed azithromycin and low dose oral isotretinoin alone in the management of moderate to severe acne. *Int J Res Dermatol* 2018;4:58-61.