

## Original Research Article

# Platelet rich plasma in treatment of chronic non healing ulcers: a study of ten cases

Nitika S. Deshmukh, Vasudha A. Belgaumkar\*, Sunil N. Tolat, R. B. Chavan, Chirag J. Vamja

Department of Dermatology, B.J. Medical College, Pune, Maharashtra, India

**Received:** 06 November 2017

**Accepted:** 13 December 2017

### \*Correspondence:

Dr. Vasudha A. Belgaumkar,

E-mail: [doc\\_vasudha@yahoo.co.in](mailto:doc_vasudha@yahoo.co.in)

**Copyright:** © the author(s), publisher and licensee Medip Academy. This is an open-access article distributed under the terms of the Creative Commons Attribution Non-Commercial License, which permits unrestricted non-commercial use, distribution, and reproduction in any medium, provided the original work is properly cited.

## ABSTRACT

**Background:** Platelet rich plasma (PRP) helps tissue re-modulation by its growth factors (GFs)– platelet derived growth factor (PDGF), transforming growth factor (TGF- $\beta$ ), epidermal growth factor (EGF), fibroblast growth factor (FGF-2), insulin-like growth factor (IGF). These GFs aid healing by attracting undifferentiated stem cells into newly formed matrix and triggering cell division; by promoting capillary growth and by attracting macrophages to improve tissue healing and regeneration. The aims and objectives of the study were to assess reduction in wound size of chronic non-healing ulcers by autologous platelet rich plasma and to evaluate the safety of autologous platelet rich plasma in treatment of chronic non healing ulcers.

**Methods:** This was an experimental study conducted on ten patients of chronic non-healing ulcers of varied etiology. Autologous PRP was freshly prepared using 10 ml of patient's own blood by differential centrifugation process and injected at the margins and base of each ulcer. Four such sittings were administered at weekly intervals for four weeks with a post-treatment follow-up period of one month. Total duration of our study was 8 weeks. Objective assessment of ulcer size was done using centimetre scale and documented by digital photographs.

**Results:** While 40% of chronic ulcers healed completely, the remaining 60% cases showed signs of healing at the end of 8 weeks. Mean improvement in ulcer size was 69.38% over a period of 8 weeks. No side effect was encountered in any of our cases.

**Conclusions:** Platelet rich plasma hastened the healing process of chronic non-healing ulcers. Being autologous, it has rare chances of hypersensitivity reactions.

**Keywords:** PRP, Chronic non-healing ulcers

## INTRODUCTION

Wound healing is a complex process mediated by interacting molecular signals involving mediators and cellular events. Platelets play two important roles in wound healing– hemostasis and initiation of wound healing. After platelet activation and clot formation, growth factors are released from alpha granules located in thrombocyte cell membrane. Growth factors work as biological mediators to promote cellular activity by binding to specific cell surface receptors.<sup>1,2</sup>

Autologous growth factors from concentrated platelet suspension have been used to treat chronic wounds for more than 20 years.<sup>1</sup> However, there is still paucity of research to establish their effectiveness. A few studies with small sample sizes showed promising results with healing rates ranging from 37.5% to 66%.<sup>2-4</sup>

Autologous platelet rich plasma [PRP] is concentration of platelets suspended in plasma, extracted after centrifuging patient's own blood. Platelets contain growth factor releasing granules which stimulate tissue-

healing and collagen modulation. Growth factors like transforming growth factor beta, fibroblast growth factors, platelet derived growth factors, vitronectin, vasculo-endothelial growth factors help in tissue remodulation. This study, attempts to evaluate the role of platelet rich plasma in the healing process in chronic non-healing ulcers.

## METHODS

This study was conducted in Byramjee Jeejeebhoy Government Medical College and Sassoon General Hospitals, Pune over a period of six months (December 2013 to May 2014). It was an experimental pilot study conducted on ten patients of chronic non-healing ulcers with varied etiology and duration (Table 2).

### Procedure to prepare autologous platelet rich plasma

The double spin differential centrifugation process was used for preparation of PRP.

10cc of patient's own blood was withdrawn using a sterile pair of gloves, a sterile scalp vein set, sterile needle and a sterile syringe. This blood was then transferred to two vacutainers with prefilled sodium citrate [5 ml each]. These test tubes were centrifuged at 800 rpm for 8 min [slow spin] followed by a heavy spin at 1200 rpm for 12 min after separation of the supernatant plasma. The entire process was performed under aseptic precautions using a digital centrifuge machine at room temperature. After the double centrifuge, a small platelet rich pellet was obtained at the bottom of the tube. The upper two thirds of the plasma was discarded and the lower one third was re-suspended with the pellet to prepare platelet rich plasma with platelet counts 3-4 folds of baseline. This freshly prepared PRP was injected at the ulcer margins and ulcer base using a 30G needle.

Each patient was administered four such sessions at weekly intervals and followed up for one month thereafter. Objective assessment of ulcer size was performed using centimeter scale. Digital photographs were recorded before and after each PRP session and during follow up period.

### Subject selection

#### Inclusion criteria

Inclusion criteria were males and non-pregnant females (above 10 years age) attending the Dermatology OPD with non-healing chronic ulcers showing no signs of healing (reduction in size, formation of granulation tissue, epithelization); written informed consent; wounds had to be free of necrosis; no previous PRP treatments.

#### Exclusion criteria

Exclusion criteria were critical thrombocytopenias (low platelet count); ulcers with evident clinical signs of

infection or profuse exudation; hypofibrinogenemia, severe hypoproteinemia and anemia; haemodynamic instability; sepsis; acute and chronic infections; autoimmune connective tissue disorders; renal failure, liver failure, malignancies; anti-coagulant therapy; keloidal tendency; recurrent or recent herpes, seropositive patients; pregnancy; unwilling patients.

### Data analysis

We analyzed our data for following outcomes:

1. Primary outcome measure was the number of ulcers showing complete healing after PRP therapy.
2. Secondary outcome measure was reduction in ulcer size after PRP therapy.

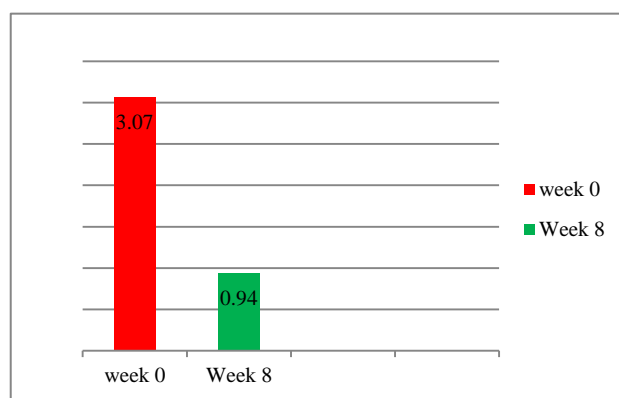
Data were entered in a structured format in Microsoft Excel and cross-verified.

## RESULTS

**Table 1: Demographic data of patients in the study.**

	Number of patients	Percentage (%)
<b>Females</b>	4	40
<b>Males</b>	6	60
<b>Total</b>	10	

Ten patients with chronic non-healing ulcers due to varied etiology were enrolled in the study, comprising 4 (40%) females and 6 (60%) males with mean age of 36.5 years (Table 1). Of these, 5 (50%) had non-healing trophic ulcers due to leprosy associated sensory-motor deficit while 2 patients (20%) were of venous origin. One (10%) patient each had trophic ulcer associated with spina bifida, diabetes mellitus and trauma. Mean ulcer duration was 9.1 months (Table 2).



**Figure 1: Reduction in size of ulcers at end of follow up period (8 weeks).**

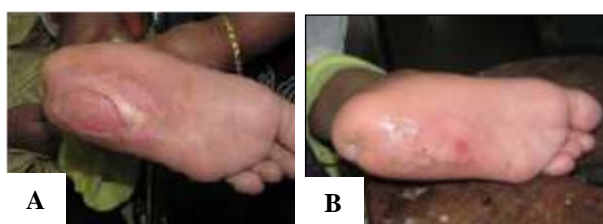After a follow up period of 8 weeks, 40% of ulcers had healed completely and remaining 60% showed reduction in size with signs of healing (peripheral re-epithelisation) at the end of 8 weeks (Figure 1-3, Table 2).

**Table 2: Various types of ulcers with comparative ulcer size before and after PRP therapy.**

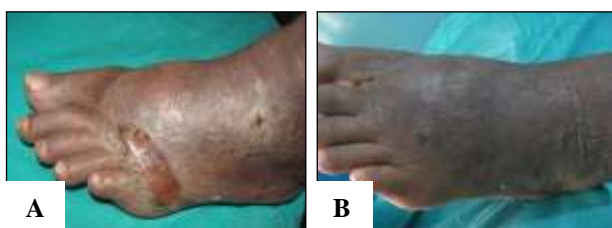
S. No	Cause of ulcer	Duration (Months)	Pre- t/t ulcer size Week 0 (cms)	Ulcer size after 8 wks (cms)
1	Venous	16	2	0
2	Trophic (spina bifida)	8	4	0
3	Trophic (leprosy)	6	5	2
4	Diabetic	12	3	1
5	Venous	9	3.5	2
6	Trophic (leprosy)	5	4.5	1.7
7	Trophic (leprosy)	8	1	0
8	Traumatic	3	3	1.5
9	Trophic (leprosy)	14	2.7	1.2
10	Trophic (leprosy)	10	2	0
<b>Total=10</b>	Mean	9.1	3.07	0.94

Mean improvement in ulcer size was 69.38%. Hence, the results were found to be statistically significant.

No patient experienced any side effects due to the procedure.



**Figure 2: A=Trophic ulcer in patient of spina bifida; B=Healed ulcer after 8 weeks of platelet rich plasma in trophic ulcer.**



**Figure 3: A=Venous ulcer with features of stasis; B=Healed ulcer after 8 weeks of platelet rich plasma.**

## DISCUSSION

Chronic wounds pose a therapeutic challenge, particularly in developing countries with resource constraints. Response to conventional therapies such as dressings, surgical debridement and skin grafting may be unsatisfactory. PRP is a potential wound healing treatment attributable to its constituents like fibrin and growth factors. We evaluated the response of non-healing ulcers with varied etiology to autologous platelet rich plasma. While 40% of chronic ulcers (two cases of leprosy and one each associated with venous

insufficiency and spina bifida) healed completely, the average ulcer size showed a drastic reduction of 69.38% over a period of 8 weeks.

Recently, Cochrane review concluded that although PRP may improve the healing of diabetic foot ulcers, there is inadequate evidence to support its influence on other chronic wounds.<sup>1</sup> Frykberg et al used PRP gel on 49 patients with 65 non-healing ulcers of varied etiology.<sup>2</sup> It was concluded that 63 of 65 ulcers responded well with reduction in area (mean 43.1%), volume (mean 56.1%) and undermining of the ulcers within a mean of 2.8 weeks with 3.2 treatment sessions.<sup>2</sup>

According a study conducted by Sachidanand et al, mean percentage of reduction in volume and area of chronic ulcers was 95% and 94.14% respectively with a mean PRP treatment duration of 5.1 weeks.<sup>3</sup>

In a study conducted by Suthar et al, all the patients showed healing of the wound/ulcer with more than 90% reduction in wound size observed in 17 (70.83%), followed by 80–90% reduction in 3 (12.5%) patients over the 24 weeks follow-up post-PRP application.<sup>4</sup> Meantime duration to ulcer healing was 8.2 weeks.<sup>4</sup>

Suresh et al demonstrated good results within 6 weeks in a non-healing diabetic foot ulcer.<sup>5</sup> We also succeeded in achieving complete re-epithelisation in a single case of diabetic ulcer within 8 weeks study period.

In our study, 6 patients (60%) had trophic ulcers due to leprosy. These ulcers also showed rapid reduction in ulcer size during this 8 week period. Amongst these 6 patients, 2 (33.3%) patients showed complete resolution with PRP while 4 (66.6%) patients had reduction in size of ulcers at end of eight weeks. According to a study conducted by Anandan et al, 46 patients of trophic ulcers due to leprosy were evaluated for efficacy of PRP.<sup>6</sup> According to their results, 92% showed complete healing, 4 patients (8%) had marked reduction in wound size with partial re-epithelization while 88% had complete healing

after the fourth sitting. Mean time to ulcer healing was approximately 4.38 weeks.

The strength of our study is that we evaluated the effect of PRP on chronic ulcers with a wide range of etiology. Nevertheless, the rate and magnitude of response could not be co-related with the cause due to small sample size.

## CONCLUSION

Autologous platelet rich plasma is beneficial in treatment of non-healing chronic ulcers irrespective of the cause and can be used as a monotherapy in chronic ulcers. Being autologous, it is devoid of hypersensitivity reactions.

## ACKNOWLEDGEMENTS

Research reported in this publication is supported by the Fogarty International Center of the US National Institutes of Health (grant #D43TW00957). The content is solely the responsibility of the authors and does not represent the official views of the National Institutes of Health.

*Funding: No funding sources*

*Conflict of interest: None declared*

*Ethical approval: The study was approved by the institutional ethics committee*

## REFERENCES

1. Autologous platelet-rich plasma for treating chronic wounds. Cochrane Database of Systematic Reviews

2016(5). Art. No.: CD006899. Available at [www.cochrane.org/CD006899/WOUNDS\\_autologous-platelet-rich-plasma-chronic-wounds](http://www.cochrane.org/CD006899/WOUNDS_autologous-platelet-rich-plasma-chronic-wounds). Accessed on 18 October 2017.

2. Frykberg RG, Driver VR, Carman D, Lucero B. Chronic Wounds Treated With a Physiologically Relevant Concentration of Platelet - rich Plasma Gel : A Prospective Case Series. *Ostomy. Wound. Management.* 2010;56:1–15.
3. Sacchidanand S, Shwetha S, Leelavathy B, Hurkudli SD. Autologous Platelet Rich Plasma in Chronic Venous Ulcers : Study of 17 Cases. *J Cutan Aesthet Surg.* 2013;6(2):97–9.
4. Suthar M, Gupta S, Bukhari S, Ponemone V. Treatment of chronic non-healing ulcers using autologous platelet rich plasma : a case series. *J. Biomed Sci.* 2017;16:1–10.
5. Suresh DH, Suryanarayan S, Sarvajnamurthy, Sarvajnamurthy S, Puvvadi S. Treatment of a Non - Healing Diabetic Foot Ulcer With Platelet - Rich Plasma. *J Cutaneous Aesthetic Surg.* 2014;7(4):229–31.
6. Anandan V, Jameelaz A, Saraswathy P, Sarankumar S. Platelet rich plasma: efficacy in treating trophic ulcers due to leprosy. *J Clin Diagnos Res.* 2016;10(10):6-9.

**Cite this article as:** Deshmukh NS, Belgaumkar VA, Tolat SN, Chavan RB, Vamja CJ. Platelet rich plasma in treatment of chronic non healing ulcers: a study of ten cases. *Int J Res Dermatol* 2018;4:50-3.