International Journal of Research in Dermatology
Mainkar A et al. Int J Res Dermatol. 2027 Jan;13(1):xxx-xxx
https://www.ijord.com

DOI: https://dx.doi.org/10.18203/issn.2455-4529.IntJResDermatol20264526

Original Research Article

Efficacy evaluation of aloe vera extract in topical gel cream for supporting dermal regeneration and skin barrier repair following chemical and mechanical damage

Avani Mainkar[1]*, Mansi Shirodkar[1], Shraddha Kumbhar[1], Pranjali Dhawal[2], Kedar Vaze[1], Maheshvari Patel[3], Nayan Patel[3], Apeksha M. Patel[3]

[1]Keva – S. H. Kelkar and Company Limited, Mumbai, Maharashtra, India
[2]FAFAI, Research and Development, Navi Mumbai, Maharashtra, India
[3]NovoBliss Research Private Limited, Silver Radiance-4, Gota, Ahmedabad, Gujarat, India

Received: 28 October 2026
Revised: 17 November 2026
Accepted: 20 November 2026

***Correspondence:**
Dr. Avani Mainkar,
E-mail: avani.mainkar@keva.co.in

Copyright: © the author(s), publisher and licensee Medip Academy. This is an open-access article distributed under the terms of the Creative Commons Attribution Non-Commercial License, which permits unrestricted non-commercial use, distribution, and reproduction in any medium, provided the original work is properly cited.

ABSTRACT

Background: The objective of the study was to evaluate the safety and wound healing efficacy of gel cream containing 5% aloe vera extract (AVE) for its ability to restore skin barrier function following chemical and mechanical superficial damage.
Methods: In this prospective, interventional, evaluator-blinded, in-use tolerability study 17 healthy adult female subjects were enrolled, with 16 completing the study. Controlled skin barrier disruption was induced on forearm sites using 1% sodium lauryl sulphate (SLS) and tape-stripping. The test product was applied for 7 days (twice) on these wounded sites. Assessments included skin hydration, transepidermal water loss (TEWL), and skin surface topography at baseline and post-application time points. The study was registered under Clinical Trials Registry-India (CTRI) with identifier CTRI/2024/02/062644 (14 February 2024).
Results: After 7 days, the test product significantly improved skin barrier function and hydration at both sites. TEWL was reduced by 44.89% and 51.42%, while skin hydration was improved by 188.06% and 138.83% after 7 days of test product usage at SLS- treated site and tape-stripped sites, respectively ($p<0.0001$). Significant improvements were also observed in roughness, scaliness, wrinkle scores, and skin smoothness at both damaged sites ($p<0.0001$).
Conclusions: The cream containing 5% AVE demonstrated significant efficacy in promoting skin repair and restoring the epidermal barrier, resulting in enhanced skin hydration, reduced transepidermal water loss, and alleviated irritation contributing to accelerated healing of minor cosmetic wounds and improved skin health.

Keywords: Wound healing, Skin damage, Hydration, Mechanical skin damage, Chemical skin damage

INTRODUCTION

A wound is described as a defect or a break in the skin, resulting from physical, thermal or physiological damage.[1] Various medical and cosmetic interventions, such as chemical peels, depilation, mechanical exfoliation, micro-needling, and laser treatments, result in disruption to skin barrier causing minor injuries called cosmetic wounds.[2] Effective post-procedural care is essential to ensure optimal healing and restore the skin's barrier function.

Minor disruptions to the skin barrier can result in temporary functional impairment, marked by increased transepidermal water loss (TEWL), dryness and reduced epidermal integrity.[3] Studies have demonstrated that maintaining a moist environment greatly facilitates the

healing process when compared to dry conditions, highlighting the essential role of hydration in effective skin repair.[4,5] The damage that occurs due to barrier disruption can delay re-epithelialization and tissue regeneration. Therefore, after skin injury, it is essential to re-establish barrier function, prevent moisture loss, and sustain adequate skin hydration to support efficient and timely healing.[6]

In preclinical research, the technique of tape-stripping is used to disrupt the stratum corneum mechanically by peeling off superficial layers of corneocytes, which corresponds to the effects of superficial abrasion and post-depilation. In addition, skin disruption may be achieved by application of sodium lauryl sulfate (SLS), an irritant that disrupts intercell lipid organization, thereby compromising the skin barrier and increasing its permeability.[7,8] These models are well established for evaluating epidermal barrier recovery and the efficacy of topical interventions aimed at restoring skin function.

While a variety of synthetic wound healing products, such as petroleum-based ointments and topical antiseptic creams are commonly used for post cosmetic or salon procedures care, their use is often limited by side effects such as, breakouts on oily or acne prone skin.[9] This has driven increasing interest in alternative therapies derived from natural and plant-based sources, which may offer effective wound healing with improved safety and biocompatibility profiles.[10,11] Topical treatments that enhance hydration and accelerate re-epithelialization are key to managing such post-procedural skin disruptions.

Aloe vera is used for skin conditions such as burns, psoriasis, cold sores, itching and inflammation.[12] It plays a significant role in wound healing by fibroblast proliferation, collagen synthesis, and angiogenesis. Additionally, its strong moisturizing and soothing properties help maintain skin hydration and reduce dryness.[13-15] Aloe vera gel is also commonly used in salons as a post-treatment regimen following skincare procedures such as hair removal and chemical peels.[16] Despite its widespread use, particularly after depilatory treatments, robust preclinical or clinical data validating the benefits of aloe vera remain limited. Moreover, most existing wound-healing studies involving aloe vera are focused on open or traumatic wounds, animal models, or direct application of crude gel preparations.[12] These limitations highlight the need for controlled studies to establish the role of aloe vera in skin repair and barrier recovery following cosmetic procedures.

Aloe vera gel is also commonly used after cosmetic procedures such as hair removal and chemical peels.[16] However, robust clinical evidence supporting its use following cosmetic procedures remains limited, as existing wound-healing studies have largely focused on open or traumatic wounds, animal models, or crude gel preparations.[12] Therefore, controlled studies are needed to establish the role of aloe vera in skin repair and barrier recovery following cosmetic procedures.

An *in-vitro* study conducted on aloe vera extract (AVE) has previously proven its extensive wound healing and anti-inflammatory activity in skin and gingival primary cells.[18] In current study, a gel cream formulation containing AVE, was developed and evaluated for its wound healing properties. It used a model that mimics skin damage caused by depilatory treatments or chemical peels, induced by tape-stripping and SLS patch respectively. Establishing such evidence may support its continued use in cosmetic practice and potentially lead to the development of standardized, evidence-based post-procedure skincare regimens.

METHODS

Ethical conduct of the study

The study was conducted in accordance with the declaration of Helsinki, ICH-GCP guidelines, and ICMR ethical principles.

The study protocol was approved by the the ACEAS independent ethics committee on 10 February 2024. And registered with the Clinical Trials Registry-India (CTRI) (CTRI/2024/02/062644) on 14 February 2024.

Written informed consent was obtained from all participants after providing information regarding the study procedures, potential risks and benefits, confidentiality, and the right to withdraw at any time without consequences. Participant safety, rights, and well-being were prioritized throughout the study, and compensation was provided at scheduled visits in accordance with applicable ethical and regulatory requirements.

Study design

This study was conducted to assess the safety and efficacy of topical cream in wound healing among healthy adult female at Novobliss Research Private Ltd (CRO), Ahmedabad. A total of 17 participants were enrolled, 16 completed the 7-day study involving five clinical visits.

Subjects were enrolled following informed consent and screened as per inclusion/exclusion criteria. Skin damage was induced using 24-hours application of a 1% SLS and 24 tape-stripping cycle across eight sites. TEWL was assessed using TEWAMeter® TM Hex (courage+khazaka electronic gmbh, cologne, Germany, version-1.16.8), skin hydration was assessed using corneometer® CM 825, and surface topography was assessed using visioscan 20 Plus®. Assessments were conducted on day 0 - (before wound infliction), on day 01 (post wound infliction, and 12 hours post-product usage), and on days 02, 03, and 07.

The test product evaluated in the study was a topical cream formulation containing 5% AVE. The formulation comprised of water, aloe barbadensis leaf juice, glycerin, caprylic/capric triglycerides, polyacrylate-13 (and) polyisobutene (and) polysorbate 20, isopropyl myristate, phenoxyethanol and ethylhexylglycerin, olive oil, butylated hydroxy toluene, perfume, disodium EDTA, and colour. The cream was designed for topical application, to be applied directly to the designated wound site until fully absorbed. The test product, AloeHeal®Gold (AVE) was manufactured by Keva - S H Kelkar and Company Limited.

Skin damage creation and site marking[7]

The study involved inducing superficial wounds using two standardized methods: 1% w/v SLS application to simulate chemically induced irritation and 24-times tape-stripping to mimic mechanical barrier disruption. A 1% w/v SLS solution was applied to the forearm using the patch application method for duration of 24 hours. Tape-stripping entails the repetitive application and removal of adhesive tape (3M, transpore™) on the skin, effectively peeling away layers of the stratum corneum and disrupting the skin barrier. A total of eight test areas (4 cm² each) were marked on each subject's volar forearm, located between the wrist and antecubital fossa. Sites were preassigned to represent SLS-treated control, SLS-treated product, tape-stripped control, and tape-stripped product sites, ensuring intra-subject comparison and consistency across subjects. This led to a total of 136 evaluable sites representing data from 17 subjects as shown in Figure 1. All test sites were gently cleansed with water and patted dry using a non-abrasive towel before product application.

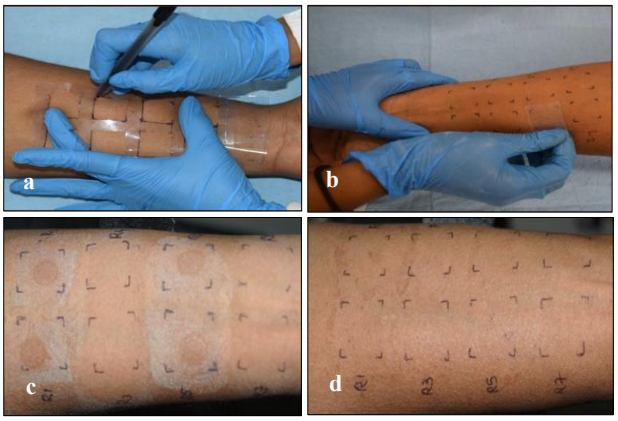

Figure 1: (a) Site marking, (b) tape stripping, (c) wound creation, and (d) wound healing.

Eligibility criteria

Participants who agreed to follow study instructions, avoid using other topical products on the application site, and attend all scheduled visits were included in the study. Subjects were excluded if pregnant based on self-reported urine pregnancy test, lactating, planning pregnancy, had known allergies to cosmetic or dermatological products, ongoing participation in another study, significant medical conditions, or were on medications deemed unsuitable by the investigator.

Study population

A total of 17 healthy female subjects**,** aged 21 to 53 years**,** were enrolled in the study. All participants were non-pregnant and had no history of adverse skin conditions.

Study procedures and visits

Participants attended five scheduled visits. Subjects were advised not to use any skincare products on the application sites during the study. On visit 1 (day-01), screening, enrollment, site demarcation, instrumental assessments before patch application (day-01), and a 24-hour patch application were performed. Visit 2 (day 01) included patch removal, 24-time tape-stripping, irritation scoring, instrumental evaluations at baseline, site photography, product application, and post-usage assessments at 12 hours**.** Visits 3 and 4 (days 02 and 03) involved irritation scoring and instrumental evaluations. Visit 5 (day-07) included final assessments and site photography (Figure 2).

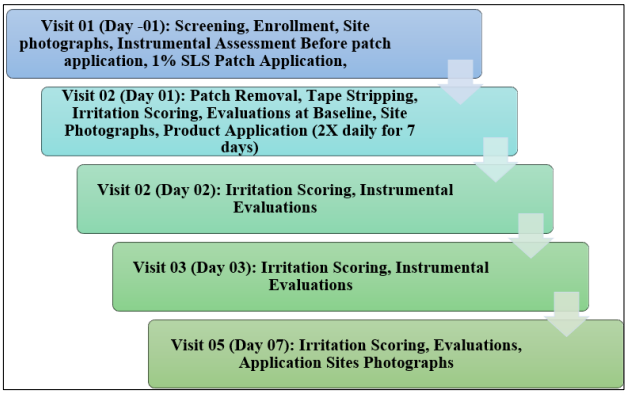

Figure 2: Process flow.

Statistical analysis

Continuous variables were described by descriptive statistics (N, Mean, SD, Median, Minimum and Maximum). Categorical variables were expressed by frequency and percentage along with the graphical presentation whenever required.

For continuous variables, data was compared from baseline to post-usage using paired t-test. Any AE was summarized with a number and the percentage.

The statistical analysis was done by using international business machines (IBM) statistical package for the social sciences (SPSS) software (version: 29.0.1.0(171)) and Excel software with a 5% level of significance. A

withdrawn subject was not included in the statistical analysis.

Sample size calculation

The sample size calculation was based on the primary endpoint of skin barrier function, assessed by TEWL, expressed in g/m²/hour. The null hypothesis posits no mean change in TEWL after treatment, while the alternative hypothesis suggests a statistically significant change, indicating an effect on skin barrier function.

Based on reference data and study assumptions, the mean (SD) TEWL at baseline is estimated at 6.6 (2.4), and at day 4, post-treatment, at 7.6 (1.2).

Assuming a paired design, the calculated effect size (Cohen's d) is 0.8333. Using a two-sided paired t-test with 85% power and a significance level (α) of 0.05, the required sample size was estimated at 14.97, which was rounded up to 15 participants to complete the study.

To account for an estimated 10% dropout rate, the total number of subjects to be enrolled is 16.67 which was rounded up to 17 subjects.

This sample size was considered sufficient to detect a clinically and statistically meaningful change in TEWL.[19]

RESULTS

Demographics and other baseline characteristics

The study comprised a total of 17 adult females, with a mean age of 39 years. Table 1 presents a detailed summary of the participants' demographic characteristics, including age, body weight, and height.

Table 1: Subject demographics and baseline characteristics.

Parameter	Statistic	Total enrolled subjects (N=27)
Gender, N (%)	Female	17 (100%)
Age (year)	Mean (SD)	39(10.19)
	Median	39.00
	[Min, max]	[21.00, 53.00]
Weight (kg)	Mean (SD)	64.94(11.45)
	Median	65.00
	[Min, max]	[50.00, 90.00]
Height (cm)	Mean (SD)	158.65(12.94)
	Median	153.00
	[Min, max]	[142.00, 182.00]

SD=standard deviation

One subject discontinued from study due to missed visit. Figure 3 represents a summary of subject's disposition.

Primary efficacy end-points

Assessment of TEWL using TEWAMeter® TM Hex

After 24-hours SLS exposure, TEWL increased by 17.65% ($p<0.05$) and 26.21% ($p<0.001$) at control site and at AVE site respectively, indicating disturbed skin barrier function. On SLS treated control site, TEWL reduced by 6.50% at 12 hours, and then incremental increase by 3.54%, 1.05% and 8.17% on Day-02, 03 and 07, respectively. At the SLS-treated AVE site, after product application TEWL continued to decrease by 11.45%, 26.92%, 35.34% and 44.89% by day-01, 02, 03 and 07 ($p<0.05$) as compared to the baseline. Compared to the control, test product treated site reflected a 2.01-fold greater reduction on day-07 ($p<0.0001$).

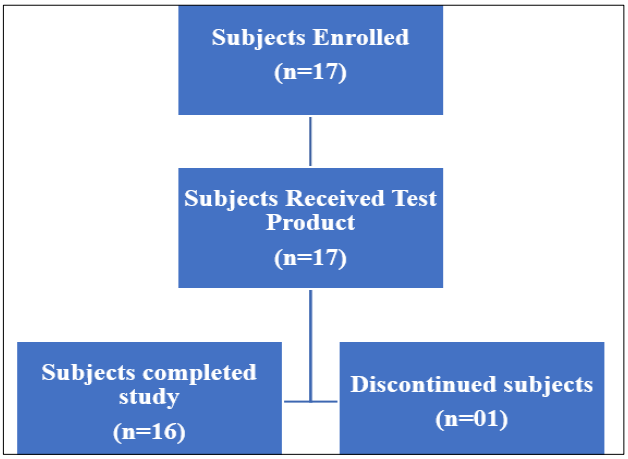

Figure 3: Subject disposition details.

Following tape-stripping, both sites showed a significant increase in TEWL. The TEWL at control site increased by 13.74% ($p<0.05$) whereas the product site showed increased by 33.30% ($p<0.01$) indicating a compromised skin barrier. At the tape-stripped-control site, TEWL reduced by 3.79% at 12 hours on day-01, and then increased to 6.28%, 9.92%, and 15.97% by day-02, 03 and 07, respectively. For the tape-stripped-product site TEWL decreased by 16.16%, 30.54%, 39.47% and 51.42% on day-01, 02, 03 and 07, respectively. Compared to the tape-stripped-control site, the test product site reflected a 2.27-fold greater reduction on day-07 ($p<0.0001$) (Figure 4).

Assessment of skin hydration using corneometer® CM 825

Skin hydration significantly decreased after 24-hour SLS patch removal on both sites, by 24.67% with $p<0.005$ at the SLS treated- control site and by 20.96% with $p<0.005$ at the SLS treated-product site, indicating a compromised skin barrier. SLS treated-control site, hydration decreased by 1.18%, 9.98%, 15.32%, and 27.10% on day-01, 02, 03 and 07, respectively. The SLS treated-product site showed increase of 74.84%, 121.05%, 160.22% and 188.06% on day-01, 02, 03 and 07 ($p<0.05$). Compared to the control,

test product treated sites reflected a 3.83-fold greater improvement ($p<0.0001$).

Tape-stripping as well led to slight but non-significant reduction in skin hydration by 3.21% at the tape-stripped control site and by 1.20% at the tape-stripped product site. At the tape-stripped-control site, hydration decreased by 2.24% at 12 hours on day-01, 15.95% on day-02, 29.39% on day-03, and 35.28% by day-07. While at the tape-stripped-product treated site, a notable improvement of 88.12% ($p<0.001$) from baseline after 12 hours on day-01 of product application was recorded. Further, 98.14%, 115.40% and 138.83% improvement on day-02, 03, and 07 was recorded with a $p<0.05$ at all the tested time points. Compared to the control, test product treated sites reflected a 3.84-fold greater improvement with a p value <0.0001 (Figure 5).

Assessment of skin topography using visioscan VC 20 plus®

Skin roughness

Skin roughness increased non-significantly post 24-hour SLS patch removal at both sites. At the control site, roughness increased by 11.71% ($p\leq0.05$) and at product site by 16.34% (Lower mean values indicate greater roughness). On SLS-treated control site, roughness increased by 14.33%, 3.77%, 12.37%, and 37.38% on Day-01, 02, 03 and 07, respectively. In contrast, the SLS-treated product site showed reductions of 28.99%, 41.32%, and 61.58% on days 01, 02, and 03, respectively ($p<0.05$), reaching 107.31% by day-07 ($p<0.0001$), with a 3.24-fold greater improvement than control ($p<0.0001$).

Tape-stripping increased skin roughness by12.07%, which was non-significant decrease at the control site and 10.18% with $p<0.05$ at product site. This change indicates clear impairment of the skin barrier. At tape-stripped control site, roughness increased by 5.97%, 5.32%, 8.64%, and 36.56% on Days 01, 02, 03, and 07, respectively ($p<0.01$). At the tape-stripped-product treated site, the roughness reduced by 41.51%, 54.31%, and 77.74% on Days 01, 02, and 03, respectively ($p<0.01$), reaching 119.86% by day-07. The product treated site represented a 3.35-fold reduction ($p<0.00001$) compared to control site, highlighting the robust effect of the product on improving skin texture (Figure 6).

Skin smoothness

Skin smoothness decreased by 18.63% ($p<0.05$) at the control site and 29.78% ($p<0.001$) at product site (skin smoothness reduction is indicated by increase in mean values and vice versa). This showed significant disruption of the skin barrier at both sites following 24-hour SLS exposure. At the SLS treated-control site, smoothness reduced by 6.64%, 2.07%, 4.71% and 4.37%, after 12-hours on day-01, 02, 03, and 07, respectively ($p>0.05$). At the SLS-treated site, after product application improvements of 14.06% at 12-hours on day-01, 27.35% on day-02, 32.40% on day-03 and 30.13% on day-07 were observed ($p<0.0001$). On day-07, the product showed a 1.26-fold improvement over the control ($p<0.005$).

After tape-stripping, skin smoothness increased by 9.24% ($p>0.05$) at control site and decreased by 12.64% ($p<0.05$) at product site, confirming superficial skin damage is caused. At tape-stripping-control site, a negligible reduction of 0.56% was observed after 12 hours on day-01. The smoothness further reduced by 11.33%, 22.39% and 17.39% on day-02, 03, and 07, respectively, with a highly significant p value<0.05. At tape-stripped-product treated site smoothness improved by 22.64% after product usage at 12 hours on day-01, and further increased by 18.42%, 21.08% and 16.87% on day-02, 03, and 07, respectively. Although the decrease in smoothness values was not consistently progressive across all time points, the significant reduction by day-07 indicates a clear improvement in skin smoothness with highly significant ($p<0.001$). As compared to the control site, tape-stripped-product site showed 1.27X improvement ($p<0.0001$) on day-07 (Figure 7).

Skin scaliness

Skin scaliness increased by 116.63% ($p<0.01$) at control site and 102% with $p<0.001$ at product site, suggesting compromised skin barrier. At the SLS treated-control site, scaliness increased by 9.27%, 37.54%, 44.38% and 29.97% on days 01, 02, 03, and 07, respectively ($p<0.05$). At SLS treated-product site scaliness decreased by 44.48%**,** 64.08%, 78.33% and 63.45% days 01, 02, 03, and 07, respectively ($p<0.0001$). On day-07, the product showed a 1.95-fold improvement than control ($p<0.0001$).

Immediately after tape-stripping, the skin scaliness increased by 25.04% with $p>0.05$ at control site and by 57.44% with $p<0.01$ at product site. At the tape-stripped-control site, scaliness increased by 43.55%, 59.80%, 74.89% and 132.43% on day-01, 02, 03 and 07, respectively ($p<0.05$). At tape-stripped-product treated site scaliness decreased by 47.31% after 12 hours on day-01, and further by 56.95%, 61.94% and 47.57% on, day-02, 03, and 07, respectively ($p<0.0001$). On day-07, the product showed a 1.93-fold improvement than control site ($p<0.0005$) (Figure 8).

Skin wrinkles

The 24-hour SLS exposure resulted in development of skin wrinkles over a period of 7 days, suggesting impaired skin topography. After patch removal, the skin wrinkles reduced by 16.08% ($p<0.001$) at control site and 4.22% with $p>0.05$ at product site. At SLS treated-control site, after initial decrease wrinkles slightly increased by 3.35%, 20.12%, 36.30%, and 43.68% on day-01, 02, 03 and 07, respectively ($p<0.05$). At SLS treated-product site showed reductions of 2.35%, 6.12%, 7.16%, and 13.94% on days 01, 02, 03, and 07, respectively, with significant reductions from day-03 ($p<0.05$). As compared to the control site,

there was 1.56X improvement was observed on day-07 ($p<0.0001$).

Tape-stripping resulted in formation of skin wrinkles at both sites. At control site, the wrinkles initially reduced by 21.41% with $p<0.05$ and by 22.14% with $p<0.001$ at product site. Skin wrinkles increased slightly post 12 hours on day-01, by 0.17% and further increased progressively by 21.62%, 41.86%, 64.67% on day-02, 03 and day-07, respectively ($p<0.05$). At tape-stripped-product site showed a 0.06% reduction on day 01, followed by increases of 3.70% and 3.57% on days-02 and 03, and a 2.80% reduction by day-07 ($p>0.05$). On day-07, the product showed a 1.84-fold improvement over the untreated site ($p<0.05$) (Figure 9).

Secondary efficacy endpoints

Assessment of skin irritation, dryness, scaliness, peeling, itching, swelling and smoothness by dermatological evaluation

Before disrupting the skin barrier no irritation, scaling, itching, or swelling was observed in any subject, though slight dryness and skin smoothness were noted. On day-01, prior to product application, very mild irritation and scaling appeared at the SLS treated sites, while the tape-stripped site remained unaffected.

At the control site, slight irritation persisted initially and reduced eventually by day-07, while at product sites, slight irritation persisted at SLS sites but resolved by day-02 post product application, with no further irritation observed through day-07.

Mild dryness and scaling were also present at SLS control sites through day-03 but resolved in treated sites by day-07. No skin peeling was noted at any point across all sites. Itchiness and swelling, observed only pre-treatment on day-01 post SLS patch removal, which resolved entirely at control site as well as at product site post product application.

Skin smoothness improved from slightly at baseline to moderate at the treated areas by day-07, indicating enhanced skin texture after test product application while it remained unimproved at the control sites.

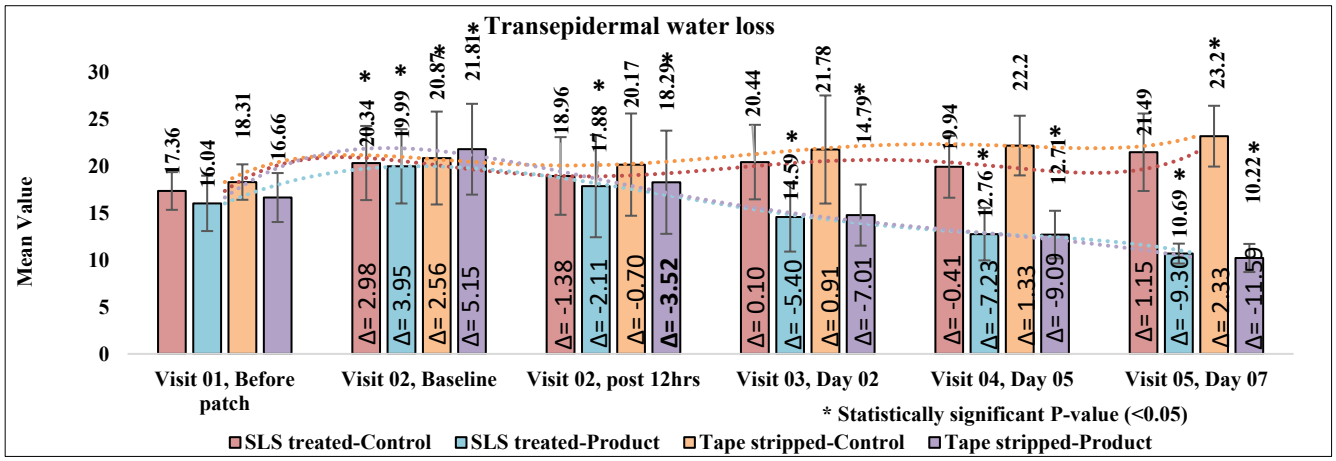

Figure 4: Change in transepidermal water loss.

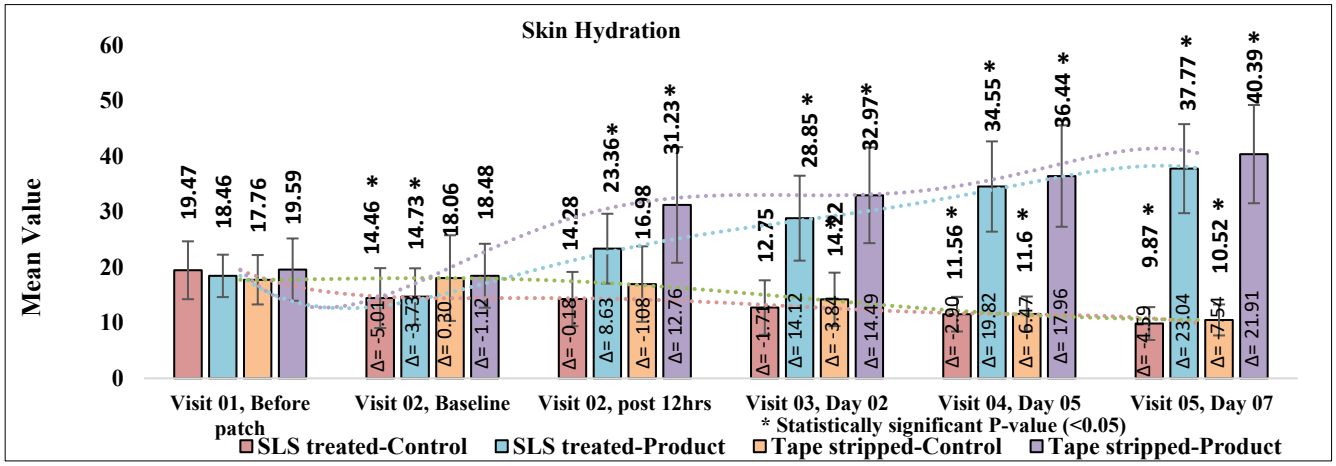

Figure 5: Change in skin hydration.

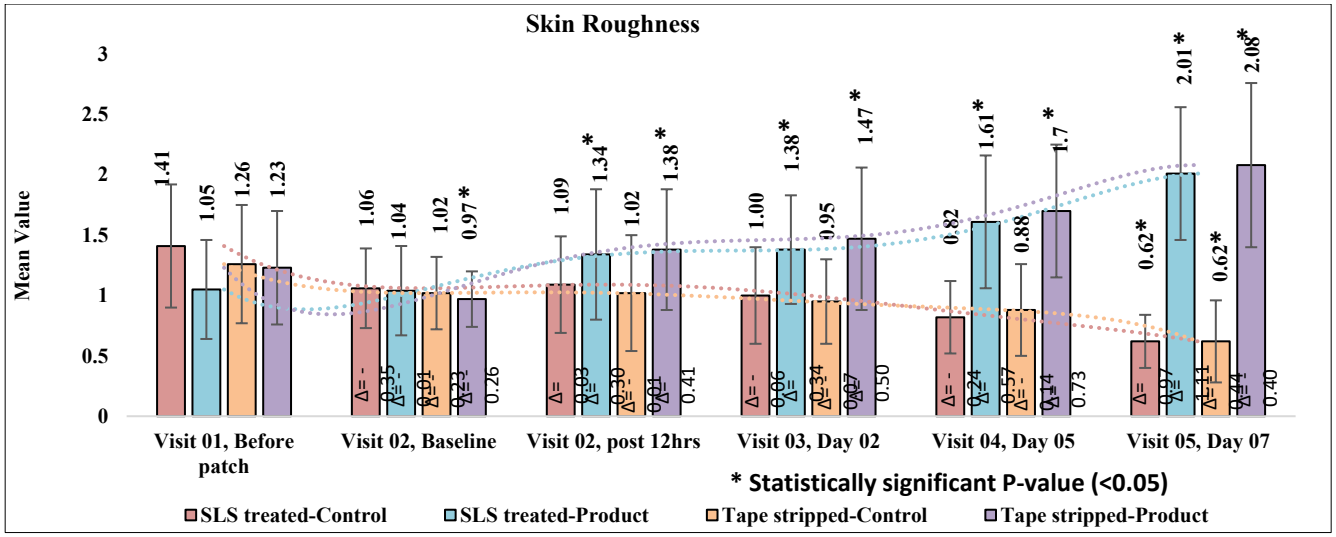

Figure 6: Change in skin roughness.

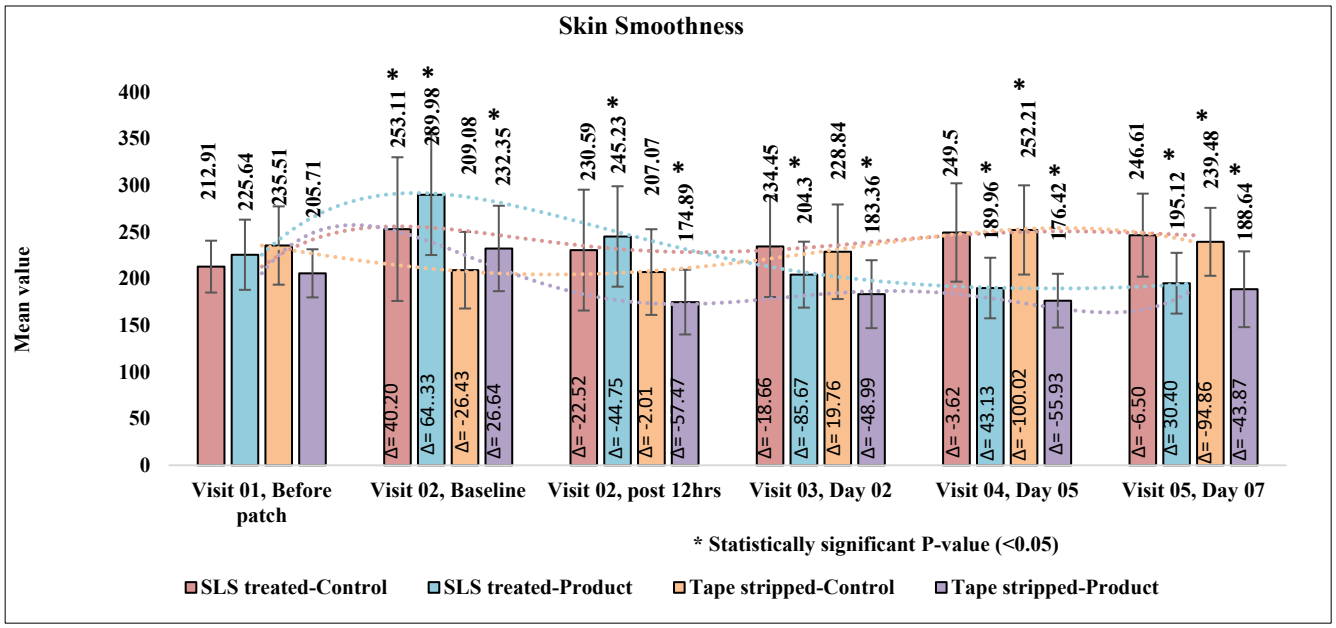

Figure 7: Change in skin smoothness.

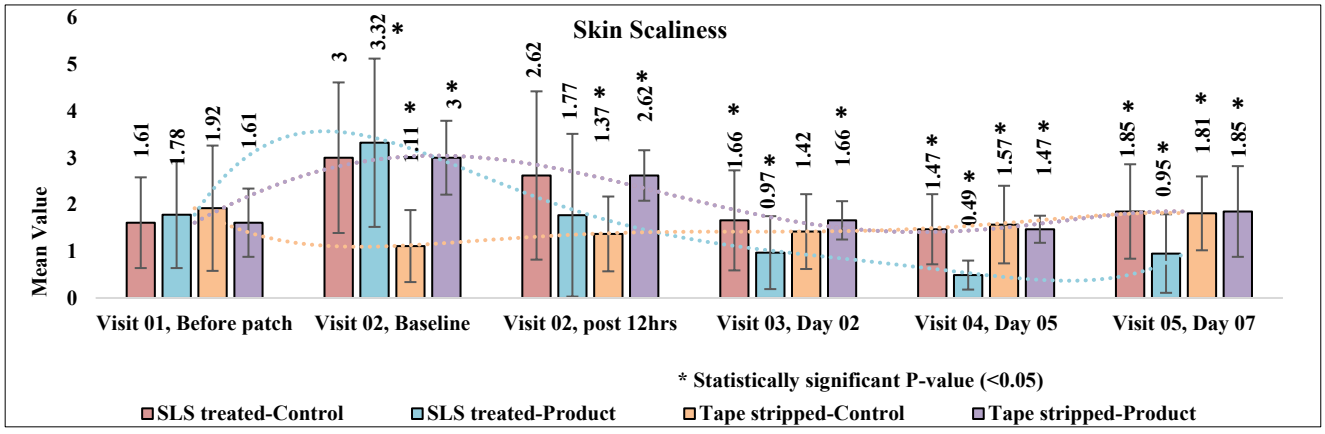

Figure 8: Change in skin Scaliness.

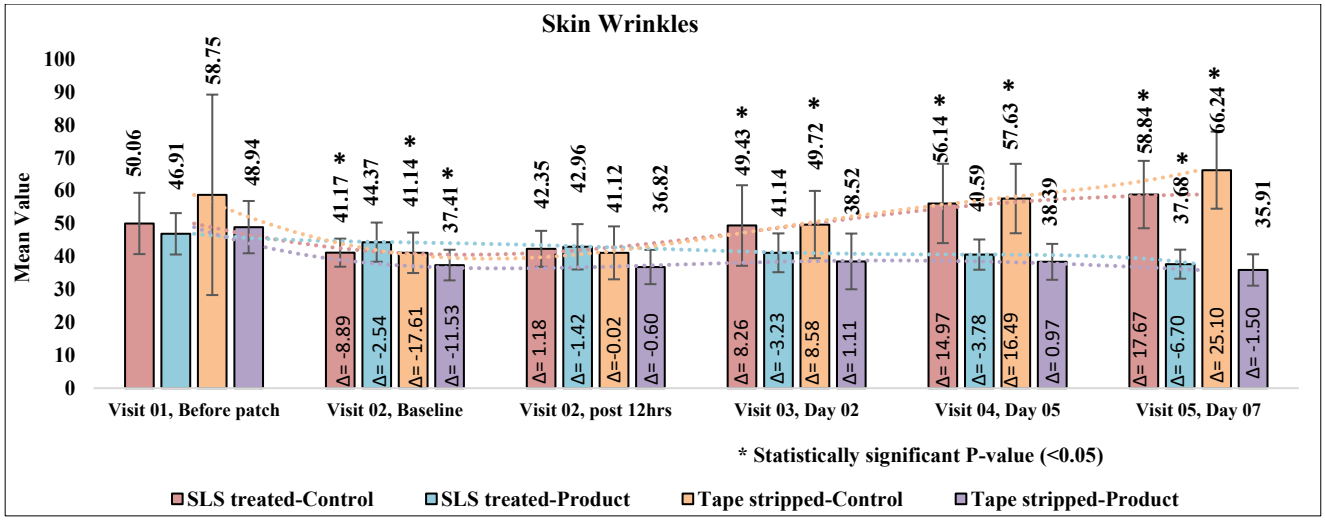

Figure 9: Change in skin wrinkles.

DISCUSSION

This clinical study, evaluated AVE in promoting cosmetic wound-healing capacity, specifically in restoring skin function and integrity following experimental barrier disruption using SLS and tape-stripping.[20] Barrier recovery**,** hydration**,** surface topography, and tolerability were assessed using instrumental and clinical measures.

The efficacy of AVE, was demonstrated in a pilot *in-vivo* study, showing sustained skin moisturization for up to 2 hours, along with previously established *in-vitro* anti-inflammatory activity and wound-healing potential.[18] In the present study, standardized and validated SLS and tape-stripping models were used to induce skin barrier disruption. Consistent with previous findings, both models increased TEWL, confirming barrier impairment.[7]

TEWL is a key marker of skin barrier integrity and is widely used to assess epidermal recovery.[21,22] Evidence from longitudinal assessments indicates that TEWL scores at healed wound sites progressively decrease over time, particularly in patients without recurrence.[23,24] Previous studies show moisturisers containing AVE in females with Fitzpatrick skin type II and III reduced TEWL and increased skin hydration after 1 week of application with significant $p<0.01$.[25] Consistent with these findings, AVE produced progressive and significant TEWL reductions, by 26.92% and 30.54% at 24 hours and 44.89% and 51.42% by day-07 at the SLS-treated and tape-stripped sites, respectively ($p<0.01$). These reductions, exceeding two-fold those of the control sites, indicate improved stratum corneum and improved epidermal cohesion, which are critical aspects of early-stage wound healing and skin barrier repair.

AVE rapidly improved hydration, 121.05% and 98.14% after 24 hours and 188.06% and 138.83% by day-07 at SLS treated and tape-stripped sites respectively. These results highlight its effectiveness in quickly restoring skin moisture. These changes translated to approximately 3.8-fold improvements over both the control sites.

Improved smoothness and reduced roughness are important indicators of skin recovery. A prior study reported significant smoothness improvement after just one application of healing ointment ($p<0.05$), consistent with our findings.[26] AVE reduced skin roughness by 107.31% and 119.86% and improved smoothness by 30.13% and 16.87% at SLS-treated and tape-stripped sites, respectively.

Scaliness was substantially reduced by day-07, 63.45% and 47.57% at SLS treated site and tape-stripped site respectively. Although wrinkle reduction was a secondary endpoint, AVE showed moderate improvement by 13.94% and 2.80% at SLS treated site and tape-stripped respectively by 7th day, potentially linked to dermal matrix restoration during healing.

Clinical assessments confirmed excellent tolerability, with transient irritation resolving by day-02 and no adverse effects reported. Improvements in dryness, itching, and visible smoothness further support AVE's role in promoting symptomatic relief and cutaneous repair in wounded skin.

The small, homogenous sample of healthy adult females allowed for controlled evaluation but may benefit from broader population inclusion in future studies. The short 7-day duration effectively captured early-stage wound healing, laying the groundwork for extended trials to assess long-term benefits.

Additionally, the use of standardized superficial wound models (SLS and tape-stripping) provided reliable, reproducible data, though further research on complex or chronic wounds such as those caused by dermal abrasions or laser treatments would enhance clinical applicability.

CONCLUSION

This clinical study confirms evidence supporting efficacy of the topical formulation containing 5% AVE for treating superficial skin damage resulting from cosmetic procedures such as chemical peels or depilatory treatments. AVE demonstrated measurable improvements in skin hydration, barrier restoration, and surface texture, with reductions in TEWL, roughness, itchiness, and fine lines markers of healthy skin recovery. Enriched with the healing properties of Aloe vera the formulation delivers rapid soothing relief and promotes visible skin repair. Hence, these proven benefits in relieving post-depilatory stress, positions topical gel cream containing AVE as a reliable option for daily skin barrier care and post-procedural recovery.

ACKNOWLEDGEMENTS

Authors would like to thank operation team, medical writing team and statistic team of NovoBliss Research. They would also like to thank all the study participants for their time, cooperation, and commitment, without whom this research would not have been possible.

Funding: The study was funded by Keva – S. H. Kelkar and Company Limited
Conflict of interest: None declared
Ethical approval: The study was approved by the Institutional Ethics Committee

REFERENCES

1. Rai PPAP, Rai DS. Pharmaceutical creams and their use in wound healing: A review. J Drug Deliv. 2019:907-12.
2. Heise R, Schmitt L, Huth L, Krings L, Kluwig D, Katsoulari KV, et al. Accelerated wound healing with a dexpanthenol-containing ointment after fractional ablative CO_2 laser resurfacing of photodamaged skin in a randomized prospective clinical trial. Cutan Ocul Toxicol. 2019;38(3):274-8.
3. Pany A, Klang V, Brunner M, Ruthofer J, Schwarz E, Valenta C. Effect of physical and chemical hair removal methods on skin barrier function in vitro: Consequences for a hydrophilic model permeant. Skin Pharmacol Physiol. 2019;32(1):8-21.
4. Döge N, Avetisyan A, Hadam S, Barbosa Pfannes EK, Rancan F, Blume-Peytavi U, et al. Assessment of skin barrier function and biochemical changes of ex vivo human skin in response to physical and chemical barrier disruption. Eur J Pharm Biopharm. 2017;138:148-58.
5. Ousey K, Cutting KF, Rogers AA, Rippon MG. The importance of hydration in wound healing: Reinvigorating the clinical perspective. J Wound Care. 2016;25(3):122-30.
6. Hoeksema H, De Vos M, Verbelen J, Pirayesh A, Monstrey S. Scar management by means of occlusion and hydration: a comparative study of silicones versus a hydrating gel-cream. Burns. 2013;39(7):1437-48.
7. Patel N, Merja A, Gajera D, Patel M. Assessing techniques for creating skin damage and evaluating wound healing: Significance for skincare and clinical application. Int J Med Sci Innov Res. 2024;9:77-87.
8. Tsai JC, Shen LC, Sheu HM, Lu CC. Tape stripping and sodium dodecyl sulfate treatment increase the molecular weight cutoff of polyethylene glycol penetration across murine skin. Arch Dermatol. 2003:169-74.
9. Kamrani P, Hedrick J, Marks JG, Zaenglein AL. Petroleum jelly: A comprehensive review of its history, uses, and safety. J Am Acad Dermatol. 2024;90(4):807-13.
10. Ekor M. The growing use of herbal medicines: Issues relating to adverse reactions and challenges in monitoring safety. Front Pharmacol. 2014;4:177.
11. Ratna MR, Thirumal M. Wound healing activity of herbal ointment containing ethanol leaves extracts of Memecylon species collected from a part of the Eastern Ghats regions. J Appl Pharm Sci. 2025;15(5):197-204.
12. Oryan A, Alemzadeh E, Moshiri A, Tabandeh MR. Topical application of Aloe vera accelerated wound healing, modeling, and remodeling: An experimental study. Ann Plast Surg. 2016;77(1):37-46.
13. Stan D, Tanase C, Avram M, Apetrei R, Mincu NB, Mateescu AL, et al. Wound healing applications of creams and "smart" hydrogels. Exp Dermatol. 2021;30(9):1218-32.
14. Itsarasook K, Prompamorn P, Tanghiranrat J, Srisukong A, Komutiban O, Haritakun W, et al. In vitro antioxidant, anti-inflammatory, and wound healing properties of Aloe vera infused with canola oil for possible application in skin cosmetics. J Food Health Bioenviron Sci. 2025;18(1).
15. Chinchilla N, Carrera C, Durán AG, Macías M, Torres A, Macías FA. Aloe barbadensis: How a miraculous plant becomes reality. Phytochem Rev. 2013:581-602.
16. Zago LR, Prado K, Benedito VL, Pereira MM. The use of babosa (Aloe vera) in treating burns: a literature review. Braz J Biol. 2021;83:e249209.
17. Mainkar A, Mukherjee D, Dhawal P, Vaze K. A stable and standardized Aloe vera gel extract with proven efficacy in oral and personal care applications. SOFW J. 2023;149:10.
18. Lodén M. Barrier recovery and influence of irritant stimuli in skin treated with a moisturizing cream. Contact Dermatitis. 1997;36(5):256-60.
19. Wilhelm KP, Wilhelm D, Bielfeldt S. Models of wound healing: An emphasis on clinical studies. Skin Res Technol. 2017;23(1):3-12.
20. Roy S, Elgharably H, Sinha M, Ganesh K, Chaney S, Mann E, et al. Mixed-species biofilm compromises wound healing by disrupting epidermal barrier function. J Pathol. 2014;233(4):331-43.
21. Alexander H, Brown S, Danby S, Flohr C. Research techniques made simple: Transepidermal water loss

measurement as a research tool. J Invest Dermatol. 2018;138(11):2295-300.
22. Chattopadhyay D, Sinha M, Kapoor A, Kumar M, Singh K, Mathew-Steiner SS, et al. Deficient functional wound closure as measured by elevated transepidermal water loss predicts chronic wound recurrence: An exploratory observational study. Sci Rep. 2024;14(1):23593.
23. Gorski J, Proksch E, Baron JM, Schmid D, Zhang L. Dexpanthenol in wound healing after medical and cosmetic interventions (postprocedure wound healing). Pharmaceuticals (Basel). 2020;13(7):138.
24. Dal'Belo PM, Gaspar LR, Maia Campos PMBG. Moisturizing effect of cosmetic formulations containing Aloe vera extract in different concentrations assessed by skin bioengineering techniques. Skin Res Technol. 2006;12(4):241-6.
25. Farberg AS, Palomares SJ, Nguyen TQ, Emesiani C, Meckfessel M. An over-the-counter healing ointment: Benefits in dry skin and wound healing. J Drugs Dermatol. 2024;23(5):360-5.
26. Oryan A, Mohammadalipour A, Moshiri A, Tabandeh MR. Topical application of Aloe vera accelerated wound healing, modeling, and remodeling: An experimental study. Ann Plast Surg. 2016;77(1):37-46.

Cite this article as: Mainkar A, Shirodkar M, Kumbhar S, Dhawal P, Vaze K, Patel M, et al. Efficacy evaluation of aloe vera extract in topical gel cream for supporting dermal regeneration and skin barrier repair following chemical and mechanical damage. Int J Res Dermatol 2027;13:xxx-xx.