

## Case Report

# Concomitant presence of bilateral nevus of Ota with unilateral nevus of Ito and halo nevus: a rare association

Aarti S. Salunke<sup>1</sup>, Mahendra V. Nagargoje<sup>2\*</sup>, Ravindranath B. Chavan<sup>1</sup>, Nilima M. Bansal<sup>1</sup>

Department of Skin and VD, <sup>1</sup>B.J. Govt. Medical College, Pune, <sup>2</sup>BKL Walawalkar Rural Hospital, Ratnagiri, Maharashtra, India

**Received:** 19 July 2017

**Accepted:** 08 August 2017

**\*Correspondence:**

Dr. Mahendra V. Nagargoje,

E-mail: [drmahen3apr@gmail.com](mailto:drmahen3apr@gmail.com)

**Copyright:** © the author(s), publisher and licensee Medip Academy. This is an open-access article distributed under the terms of the Creative Commons Attribution Non-Commercial License, which permits unrestricted non-commercial use, distribution, and reproduction in any medium, provided the original work is properly cited.

### ABSTRACT

Nevus of Ota is dermal melanocytosis, generally presents as blue-black or gray-brown patchy diffuse pigmentation. Most commonly occurs unilaterally on face in areas innervated by the first and second divisions of trigeminal nerves. Bilateral involvement and oral mucosal involvement can occur, but as a rare manifestation. Nevus of Ota may be very rarely associated with the nevus of Ito and other extra cutaneous features. The halo nevus may be seen in congenital or acquired melanocytic nevi. Presence of halo nevus in conjunction with two different dermal nevi is not reported till date. We are reporting 19 year old female presented with bilateral Nevus of Ota with oral mucosal involvement and associated nevus of Ito and halo nevus.

**Keywords:** Bilateral nevus of Ota, Dermal nevi, Halo nevus, Nevus of Ito, Palate and tongue pigmentation

### INTRODUCTION

Nevus of Ota first described In 1939 Masao Ota who gave a descriptive name of the condition as nevus fuscocaeruleus ophthalmomaxillaris and thereafter the condition was known as nevus of Ota.<sup>1</sup> Clinically characterized by unilateral blue gray patch involving skin and mucosa. The extracutaneous lesions may occur in sclera, cornea, eyelids, retina and other sites like tympanum (55%), nasal mucosa (30%), pharynx (25%), palate (20%) etc.

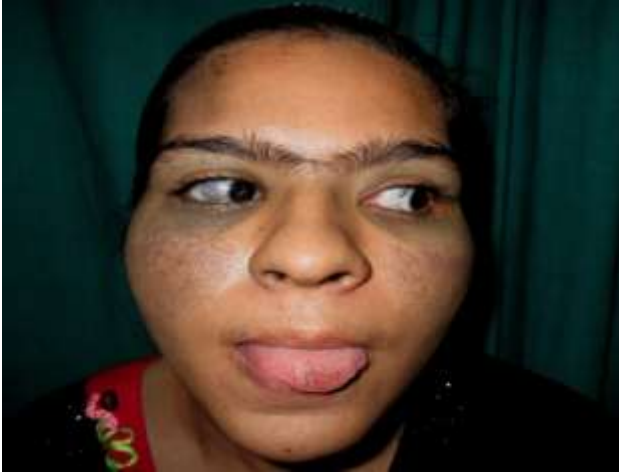M. Ito first described a congenital pigmented patch or nevus fuscoceruleus acromiodeltoideus in 1954. Nevus of Ito is a slate blue patch of dermal pigmentation involving the distribution of the posterior supraclavicular and lateral brachial cutaneous nerves.<sup>3</sup> Nevus of Ito has features similar to that of Ota's nevus, it differ only by area of distribution and rarely seen. Nevus of Ota and Ito together were seldom reported.<sup>2</sup>

In 1916, Sutton described halo nevus (HN) as a leukoderma acquisitum centrifugum is a rare finding characterized by a hypopigmented peripheral lining around the melanocytic nevus due to an autoimmune lymphocytic response which simulates a halo.<sup>4</sup>

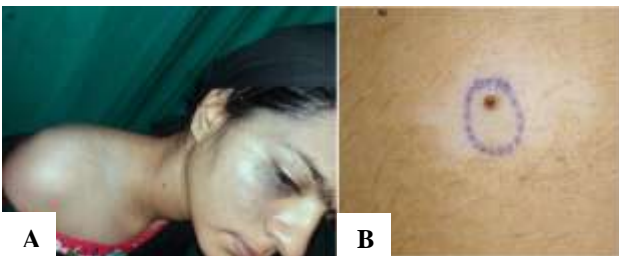### CASE REPORT

A 19 year-old female patient presented with asymptomatic darkly pigmented patches over both sides of cheek since birth. These lesions were small in size initially and appeared only over cheeks. After few years these patches gradually appeared over peri-orbitally, temple and forehead region. Patient gave history of similar asymptomatic lesions over right shoulder region which was also since birth. Lesions were faint in color during childhood, but after puberty it became darkly pigmented. On further inquiry, patient showed another asymptomatic whitish lesion with mole over upper back which was developed since two years. Because of

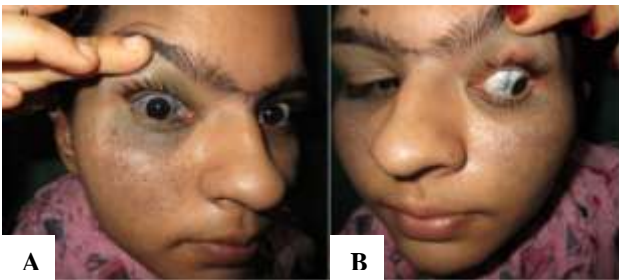cosmetic concern patient seek medical consultation. On dermatological examination there was bluish colored mottled pigmented macule present over mid-face (Figure 1). On of right side of face this pigmentation involved right sided forehead, temple, peri-orbital and malar region and more intense in color compared to other side. On left side pigmentation was present over temple, peri-orbital and malar region. Large greenish-blue colored macule was present over right shoulder region, extending from acromio-clavicular region up to upper part of scapular region (Figure 2).



**Figure 1: Bluish coloured mottled pigmented macule over bilateral cheeks, periorbital, temple region. Pigmentation of bilateral sclera and tip of tongue.**



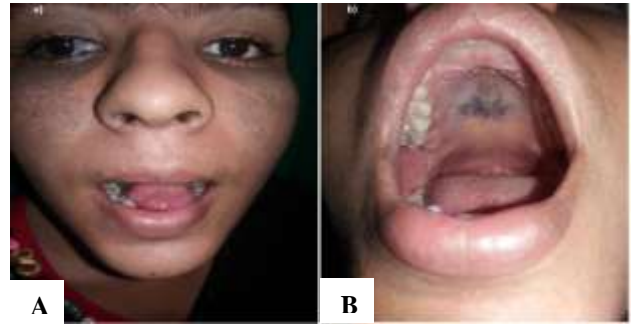**Figure 2: A) Greenish- blue macule over right shoulder region (nevus of Ito); B) central melanocytic nevus with peripheral depigmented macule (halo nevus).**



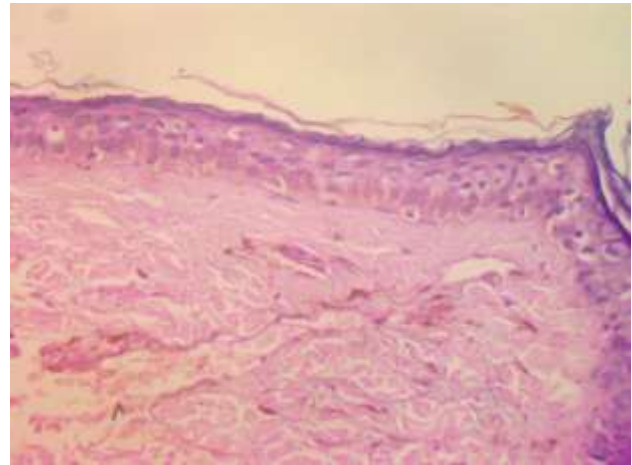
**Figure 3: A) Greyish pigmentation of right sclera all around the limbus; B) greyish pigmentation of left sclera superomedially.**

Over the upper back, there was dark colored melanocytic nevus surrounded by depigmented peripheral macule, diagnosed as Halo nevus clinically (Figure 2).

Ophthalmological examination revealed bilateral scleral pigmentation (Figure 3). On right side, conjunctiva and sclera showed bluish black pigmentation all around the limbus. On left side, supero-medial scleral pigmentation was observed. Visual acuity and indirect gonioscopy did not reveal any abnormality.



**Figure 4: A) Brownish mottled pigmented macule over tip of the tongue; B) bluish-black macule over right side of hard palate encroaching to the left side by crossing midline.**



**Figure 5: H and E stain (40 X). Pigmented dendritic dermal melanocytes in mid-dermis.**

Intraoral examination revealed bluish-black macule over right side of hard palate encroaching to the left side by crossing midline (Figure 4). Tip of the tongue showed brown colored macule. Rest of the oral mucosa was normal. Auditory examination did not revealed discoloration of auricle and tympanic membrane. Audiometry did not reveal hearing loss. Clinically diagnosis of bilateral nevus of Ota along with nevus of Ito made. Histopathology from affected region of face and shoulder showed pigmented dendritic dermal melanocytes with unremarkable epidermal changes (Figure 5).

## DISCUSSION

Both nevus of Ota and nevus of Ito are dermal melanocytoses. Nevus of Ota may represent melanocyte that may have persisted and not migrated completely from the neural crest to the epidermis during the embryonic stage. The predisposing factors are genetics, female sex hormones, infection, trauma, and ultraviolet light exposure.<sup>5</sup> Though most (90%) of the cases of nevus of Ota are unilateral, in 5 to 10% cases pigmentation can occur bilaterally (as in our case) and may involve ocular, nasal and oral mucosal surfaces. The deeper lesions appear blue in colour due to Tyndall effect, whereas the more superficial lesions are slate grey in colour.<sup>6</sup>

Tanino classified nevus of Ota into four types: mild (type 1), moderate (type 2), intense (type 3), and bilateral (type 4). This case belongs to type 4 according to Tanino's classification. In patients with ocular pigmentation certain complications such as increased intraocular pressure with or without glaucoma, asymmetric cupping of the optic nerve head not associated with glaucoma, uveitis, cataracts, orbital melanomas, and retinitis pigmentosa have been reported as coincidental findings.<sup>7</sup> Our patient did not show any changes of glaucoma at present, but she needs to be closely evaluated biannually to prevent development of these complications.

The nevus of Ito otherwise clinically and histopathologically similar to the nevus of Ota.<sup>3</sup> It is predominant in Asia and darker skinned races and may be associated with an ipsilateral or bilateral nevus of Ota. Though association of these two nevi is rare there are few reports showing this association. Hidano et al has reported a case of bilateral nevus of Ota with nevus of Ito and lip pigmentation while Mukhopadhyay et al reported a case of unilateral nevus of Ota and nevus of Ito in Indian male.<sup>8,9</sup> One case report in literature observed unilateral nevus of Ota with bilateral nevus of Ito.<sup>2</sup> Our case was rare association of bilateral nevus of Ota with palate and tongue pigmentation and associated unilateral nevus of Ito. So far literature documents only 12 cases of nevus of Ota with intraoral involvement (hard palate), pigmentation over tongue is infrequent. To best of our knowledge only single case with tongue pigmentation is reported in the literature.<sup>6</sup> So our case would be the second case to report tongue pigmentation in nevus of Ota patient.

Benign cutaneous and leptomeningeal conditions associated with nevus of Ota are phakomatosis pigmentovascularis, nevus flammeus, Sturge-Weber syndrome, Klippel-Trenaunay syndrome, and neurofibromatosis.<sup>10</sup> Our case highlights association of halo nevus with these two dermal nevi, which was not reported till date.

The halo phenomenon may be observed around congenital or acquired melanocytic nevi, nevocellular

nevus, blue nevus, spitz nevus, neurofibromas and primary or metastatic melanomas. The halo nevus is frequently associated with vitiligo. In our patient halo nevus around melanocytic nevus was observed along with presence of two different dermal nevi over distant location.

We are first to report this rare association of bilateral nevus of Ota having palate and tongue pigmentation with unilateral nevus of Ito and Halo nevus. The authors emphasize the rarity of this triple association in the literature.

*Funding: No funding sources*

*Conflict of interest: None declared*

*Ethical approval: Not required*

## REFERENCES

- Ota M. Nevus fuscocoeruleus ophthalmomaxillaris. *Tokio Med J.* 1939;63:1243-5.
- Mukhopadhyay AK. Unilateral Nevus of Ota with Bilateral Nevus of Ito and Palatal Lesion: A Case Report with a Proposed Clinical Modification of Tanino's Classification. *Indian J Dermatol.* 2013;58(4):286-9.
- Ito M. Studies on melanin. XXII. Nevus fuscoeruleus acromiodeltoideus. *Tohoku J Exp Med.* 1954;60:10.
- Babu A, Bhat M R, Dandeli S, Ali NM. Throwing light onto the core of a halo nevus: A new finding. *Indian J Dermatol.* 2016;61:238.
- Maheshwari R, Desai V, Sunil Kumar M V, Gaurav I. Unilateral nevus of ota: A case report of oculodermal melanocytosis!. *J Dent Allied Sci.* 2016;5:39-42.
- Shivhare P, Lata S, Yadav M, Haidry N, Patil ST. A Nevus of OTA with Intraoral Involvement: A Rare Case Report. *Int J Oral Health Med Res.* 2015;2(2):76-9.
- Kumar MA, Venkatesh E, Srikanth D, Prashanth P. The case of a rare nevus with palatal, facial, and scleral pigmentation. *Univ Res J Dent.* 2013;3:131-3.
- Hidano A, Kajima H, Endo Y. Bilateral nevus Ota associated with nevus Ito. A case of pigmentation on the lips. *Arch Dermatol.* 1965;91(4):357-9.
- Mukhopadhyay AK. Nevus of ota associated with nevus of Ito. *Indian J Dermatol Venereol Leprol.* 2004;70:112-3.
- Hino K, Nagane M, Fujioka Y, Shiokawa Y. Meningeal melanocytoma associated with ipsilateral nevus of Ota presenting as intracerebral hemorrhage: case report. *Neurosurgery.* 2005;56:1376-7.

**Cite this article as:** Salunke AS, Nagargoje MV, Chavan RB, Bansal NM. Concomitant presence of bilateral nevus of Ota with unilateral nevus of Ito and halo nevus: a rare association. *Int J Res Dermatol* 2017;3:538-40.