

Original Research Article

Microneedling vs. chemical reconstruction of skin scars with trichloroacetic acid: a comparative study

Nithya Dhollan^{1*}, Vanathi Thirunavukkarasu²

¹Department of Dermatology, Venereology and Leprosy, Karpagam Faculty of Medical Sciences and Research, Coimbatore, Tamil Nadu, India

²Department of Cosmetology, Stanley Medical College, Chennai, Tamil Nadu, India

Received: 22 March 2017

Accepted: 28 April 2017

*Correspondence:

Dr. Nithya Dhollan,

E-mail: drnithyadhollan@gmail.com

Copyright: © the author(s), publisher and licensee Medip Academy. This is an open-access article distributed under the terms of the Creative Commons Attribution Non-Commercial License, which permits unrestricted non-commercial use, distribution, and reproduction in any medium, provided the original work is properly cited.

ABSTRACT

Background: Acne scars are a cause of major psychological morbidity in the young population. Microneedling using dermarollers which uses the principle of percutaneous collagen induction and Chemical reconstruction of skin scars (CROSS) using Trichloroacetic acid (TCA) are both widely used methods for the treatment of acne scars and are cheaper alternatives to LASER resurfacing. The aim of our study is to objectively compare the efficacy of microneedling using dermaroller with CROSS using 100% TCA in the management of acne scars.

Methods: 30 patients with acne scars were divided into 2 groups A and B with 15 patients each. Group 'A' underwent microneedling using 1.5 mm dermaroller and Group 'B' underwent CROSS technique with 100% TCA. A total of 4 sessions at monthly intervals were performed on both groups. The percentage improvement in the acne scar grade between the two groups was compared using the student 't' test.

Results: Among the 30 patients, 13 (86%) patients in Group A (Microneedling) and 11 (78%) patients in group B (CROSS) noted significant reduction in their acne scar grade. The difference between the 2 groups was statistically insignificant. 3 patients had significant post inflammatory hyperpigmentation in group 'B'.

Conclusions: The techniques of microneedling and CROSS are both effective in acne scars But microneedling scores in other aspects such as faster wound healing, better skin rejuvenation and safety in dark skinned individuals.

Keywords: Acne scars, Microneedling, Dermaroller, Percutaneous collagen induction, Chemical reconstruction of skin scars, Trichloroacetic acid

INTRODUCTION

The psychological disadvantage of acne vulgaris extends even after its control since post acne scarring is a permanent sequelae.¹ There are various procedures to treat acne scars such as LASERS, microneedling and chemical peel. While LASERS (Fractional CO₂, Erb: YAG lasers) may be more effective, they are associated with a significant down time. Affordability is a major limiting factor for the widespread use of LASERS.² In such scenarios, microneedling with dermarollers and chemical reconstruction of scars (CROSS) with trichloroacetic acid (TCA) are cost effective options.²⁻⁴

Microneedling with dermarollers uses the principle of percutaneous collagen induction in which multi microperforations made into the scarred dermis cuts the scar tissue and leads to bleeding. Microinjury acts as a stimulus for the release of growth factors thereby inducing the production of new collagen.^{3,4}

Chemical reconstruction of scars (CROSS) with 100% trichloroacetic acid (TCA) uses the principle of controlled destruction as in chemical peels with subsequent re-epithelisation resulting in modification of scars.⁵

Both of these techniques are cheaper cousins to expensive LASER resurfacing of scars.²

The aim of this study is to compare the efficacy of microneedling with dermarollers and chemical reconstruction of scars (CROSS) with 100% TCA in the management of acne scars. This study is also designed to study the adverse effect profile of both modalities of treatment.

METHODS

This prospective randomised open labelled controlled study was carried out in a tertiary care hospital over a period of 6 months. 30 patients who had acne scars were enrolled in the study. The acne scars were graded according to Goodman and Baron grading (Table 1).⁶ The patients were randomised into two groups A and B. Group A received microneedling treatment. Each patient received 4 sessions at intervals of one month. Group B received Chemical reconstruction of scars (CROSS) with

100% trichloroacetic acid (TCA), 4 sessions each at 1 month intervals.

Inclusion criteria

Patients aged between 18 to 45 years of age who had grade 2, 3 or 4 acne scars according to Goodman and Barons grading were included in the study. Also only those patients who are wilfully consenting to undergo multiple sessions are included in the study.

Exclusion criteria

Patients with active acne and active infections such as herpes simplex were excluded from the study. Patients who had taken oral retinoids in the past 6 months, those with keloidal and bleeding tendencies were excluded from the study. Also excluded were those with pregnancy and lactation and also those who had unrealistic expectations from the outcome of the procedure.

Table 1: Goodman and Baron grading of acne scars.

Grade	Level	Clinical features
1	Macular	Erythematous, hyper or hypo pigmented
2	Mild	Mild atrophy or hypertrophy scars that may not be obvious at social distances of 50cm or greater and may be covered adequately by makeup or the normal shadow of shaved beard hair in men or normal body hair if extrafacial.
3	Moderate	Moderate atrophic or hypertrophic scarring that is obvious at social distances of 50cm or greater and is not covered easily by makeup or the normal shadow of shaved beard hair in men or body hair if extrafacial, but is still able to be flattened by manual stretching of the skin (if atrophic).
4	Severe	Severe atrophic or hypertrophic scarring that is evident at social distances greater than 50cm and is not covered easily by makeup or the normal shadow of shaved beard hair in men or body hair if extrafacial and is not able to be flattened by manual stretching of the skin

Technique for microneedling

Topical anaesthesia containing lignocaine and prilocaine was applied to the affected areas one hour prior to the procedure. Under aseptic conditions microneedling was done with a dermaroller (Dermaroller G, Dermaindia). The device consists of cylindrical plastic drum which is designed to roll vigorously. It contains a microarray of needles arranged circularly in 24 rows of 8 needles each making a total of 192 needles. The needles are gold plated and of 1.5 mm depth. The dermaroller was gently rolled over the acne scars in three different directions each perpendicular to the other. Pinpoint bleeding was observed on rolling which was considered to be the end point. After the procedure erythema and edema were noticed. The patients were advised to avoid sun exposure and use sunscreens after the procedure.

Technique for CROSS

After thorough cleansing of the face and degreasing, 100% trichloroacetic acid was applied to the scars using a sharpened toothpick. The end point was frosting. After

the procedure the patients were advised to avoid sun exposure and use sunscreens regularly.

Serial photographs were taken, one before the commencement of treatment and then repeated every month for all the patients.

At the end of the fourth session the percentage improvement in acne scars was noted. The observations were tabulated. The results were graded on the basis of the percentage improvement as follows: Grade 0: Less than 25% improvement; Grade 1: 25-49% improvement; Grade 2: 50-74% improvement; Grade 3: More than 75% improvement. Those patients with 1, 2 and 3 grades of improvement were taken to have improved. The percentage of those patients with improvement in group A and group B were compared using the students "t" test. The p value was computed.

RESULTS

Of the 30 patients, 15 patients in group A and 14 patients in group B completed the 4 sessions of microneedling

and CROSS technique respectively. One patient in group ‘B’ was lost to follow up after the 2nd session.

Among the 15 patients in group ‘A’ who underwent microneedling at the end of the 4th session, 2 patients showed less than 25% improvement. 2 patients showed improvement between 25-49%, 7 patients showed improvement between 50-75% and 4 patients showed improvement of more than 75% (Figure 1a and b, 2a and b). The percentage of patients showing various grades of improvement is shown in Table 2.

Table 2: Percentage of patients showing various grades of improvement in group A (microneedling).

Grade	Percentage of improvement	No of patients improved	Percentage of patients improved
0	<25%	2	13.3%
1	25-49%	2	13.3%
2	50-74%	7	46.7%
3	>75%	4	26.7%

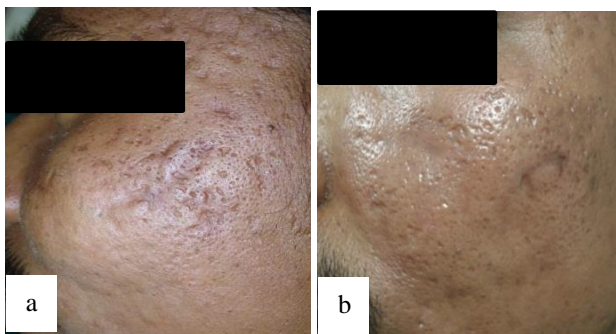


Figure 1 (a and b): Before and after microneedling (Group A).

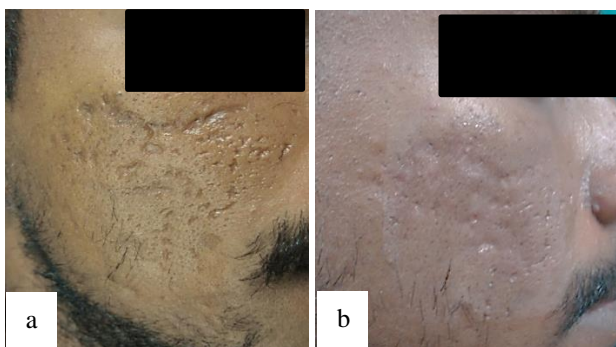


Figure 2 (a and b): Before and after microneedling (Group A).

Among the 14 patients in group ‘B’ who underwent CROSS technique with 100% trichloroacetic acid, at the end of 4 sessions, 3 patients showed less than 25% improvement. 4 patients showed improvement between 25-49%. 5 patients showed an improvement of 50-74% in their acne scars. 2 patients showed an improvement of more than 75% (Figure 3a and b). The percentage

distribution of the grades of improvement of patients in group ‘B’ who underwent CROSS is represented in Table 3.

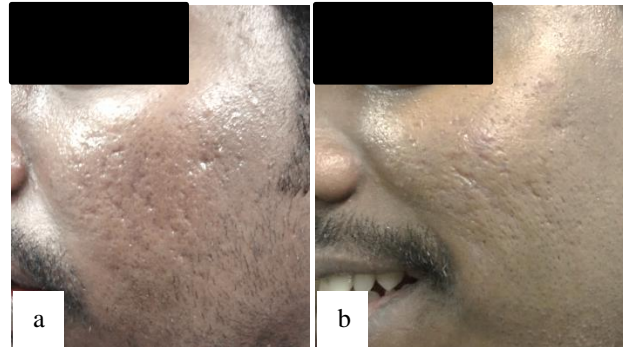


Figure 3 (a and b): Before and after CROSS with TCA (Group B).

Table 3: Percentage of patients showing various grades of improvement in Group B (CROSS with 100% TCA).

Grade	Percentage of improvement	No of patients improved	Percentage of patients improved
0	<25%	3	21.4%
1	25-49%	4	28.5%
2	50-74%	5	35.7%
3	>75%	2	14.28%

Among the 30 patients, 13 (86%) patients in Group A (Microneedling) and 11 (78%) patients in group B (CROSS) noted significant reduction in their acne scar grade. The difference between the 2 groups was statistically insignificant. The percentage improvements in both groups are represented graphically in Figure 4.

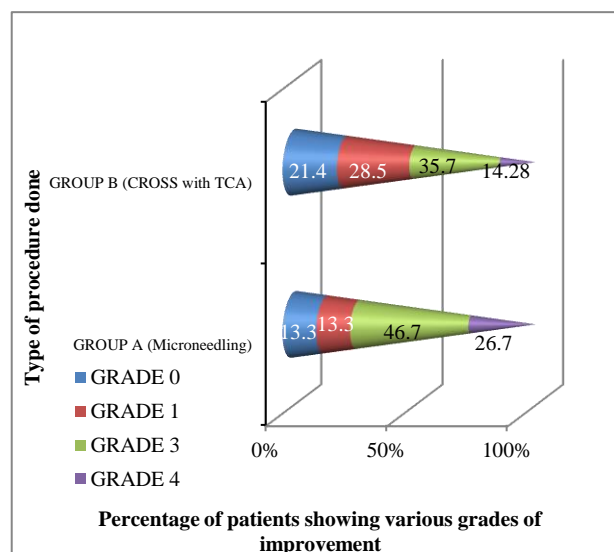


Figure 4: Comparison of percentage improvements of acne scars after microneedling and CROSS with TCA.

No major adverse effect was reported in both the groups. 3 patients had significant post inflammatory hyperpigmentation in group 'B' (Figure 5a and b).

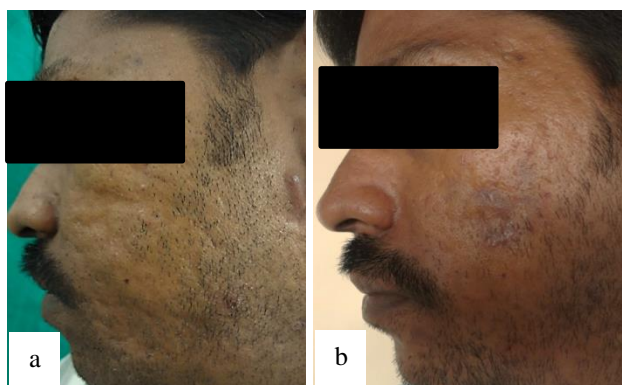

Figure 5 (a and b): Before and after CROSS with TCA- post inflammatory hyperpigmentation.

DISCUSSION

To our knowledge this is the second Indian study comparing the effects of microneedling using dermaroller with CROSS technique using trichloroacetic acid in the management of acne scars.

In our study we observed that both dermaroller and TCA CROSS techniques produced improvement in acne scars in almost all patients. Since only those patients who had more than 25% improvement were taken to have significant improvement, the percentage improvement of scars in group A which underwent microneedling was 86% and that in group B which underwent TCA CROSS was 78%. The difference in percentage improvement of scars between the two groups was statistically insignificant. This is similar to that observed in the study conducted by Leheta et al which also compared the two techniques among Egyptian patients.⁷ In an Indian study conducted by Neerja, there was improvement with both the technique and there was no statistically significant difference in results between the two techniques.⁸ But this study reported overall patient satisfaction with TCA CROSS.

There are many reports available which have studied the effects of each of these techniques individually. The percentage improvement seen in group A, which underwent microneedling using dermaroller for 4 sessions which is 86% is comparable to that of the study done by Imran et al.³ The downtime observed for erythema and edema to subside after the dermaroller procedure was 2-3 days which was similar to that of the study by Fabroccini et al.⁹ The lesser downtime was also reported as an advantage in the study by Fernandes and Signorini et al, in which they reported that the absence of epidermal damage when compared to conventional acne scar treatments like dermabrasion as well as the newer treatments like LASER resurfacing.¹⁰

In our study, we observed that many patients in group 'A' reported improvement in the firmness of the face giving a lifted appearance which was intact for months even after the completion of the study. This effect was also reported in other studies such as that by Imran et al and Aust et al. The firmness was probably due to continuation of deposition of collagen and elastin upto 6 months after the procedure which was confirmed histologically in the study done by Aust et al.¹¹ This lifted appearance provided extra anti-aging effects in our patients. Microneedling can provide both acne scar remodelling and anti-aging benefits in same sitting. This property was also reported by Fernandes et al.¹²

The percentage improvement in group 'B' which underwent TCA CROSS was 78%. The results are in concordance with the study done by Lee et al where they reported an improvement of 68% after 3 sessions of TCA.¹³ The improvement in scars is cumulative with more sessions giving greater percentage improvement. In a study done by Yug et al the percentage improvement was 50.5% after 6 sessions at six weeks interval. But this lesser response after more sessions was probably due to the fact that they had used 65% TCA whereas we had used 100% TCA in our study resulting in better percentage improvement scores.^{5,14}

We observed that among the different types of scars box scars and rolling scars responded well to microneedling therapy whereas the icepick scars responded well to CROSS technique. Same was seen in the study by Neerja.⁸

In our study there was post inflammatory hyperpigmentation observed among 20% of patients who underwent CROSS technique. This could have been because of the concentration of TCA used which was 100%. Also since the study was conducted in south India and the Fitzpatrick skin type of most of the patients was in type IV and V, there was increased tendency for developing post inflammatory hyperpigmentation.

CONCLUSION

The techniques of microneedling and CROSS are both effective in acne scars. When there is more of deep rolling and box scars, microneedling may be preferred. CROSS technique with 100% TCA is more effective in ice pick scars. Both techniques are cost effective; require less resources and safe modalities for management of acne scars. But microneedling scores in other aspects such as faster wound healing, better skin rejuvenation and safety in dark skinned individuals.

ACKNOWLEDGEMENTS

I acknowledge the contributions of Dr. G. R. Ratnavel, (Late), Professor and Head of Department, Department of Cosmetology, Stanley Medical College for his guidance in study design.

Funding: No funding sources

Conflict of interest: None declared

Ethical approval: The study was approved by the institutional ethics committee

REFERENCES

1. Koo J. The psychosocial impact of acne: patients' perceptions. *J Am Acad Dermatol.* 1995;32:26-30.
2. Kim HJ, Kim TG, Kwon YS, Park JM, Lee JH. Comparison of a 1,550 nm Erbium: glass fractional laser and a chemical reconstruction of skin scars (CROSS) method in the treatment of acne scars: a simultaneous split-face trial. *Lasers Surg Med.* 2009;41:545-54.
3. Imran I. Microneedling therapy in atrophic facial scars: an objective assessment. *J Cutan Aesthet Surg.* 2009;2:26-30.
4. Satish D. Microneedling with Dermaroller. *J Cutan Aesthet Surg.* 2009;2(2):110-1.
5. Yug A, Lane J, Howard MS, Lee KH. Focal treatment of acne scars with trichloroacetic acid: chemical reconstruction of skin scars method. *Dermatol Surg.* 2006;28:1017-21.
6. Goodman GJ, Baron JA. Postacne scarring: a qualitative global scarring grading system. *Dermatol Surg.* 2006;32:1458-66.
7. Leheta T, El Tawdy A, Abdel Hay R, Farid S. Percutaneous Collagen Induction Versus Full-Concentration Trichloroacetic Acid in the Treatment of Atrophic Acne Scars. *Dermatol Surg.* 2011;37(2):207-16.
8. Puri N. Comparative study of dermaroller therapy versus trichloroacetic acid CROSS for the treatment of atrophic acne scars. *J Pak Assoc Dermatol.* 2015;15 (2):114-8.
9. Fabbrocini G, Fardella N, Monfrecola A, Proietti I, Innocenzi D. Acne scarring treatment using skin needling. *British association of dermatology. Clin Exp Dermatol.* 2009;34:874-83.
10. Fernandes D. Minimally invasive percutaneous collagen induction. *Oral Maxillofac Surg Clin North Am.* 2006;17:51-63.
11. Aust MC, Fernandes D, Kolokythas P, Kaplan HM, Vogt PM. Percutaneous collagen induction therapy: an alternative treatment for scars, wrinkles, and skin laxity. *Plast Reconstr Surg.* 2008;121:1421-30.
12. Fernandes D, Signorini M. Combating photoaging with percutaneous collagen induction. *Clin Dermatol.* 2008;26:192-9.
13. Lee JB, Chung WJ, Kwahck H, Lee KH. Focal treatment of acne scars with trichloroacetic acid: chemical reconstruction of acne scars method. *Dermatol Surg.* 2002;28:1017-38.
14. Yug A, Lane JE, Howard MS, Kent DE. Histological study of depressed acne scars treated with serial high concentration (95%) trichloroacetic acid. *Dermatol Surg.* 2006;32:985-90.

Cite this article as: Dhollan N, Thirunavukkarasu V. Microneedling vs. chemical reconstruction of skin scars with trichloroacetic acid: a comparative study. *Int J Res Dermatol* 2017;3:277-81.