

Original Research Article

Mucocutaneous infections in HIV positive patients attending a tertiary care institution: a descriptive study

Neethu Haridas¹, Kunnummal Muhammed^{2*}, Sarita S.³

Department of Dermatology & Venereology, ¹Consultant, Kothamangalam Taluk Hospital, Ernakulam, ²Koroth School Road, Vatakara, Kozhikode, ³Associate Professor, Govt. Medical College, Kozhikode, Kerala, India

Received: 10 March 2016

Accepted: 28 March 2017

*Correspondence:

Dr. Kunnummal Muhammed,
E-mail: drmuhammedk@rediffmail.com

Copyright: © the author(s), publisher and licensee Medip Academy. This is an open-access article distributed under the terms of the Creative Commons Attribution Non-Commercial License, which permits unrestricted non-commercial use, distribution, and reproduction in any medium, provided the original work is properly cited.

ABSTRACT

Background: AIDS is characterized by the waning of body's immunity leaving the victim to the multitude of life threatening opportunistic infections, neurological disorders or malignancies. Dermatologic manifestations occur in more than 90% of patients with HIV infection most often due to infections. The awareness of the varied patterns of these skin lesions would help in early diagnosis and management of these in HIV infection, which in turn reduce the morbidity and improve quality of life.

Methods: Observational study from 1st April 2012 to 31st March 2013 in a tertiary care institution of North Kerala. HIV positive patients attending sexually transmitted infection clinic of Dermato venereology department, anti-retroviral treatment clinic (ART clinic) and infectious diseases ward of Department of Medicine of a tertiary care centre were examined after consent for mucocutaneous infections.

Results: The study population comprised of 206 HIV infected patients with mucocutaneous infections. The male to female ratio was 2.07:1. Most of the affected belong to 30-50 years age group. Majority were manual laborers(49.3%) and in stage3 HIV disease. 107 patients had CD4 Count below 350 at the time of study(51.9%) whereas 40 cases (19.4%) had CD4Count above 500. Most common mucocutaneous infection was oral candidiasis (51%), followed by onychomycosis (16.5%). Out of 29 patients with dermatophytosis majority had tinea cruris (18 patients). Bacterial was second commonest infection. Only 3 patients had tuberculoid leprosy, one with type 1 reaction. Common viral infection was herpes zoster followed by herpes genitalis and conylooma acuminata. 11 patients had verruca vulgaris, one with extensive lesions. Out of 206 patients 28 had sexually transmitted infections (STIs) other than HIV, herpes genitalis being the commonest. Syphilis observed in 4 patients (1.9%). 162 patients (78.6%) were on HAART. The response to treatment was better in patients with CD4 Count above 500cells/mm³.

Conclusions: Oral candidiasis, onychomycosis, pyoderma and ulcerative STIs were noted in significant number of HIV infected individuals. These were more common in those with CD4Count below 300 cells/ mm³. Those patients with CD4 Count above 500 cells/ mm³ responded well to treatment.

Keywords: HIV infection, AIDS, Mucocutaneous infections

INTRODUCTION

Acquired immune-deficiency Syndrome (AIDS), is characterised by the waning of body's immunity leaving the victim vulnerable to multitude of life threatening

opportunistic infections, neurological disorders or even rare malignancies.

Dermatologic problems occur in more than 90% of patients with HIV infection and can be the first

manifestation of asymptomatic HIV infection or may indicate advancing immunodeficiency.¹ The various mucocutaneous features in HIV infection range from the macular rash of acute seroconversion syndrome to extensive end-stage Kaposi's sarcoma.² The analysis of mucocutaneous manifestations have showed that in the majority of patients the lesions were due to infections.³ These infections include the conditions seen in immunocompetent patients as well as those seen almost exclusively in the setting of HIV.⁴

In addition, immune reconstitution inflammatory syndrome (IRIS) occurs in 10-25% of HIV seropositive patients started on highly active antiretroviral therapy (HAART). About 52-78% of these cases involve cutaneous features.⁵ Awareness of the varied pattern of these skin manifestations would help in the early diagnosis and management in HIV infection, which would in turn decrease the morbidity and improve the quality of life of these patients.

In this background we thought it worthwhile to carry out a study on the various mucocutaneous infections prevalent among HIV infected individuals and to find out any association of the infection pattern and the CD4 T cell count of the affected.

Aims of the study

1. To study the various mucocutaneous infections in HIV positive patients attending STI clinic under the department of Dermatology & Venereology and the antiretroviral treatment clinic and the infectious disease ward under the department of Medicine in a tertiary care institution.
2. To find out the correlation between various mucocutaneous infections and the CD4 count in patients included in the study.

METHODS

Study design

Observational study

Study period

1st April 2012 to 31st March 2013

Exclusion criteria

Children below 12 years of age and patients who were not willing to participate in the study were excluded.

After obtaining clearance from institutional ethics committee and written informed consent from individual study subject, the patients who satisfied the inclusion criteria were included in the study. A detailed history of the dermatologic complaints of the patients was taken. Past history of similar complaints was also noted. A

thorough examination of the patients was done. The history and the examination details were recorded in a preset proforma. According to the differential diagnoses; relevant investigations were performed to confirm the diagnosis. In bacterial pyodermas, swabs were taken from the site of lesion for gram staining and pus culture and sensitivity. In viral infections like varicella zoster, herpes zoster, herpes labialis and herpes genitalis the diagnosis was confirmed by Tzanck smear from the vesicles and ulcers. In suspected cases of fungal infection, lesional skin scrapings in potassium hydroxide were examined under microscope to confirm the diagnosis.

Speculum examination was done in all patients with vaginal discharge and wet smear, gram staining, and KOH smear were done. Skin biopsy was performed in some patients with atypical presentations who gave consent for the same to confirm the diagnosis. CD4 count of all patients was recorded. Haemoglobin values and Body mass index of all patients were calculated and recorded. An attempt was made to find out any association between CD4 count and mucocutaneous manifestations of the affected.

Analysis method

The data were entered in excel and statistical analysis was performed using Microsoft excel and statistical package for social sciences (SPSS) version 16 for windows. For categorical variables, association was tested using chi square test.

RESULTS

The study population comprised of 206 HIV infected patients with mucocutaneous infections and the male to female ratio was 2.07: 1 (139 males and 67 females). Most of the affected belonged to the age group 30- 50 years (150 patients, Figure 1).

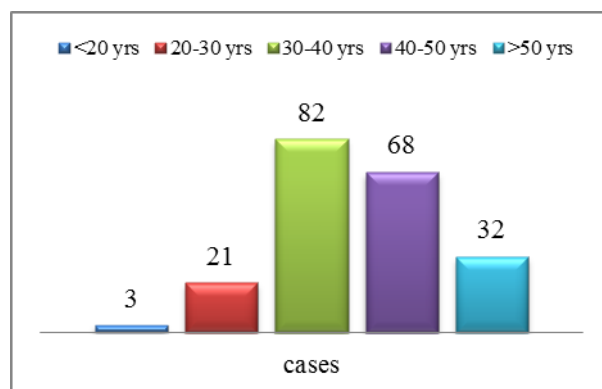


Figure 1: Age distribution of study group.

Majority of the patients were manual labourers (49.3%), followed by housewives (26.1%), drivers (3.0%), people working abroad (2.0%) and commercial sex workers (1.0%). The rest (38%) were occupied otherwise.

Majority of the study subjects had stage 3 HIV disease (43.2%) followed by stage 2 disease (31.1%) [Figure 2]. One hundred and seven patients had a CD4 count below 350 at the time of the study (51.9%) whereas 40 cases (19.4%) had CD4 count above 500.

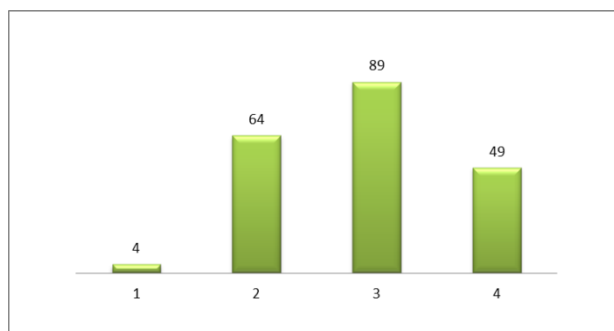


Figure 2: Distribution of HIV patients according to stage of diseases.

The most common mucocutaneous infection observed was oral candidiasis [Table 1], which was seen in 51% of patients, this was followed by onychomycosis in 16.5% of patients and dermatophytosis in 14.1% of patients. Other common mucocutaneous diseases documented in the study group were pyoderma (20%), herpes zoster (7.3%), herpes genitalis (6.3%), condyloma acuminata (5.4%), vulvovaginal candidiasis (5.4%) and verruca vulgaris (5.4%).

Fungal infections were the most common mucocutaneous infections noted in this study. Out of the patients with fungal infections, the most common infection noted was oral candidiasis, 105 (51%) followed by onychomycosis which accounted for 16.5% of the infections. The most common type of oral candidiasis that was noted in this study group was the pseudo membranous type in eighty cases.

Table 1: Mucocutaneous infections in HIV positive individuals.

Sl no	Mucocutaneous infections observed among hiv infected patients	No. Of patients	Percentage
1	Oral candidiasis	105	51
2	Onychomycosis	34	16.5
3	Dermatophytosis	29	14.1
4	Secondary pyoderma	24	11.7
5	Primary pyoderma	18	8.7
6	Herpes zoster	15	7.3
7	Herpes genitalis	13	6.3
8	Condyloma acuminata	11	5.4
9	Vulvovaginal candidiasis	11	16.4
10	Verruca vulgaris	11	5.4
11	Scabies	9	3.9
12	Tinea versicolor	7	3.3
13	Syphilis	5	2.4
14	Molluscum contagiosum	4	1.9
15	Candidal intertrigo	4	1.9
16	Hansen's disease	3	1.5
17	Cutaneous tuberculosis	3	1.5
18	Herpes labialis	3	1.5
19	Candidal balanoposthitis	2	1.4
20	Demodecidiosis	2	1
21	Epidermodysplasia verruciformis	2	1
22	Acute paronychia	2	1
23	Varicella zoster	1	0.5

Out of the 29 patients with dermatophytosis, majority had tinea cruris (18 patients), 6 had both tinea cruris and corporis and 5 had tinea corporis. Absence of central clearing was noted in one patient.

Recurrent infection was noted in one of the 11 patients with vulvovaginal candidiasis. There was no other co-

existent STDs in those patients with vulvovaginal candidiasis.

In patients with onychomycosis toe nails were involved in most of the cases and more than one digit was involved in one patient. Two of the seven patients with tinea versicolor had extensive disease. Interdigital spaces of the

toes were involved in all the 4 cases with candidal intertrigo.

Bacterial infections were second only to the fungal infections in the current study. The primary pyodermas

observed in the study group were folliculitis in nine, furuncle in seven and carbuncle and abscess in one each. Among the patients with secondary pyodermas most of the patients had infected prurigo lesions and some others had infected venous eczema.

Table 2: CD4 and mucocutaneous infections in HIV patients.

Sl no	Mucocutaneous infections observed among HIV infected patients	CD4 Count			Total
		<350	350-500	>500	
1	Oral candidiasis	66 (62.9%)	24 (22.9%)	15(14.3%)	105
2	Onychomycosis	23 (67.6%)	9 (26.5%)	2 (5.9%)	34
3	Dermatophytosis	10 (34.5%)	11 (37.9%)	8 (27.6%)	29
4	Secondary pyoderma	11 (45.8%)	4 (16.7%)	9 (37.5%)	24
5	Primary pyoderma	8(44.4%)	6 (33.3%)	4(22.2%)	18
6	Herpes zoster	4 (26.7%)	9 (60%)	2 (13.3%)	15
7	Herpes genitalis	7 (53.8%)	3 (23.1%)	3 (23.1%)	13
8	Condyloma acuminata	7 (63.6%)	3 (27.3%)	1 (9.1%)	11
9	Vulvovaginal candidiasis	6 (54.5%)	2 (18.2%)	3(27.3%)	11
10	Verruca vulgaris	8 (72.7%)	3 (27.3%)	0	11
11	Scabies	2 (22.2%)	2 (22.2%)	5 (55.6%)	9
12	Tinea versicolor	2 (28.6%)	2 (28.6%)	3 (42.9%)	7
13	Syphilis	2 (40%)	2 (40%)	1 (20%)	5
14	Molluscum contagiosum	2 (50%)	2 (50%)	0	4
15	Candida intertrigo	1 (25%)	1 (25%)	2 (50%)	4
16	Hansen’s disease	0	1 (33.3%)	2 (66.7%)	3
17	Cutaneous tuberculosis	1 (33.3%)	2 (66.7%)	0	3
18	Herpes labialis	1 (33.3%)	2 (66.7%)	0	3
19	Candidal balanoposthitis	1 (50%)	0	1 (50%)	2
20	Demodecidiosis	0	2 (100%)	0	2
21	Epidermodysplasia verruciformis	1 (50%)	1 (50%)	0	2
22	Acute paronychia	0	2 (100%)	0	2
23	Varicella zoster	0	0	1 (100%)	1

Pus culture was done in all patients and staphylococcus aureus was isolated in 30 cases. MRSA was grown in 3 patients and mixed growth was found in 5 patients. Klebsiella , Pseudomonas and Group B streptococci were not isolated in any of the samples . No bacterial growth was found in the rest.

Table 3: CD4 count & response to treatment.

CD4 Count	Response to treatment		Total
	Yes	No	
<350	81 (75.7%)	26 (24.3%)	107 (51.9%)
350-500	45 (76.3%)	14 (23.7%)	59 (28.6%)
>500	37 (92.5%)	3 (7.5%)	40 (19.4%)
Total	163	43	206

All three patients with Hansen’s disease had tuberculoid spectrum of disease and one of them manifested type 1 reaction at the time of diagnosis of leprosy. He presented with type 1 reaction within six months of initiating HAART. One of the three patients with cutaneous tuberculosis had orificial type.

Table 4: Response to treatment with HAART.

HAART	Response to treatment		Total
	Yes	No	
Yes	124 (76.5%)	38(23.5%)	162
No	39 (88.6%)	5 (11.6%)	44
Total	163 (79.1%)	43 (20.9%)	206

The most common viral infection noted among the HIV infected patients in this study was herpes zoster followed by herpes genitalis, condyloma acuminata, and verruca vulgaris. Out of the 15 patients with herpes zoster two had multidermatomal and one had recurrent herpes zoster.

One of the eleven patients who manifested verruca vulgaris had extensive lesions. Among the four HIV positive individuals who manifested molluscum contagiosum, one patient had an atypical presentation as a plaque over the eyelid with no central umbilication and the diagnosis was confirmed by histopathology.

Out of the 206 patients, 28 patients had sexually transmitted infection other than HIV. Herpes genitalis was the most common coexisting STI in the study group (13 patients, 6.3%) followed by condyloma acuminata (5.4%). Syphilis coexisting with HIV was observed in 4 patients (1.9%).

Two patients with herpes genitalis had atypical presentation as raised plaques. Recurrent herpes genitalis was noted among five patients and one patient had lesions lasting for more than one month.

The atypical presentation observed in condyloma acuminata was a giant condyloma in the perianal area noted in one patient. There were 4 patients with syphilis, one patient had primary chancre, another patient had secondary syphilis and two others had late latent syphilis.

Out of the 206 HIV seropositive patients, 162 (78.6 %) were on highly active antiretroviral treatment (HAART). 65.7 % of those on HAART were receiving drugs for more than 6 months duration.

Out of the 206 patients treated for mucocutaneous infections, 79.1% responded to treatment. Response to treatment was noted in 23.5% of those on HAART as against 11.6% of those not receiving HAART. Higher percentage of those with CD4 count above 500 showed response to treatment (92.5%) when compared to those with CD4 count below 500 (approximately 75%).

DISCUSSION

The male predilection observed in the present study was lower than that recorded in the previous studies from Kerala indicating a rise in HIV infection in females.^[6] This could be attributed to the prompt detection of infection in females by the successful contact tracing of the HIV seropositive males attending the HIV clinics and was comparable to the data published by Shah et al.⁷

The age distribution of the study group was concordant to previous data showing predominance of STIs in sexually active age group.⁸ The lower prevalence of HIV among the adolescent age group in the current study may be due to the delayed age of sexual debut in this part of the world.

Predominance of manual labourers among males in the study group could be due to the lack of awareness about HIV and the measures to prevent it among this sector of population and also the increased incidence of sexual promiscuity prevailing among them. Drivers and those working abroad constituting significant percentage of study group was consistent with previous studies since these two groups are more prone for sexual promiscuity considering their respective occupations demanding them to stay away from their families.⁹

Among the females, 76% were housewives. This is consistent with study done by Jindal N.¹⁰ Most of the women in this study were married monogamous women and had acquired the infection from their spouses. The significant percentage of housewives among HIV affected indicates the need to extent the AIDS awareness programmes to low risk groups also.

The low proportion of commercial sex workers among HIV infected, in this study could be a reflection of the efficacy of health education of at risk groups regarding the modes of spread and ways of prevention of HIV and adoption of safe sex practices by them.

Infections were the commonest mucocutaneous lesions among HIV infected individuals as in previous studies.^{10,11}

Our observation of oral candidiasis as the most common mucocutaneous infection in the present study was in concordance with existing literature.^{11,12} Almost 62% of the patients with oral candidiasis in this study had a CD4 count less than 350. The higher prevalence of oral candidiasis noted by us could be due to low CD4 count observed in more than 50% of study group (<350 cells/mm³). Low CD4 count is recognised as a risk factor for oral candidiasis in HIV positives.¹³

Contrary to the expectation, recurrent vulvovaginal candidiasis was seen only in one patient and that patient had a CD4 count of more than 500. The prevalence of genital candidiasis was low in male HIV patients compared to female HIV patients. In this study among the patients with CD4 counts less than 350, 16.4% of females developed vulvovaginal candidiasis whereas only 1.4% of males had balanoposthitis. This could be due to the presence of candidal microflora even otherwise normally in females.

Our observation of dermatophytosis in 14.1% of the study group was consistent with existing data.^{10,11}

Onychomycosis was found in 16.5% of the patients, which is in concordance with other studies.^[14] Majority of the patients with onychomycosis were manual labourers. Also 67% of the patients had CD4 count <350. These findings are supported by the study by Guptha et al who reported that CD4 count around 370 & walking bare foot are increased risk factors for onychomycosis in HIV patients^[14]. Surprisingly, only one patient had involvement of more than one toe nail.

The reported prevalence of pyoderma in the literature was lower than our finding.^{6,10} When both primary and secondary pyodermas in this study are clubbed together, the prevalence of pyodermas is high as 20%. The increased incidence of pyodermas obtained in this study could be due to the fact that majority of the patients in the study were manual labourers, working in unclean, hot and

humid environment. The hot and humid climate in this area would have added to higher risk of infection. Also this section of people will be having less hygiene and therefore were at greater risk bacterial colonization. As in the case of fungal infections, majority of the patients had CD4 count less than 350.

Hansen's disease were found in 3 patients and as reported earlier showed no clinical difference from the same in immunocompetent. It is stated that cellular immunity towards *Mycobacterium leprae* infection remains intact in spite of the low CD4 count.¹⁵ One patient developed type 1 reaction within six months of starting HAART and we believe this to be a manifestation of IRIS following HAART which has been described earlier.¹⁶

The most commonly observed viral infection among the HIV patients was herpes zoster which is in accordance with certain previous studies.¹⁰ The uneventful disease course of herpes zoster in the current study was contrary to the observations that the disease tends to be more aggressive in HIV infected.¹⁷

The prevalence of 3.9% for scabies in the HIV seropositive group noted by us was consistent with the findings of others.¹¹

The relationship between HIV infection and STDs appears to be synergistic. Herpes genitalis in 6.3% of HIV infected, noted by us was comparable to the findings of others.^{3,10,11}

Condyloma acuminata observed in 5.4% of the study group was in concordance with previous reports.^{3,10,11} Our observation of giant condyloma in one HIV positive individual was reported earlier.¹⁸

Coexistence of syphilis with HIV noted in 2% of study population by us was slightly lower than the findings of Kar et al.¹⁹ A higher prevalence is reported by Bhushanam et al.²⁰ The lower percentage of HIV positives with syphilis noted in our study could be attributed to the decline in incidence of syphilis with the widespread use of penicillins for many common ailments.

Similarly, predominance of viral STDs among HIV positives documented by us could be attributed to the wide use of antibiotics, taking care of bacterial STD.

The common mucocutaneous manifestations in HIV by Kore et al were candidiasis, dermatophytosis, HSV infection, herpes zoster pyoderma, and human papilloma virus infection.²¹ These findings are almost consistent with the present study.

CD4 count has immense importance in the setting of HIV, because it is the CD4 receptor that helps the virus to set its domain on the individual, and thereby tampering the immunity of the individual and placing them at the

risk of innumerable diseases which are detrimental to health.

On classifying these infections according to their CD4 count, Kore et al reported that an increase in dermatophytosis, molluscum contagiosum, human papilloma virus infection and pyodermas were noted at CD4 count below 300.²¹ Shobhana et al noted oral candidiasis, herpes zoster, genital herpes and genital wart were more common at low CD4 level around 200.¹¹

In the current study, oral candidiasis was the most common finding in all subset of the CD4 classes with 62% of the infections observed in patients with CD4 <350. The other infections that were prevalent among patients with low CD4 count were pyodermas, onychomycosis and herpes genitalis, comparable to existing data.^{11,21}

This implies that even though CD4 T cells play an important role in immunity, low CD4 count alone is not the only factor that determines the prevalence of all mucocutaneous infections in HIV patients. This is further supported by our observation that certain conditions like secondary pyodermas were present in almost equal or even higher proportions in patients with CD4 count > 500 as compared to those with a low CD4 count. Various factors like genetic predisposition and environmental factors might also be contributing.

Better response to treatment among patients with higher CD4 count documented by us could be attributed to the better immunity associated with high CD4 level. Those with advanced infection and low CD4 count are initiated on HAART and this could be the reason for the relatively lower response of mucocutaneous infections observed in patients receiving HAART.

Main limitation of our study was that it was not designed to include the follow up of the study group; hence we are unable to identify mucocutaneous infections of prognostic significance. Another limitation was the small sample size.

CONCLUSION

With the introduction of HAART and the resultant increase in life expectancy of those with HIV infection, management of coexisting dermatoses in HIV infected assumes great importance. Oral candidiasis, onychomycosis, pyodermas and ulcerative STIs were noted in significant number of HIV infected. Oral candidiasis, onychomycosis and STIs were more common in those with CD4 count below 350cells/ mm³. Though most of the infections responded to treatment, those with CD4 count above 500 had a better prognosis compared to those with CD4 count below 500. More studies on the infectious dermatoses associated with HIV in different population groups may help us to formulate

treatment guidelines for HIV positive individuals manifesting cutaneous infections.

Funding: No funding sources

Conflict of interest: None declared

Ethical approval: The study was approved by the institutional ethics committee

REFERENCES

1. Cockerell C, Friedman-Klein A. Cutaneous signs of HIV infection. *Clin Dermatol.* 1993;4:507-24.
2. Srikanth KP, Vijayakumar S, Aparna, Mallikarjun. A hospital based cross sectional study of mucocutaneous manifestations in the HIV infected. *Int J Collaborative Research on Internal Medicine and Public Health.* 2010;2:50-78.
3. Chopra S, Arora U. Skin and Mucocutaneous Manifestations: Useful Clinical Predictors of HIV/AIDS. *J Clin Diagn Res.* 2012;6:1695-8.
4. Hogan MT. Cutaneous Infections Associated With HIV/AIDS. *Dermatol Clin.* 2006;24:473-6.
5. Osei-Sekyere, B, Karstaedt AS. Immune reconstitution inflammatory syndrome involving the skin. *Clin Exp Dermatol.* 2009;35:477-81.
6. Criton S, Mohan K B, Asokan P U. Dermatological manifestations of human immunodeficiency virus infected / acquired immunodeficiency syndrome patients in a referral hospital of Central Kerala. *Indian J Dermatol Venereol Leprol.* 1995;61:89-9
7. Shah I. Discordant HIV infection among married Indian couples. *Med J DY Patil Univ.* 2015;8:326-7.
8. Ray K, Bala M, Gupta SM, Khunger N, Puri P, Muralidhar. Changing trends in sexually transmitted infections at a Regional STD Centre in north India. *Indian J Med Res.* 2006;124:559-68.
9. Singh RK, Joshi HS. Sexual behaviour among truck drivers. *Indian J Public Health.* 2012;56:53-6.
10. Jindal N, Aggarwal A, Kaur S. HIV seroprevalence and HIV associated dermatoses among patients presenting with skin and mucocutaneous disorders. *Indian J Dermatol Venereol Leprol.* 2009;75:283-6
11. Shobhana A, Guha SK, Neogi D K. Mucocutaneous manifestations of HIV infection. *Indian J Dermatol Venereol Leprol.* 2004;70:82-6.
12. Morgan. D, Mahe C, Mayanja B, James A G Whitworth. Progression to symptomatic disease in people infected with HIV-1 in rural Uganda: prospective cohort study. *BMJ.* 2002;324:193-7.
13. Anwar KP, Malik A, Subhan KH. Profile of candidiasis in HIV infected patients. *Iran J Microbiol.* 2012;4:204-9.
14. Gupta AK, Taborda P, Taborda V, Gilmour J, Rachlis A, Salit I, et al. Epidemiology and prevalence of onychomycosis in HIV-positive individuals. *Int J Dermatol.* 2000;39:746-53.
15. Massone C, Talhari C, Ribeiro-Rodrigues R, Sindeaux RH, Mira MT, Talhari S, et al. Leprosy and HIV coinfection: A critical approach. *Expert Rev Anti Infect Ther.* 2011;9:701-10.
16. George A, Vidyadharan S. Hansen's disease in association with immune reconstitution inflammatory syndrome. *Indian Dermatol Online J.* 2016;7:29-31.
17. Das A L, Sayal S K, Gupta C M, Chatterjee M. Herpes zoster in patients with HIV infection. *Indian J Dermatol Venereol Leprol.* 1997;63:101-4.
18. Yakasai IA, Abubakar IS, Ibrahim SA, Ayyuba R. Unusual presentation of giant condylomata acuminata of the vulva: A case report and review of literature. *Ann Trop Med Public Health.* 2012;5:508-10.
19. Kar H K, Narayan R, Gautam R K, Jain R K, Doda V, S. Mucocutaneous disorders in HIV positive patients. *Indian J Dermatol Venereol Leprol.* 1996;62:283-5.
20. Bhushanam VV, Chokalingam K. STD profile of HIV seropositive cases seen in STD clinic at Raja Multhan Medical College Hospital. *Ind J Sex Transm Dis.* 1993;14:44-5.
21. Kore SD, Kanwar AJ, Vinay K, Wanchu A. Pattern of mucocutaneous manifestations in human immunodeficiency virus-positive patients in North India. *Indian J Sex Transm Dis.* 2013;34:19-24.

Cite this article as: Haridas N, Muhammed K, Sarita S. Mucocutaneous infections in HIV positive patients attending a tertiary care institution: a descriptive study. *Int J Res Dermatol* 2017;3:175-81.