

## Original Research Article

# Oral pemphigus vulgaris: clinicopathological study of 35 cases at a tertiary care centre in North India

Ameesha Mahajan<sup>1\*</sup>, Jasleen Kaur<sup>1</sup>, Mridu Manjari<sup>2</sup>, Saurabh Sharma<sup>1</sup>, Pooja Bains<sup>1</sup>,  
Guneet Awal<sup>1</sup>, Manpreet Kaur<sup>1</sup>, Simplepreet Kaur<sup>1</sup>, Saurabh Chawla<sup>3</sup>

<sup>1</sup>Department of Dermatology, Venereology & Leprosy, <sup>2</sup>Department of Pathology, Sri Guru Ram Das Institute of Medical Sciences & Research, Amritsar, Punjab, India

<sup>3</sup>Department of Health and Family Welfare, Government of Punjab, India

**Received:** 21 February 2017

**Accepted:** 08 March 2017

### \*Correspondence:

Dr. Ameesha Mahajan,

E-mail: [lucky\\_misha@rediffmail.com](mailto:lucky_misha@rediffmail.com)

**Copyright:** © the author(s), publisher and licensee Medip Academy. This is an open-access article distributed under the terms of the Creative Commons Attribution Non-Commercial License, which permits unrestricted non-commercial use, distribution, and reproduction in any medium, provided the original work is properly cited.

## ABSTRACT

**Background:** The purpose of the study was to evaluate the clinical and histopathological features of oral pemphigus vulgaris.

**Methods:** A prospective study of 35 cases of oral pemphigus vulgaris, over a period of 2.5 years from June 2014 to December 2016 in the Department of Dermatology, Sri Guru Ram Das Institute of Medical Sciences and Research, Amritsar was designed. Complete history and detailed mucocutaneous examination was done. Punch biopsy was performed from the oral mucosa and skin lesions (if present). Specimen was sent for histopathological examination and results analysed.

**Results:** Out of 35 patients, 17 (48.57%) were males and 18 (51.42%) were females. Male to female ratio was 1:1.1. The majority of the patients (12, 34.29%) were in the 40-49 year age group. Multiple sites were involved in all patients with bilateral buccal mucosa being involved in all the cases, followed by tongue (30, 85.71%). Histopathological examination showed presence of suprabasal split and acantholytic cells in all cases.

**Conclusions:** Oral ulcers are a presenting feature of pemphigus vulgaris which commonly precede the skin lesions. Histopathological examination enables early diagnosis of the disease which leads to prompt treatment and decreased morbidity.

**Keywords:** Oral ulcers, Oral pemphigus, Pemphigus vulgaris, Autoimmune disease, Histopathology

## INTRODUCTION

Pemphigus is a group of chronic autoimmune diseases characterized by the presence of antibodies against desmosomal proteins. It is derived from the Greek word 'pemphix' meaning blister or bubble. It manifests as mucocutaneous lesions.<sup>1</sup>

It can be classified into 6 types: pemphigus vulgaris, pemphigus vegetans, pemphigus foliaceus, pemphigus erythematosus, paraneoplastic pemphigus and IgA pemphigus.<sup>2</sup>

Pemphigus vulgaris is the most common variant. Nearly all patients have mucosal lesions and they can be the presenting symptom in 50-70% cases. These can precede the cutaneous lesions by months to years or may be the only manifestation of the disease. Intact bullae are rare in the mouth and more commonly patients have ill-defined irregularly shaped buccal or palatal erosions which are slow to heal. The erosions extend peripherally and there occurs shedding of the epithelium. Other mucosal surfaces may be involved, including the conjunctiva, nasopharynx, larynx, oesophagus, urethra, vulva and cervix.<sup>1</sup>

The incidence of pemphigus among the dermatology outpatient attendees varies from 0.09 to 1.8%.<sup>3,4</sup> The peak incidence of pemphigus vulgaris occurs between the fourth and sixth decades of life.<sup>5</sup> Though in India, a significant proportion of patients are younger than 40 years of age.<sup>6</sup>

The diagnosis depends on biopsy confirmation of intraepithelial vesicle formation with suprabasal split, acantholysis and the presence of Tzanck cells.<sup>7</sup> While the precise pathogenesis of pemphigus vulgaris is not clear, acantholysis occurs in presence of antibodies against desmoglein 1, desmoglein 3 and 9- $\alpha$  nicotinic acetylcholine receptor.<sup>8</sup>

## METHODS

A prospective study of 35 cases of pemphigus vulgaris obtained over a period of 2.5 years from June 2014 to December 2016 in the Department of Dermatology, Sri Guru Ram Das Institute of Medical Sciences and Research, Amritsar, was conducted after ethical clearance.

Inclusion criteria were all individuals above 18 years of age, irrespective of sex, willing to undergo oral biopsy. Exclusion criteria were patients below 18 years of age and those who were not willing to undergo biopsy. Thorough history was taken and cutaneous along with intraoral examination was done. Oral punch biopsy was taken after giving local anaesthetic and specimen was sent for histopathological examination to Department of Pathology, Sri Guru Ram Das Institute of Medical Sciences and Research. Photographs were taken for documentation.

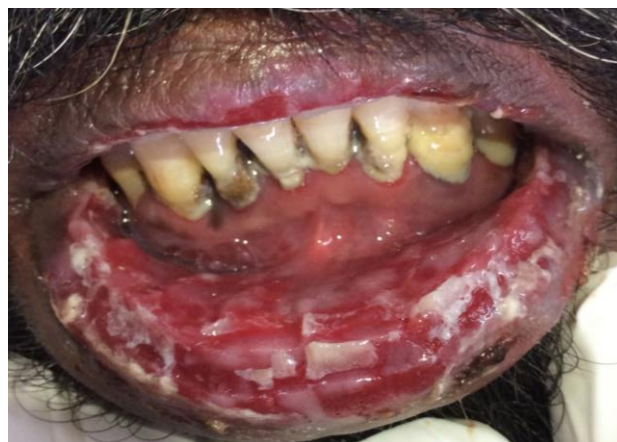## RESULTS

Out of 35 patients, 17 (48.57%) were males and 18 (51.42%) were females. Male to female ratio was 1:1.1. Youngest patient was 20 years old and oldest was 59 years old. The majority of the patients were in the 40-49 year age group i.e. 12 patients (34.29%), followed by 10 (28.57%) patients in 30-39 years age group as shown in Table 1.

**Table 1: Showing age and sex distribution of pemphigus vulgaris patients.**

Age group (years)	Sex			
	Male		Female	
	No.	% age	No.	% age
20-29	2	5.71	2	5.71
30-39	5	14.29	5	14.29
40-49	5	14.29	7	20.00
50-59	5	14.29	4	11.49
<b>Total</b>	<b>17</b>	<b>48.57</b>	<b>18</b>	<b>51.42</b>

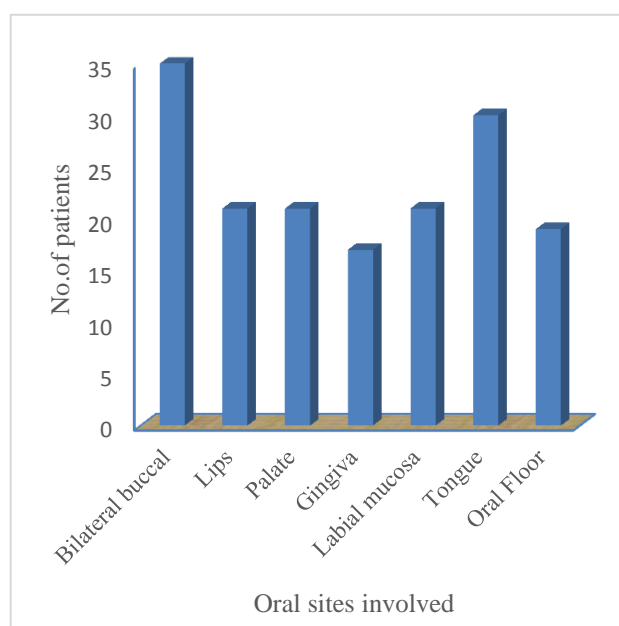
Mean age of presentation was 41.48 years. The mean duration of pemphigus vulgaris was 9.24 months. Nikolsky sign was positive in all cases. In 22.86% (8) cases, oral cavity was the only site of involvement as given in Figure 1.



**Figure 1: Clinical picture of pemphigus vulgaris showing involvement of multiple sittings.**

Out of the rest 27 cases, oral cavity was the primary site of involvement in 20 cases (57.14%). 2 (5.71%) cases presented skin lesions initially and 5 (14.29%) cases presented with simultaneous involvement of the skin and the oral mucosa. All patients had associated pain in the ulcers, burning sensation and difficulty in eating food.

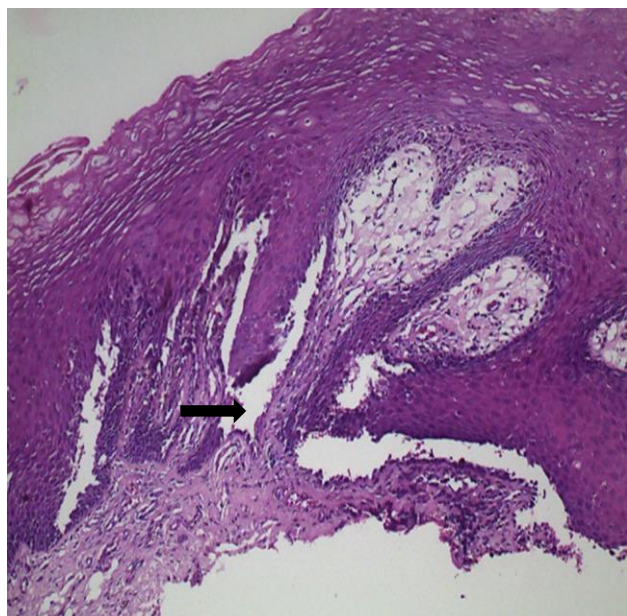
Multiple sites were involved in all patients with bilateral buccal mucosa being involved in all the cases, followed by tongue (30, 85.71%). Palate, lips and labial mucosa was involved in 21 cases (60%) as given in Figure 2.



**Figure 2: Showing frequency of involvement of oral sites.**

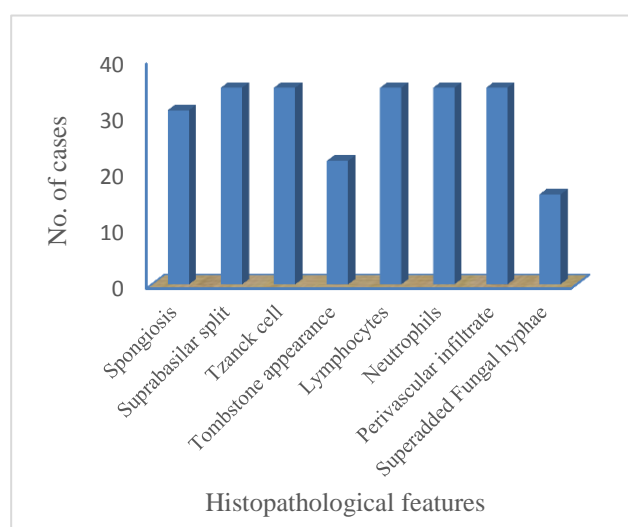
The most common cutaneous sites involved were the trunk (68.57%) followed by scalp (54.29%) and face (37.14%). Other mucosae were involved in 15 cases (42.86%).

Histopathological examination showed presence of suprabasilar split and acantholytic cells in all cases as depicted in Figure 3.



**Figure 3: Histopathology of pemphigus vulgaris showing suprabasal Split (H & E 400X).**

Spongiosis in the lower spinous layer could be appreciated in 88.6% cases. Tombstone appearance of basal cells was seen in 22 cases (62.86%). Dermal infiltrate comprised of neutrophils and lymphocytes along with mixed superficial perivascular infiltrate in all cases as in Figure 4.



**Figure 4: Showing histopathological features of pemphigus vulgaris.**

## DISCUSSION

Oral ulcerative lesions may be the only manifestation or an initial presentation of pemphigus vulgaris. They bring about a great physical, social, and psychological bearing on the patients affected, which is detrimental to them. Histopathology allows early diagnosis of pemphigus vulgaris especially in cases where only oral mucosa is involved. Once diagnosed early, we might cut the root cause of suffering and pain borne by these very patients.

In our study, pemphigus vulgaris presented most frequently in the fifth decade with age varying from 20 years to 59 years with mean age of 41.48 years. These results are consistent with the previous reports of Shamim et al, Iamaroon et al and Camacho-Alonso et al. The male to female ratio in our patients was 1:1.1.<sup>9-11</sup> as given in Table 2.

**Table 2: Showing comparison between various studies on pemphigus vulgaris.**

Parameters	Our study	Shamin et al	Imaroon et al	Camacho-Alonso et al
Number of cases	35	20	18	14
Age group (years)	20-59	20-69	18-55	21-87
Average age (years)	41.48	42.3	37.7	44.78
Duration (months)	1.5-24	1-12	1-98	0.75-72
Average duration (months)	9.24	8	12	11.66
Females	18	12	12	10
Males	17	8	6	4
Female:Male Ratio	1.1:1	3:2	2:1	2.5:1

The gender predisposition in literature has projected contrasting results. Overall, it appears that both sexes are equally affected.<sup>6</sup> Few studies have reported a significant male preponderance (3:1, 3:2) whereas certain studies have shown significant female preponderance (0.8:1, 1:1.2).<sup>12-15</sup> In a study by Babu et al, 71.4% of their cases were females and majority of their patients fell in the age group of 30-40 years. Their results suggested that pemphigus was observed in 7/3,500 dermatological patients during 8 months of their study.<sup>16</sup> Kumar reported incidence of pemphigus to be 4.4/million in Kerala population of India and disease exposure to be high between 40 and 50 years age group.<sup>17</sup>

In our study, skin involvement was seen in 27 cases while other mucosal involvement was seen in 15 cases. Cutaneous lesions showed ulceration and crusting. The oral manifestations initially started as vesicle, which

ruptured, leaving a raw eroded ulcerative area. It involved multiple sites in the oral mucosa. Shamim et al in their study stated that oral cavity was the primary site of involvement from his study on clinical analysis of 71 pemphigus patients.<sup>9</sup>

Since the clinical features of oral pemphigus vulgaris are similar to aphthous ulcers, benign mucous membrane pemphigoid and lichen planus, the diagnosis of pemphigus vulgaris should be confirmed with conventional histology.

Histopathologically, pemphigus vulgaris is characterized by acantholysis and suprabasilar bulla formation. In our study, acantholysis characterised by presence of Tzanck cells and suprabasilar split were seen in all 35 cases (100%). The basal cells lining the floor of the bullae were arranged in a tombstone pattern in 22 cases (62.86%). There were inflammatory cells in the connective tissue stroma chiefly they were lymphocytes and neutrophils (35, 100%). Because of poor oral hygiene, superadded fungal hyphae were seen in 16 cases (45.71%).

## CONCLUSION

Since oral lesions can precede skin lesion in pemphigus vulgaris, their early diagnosis with the help of histopathology helps in initiating timely treatment thus reducing associated morbidity.

*Funding: No funding sources*

*Conflict of interest: None declared*

*Ethical approval: The study was approved by the institutional ethics committee*

## REFERENCES

- Schmidt E, Groves R. Immunobulious Diseases. In: Griffiths C, Barker J, Bleiker T, Chalmers R, Creamer D, editors. Rook's textbook of dermatology. 9th Ed. Singapore: Wiley-Blackwell 2016; 50.1-.57.
- Hashimoto T. Recent advances in the study of the pathophysiology of pemphigus. Arch Dermatol Res. 2003;295(1):2-11.
- Mascarenhas MF, Hede RV, Shukla P, Nadkarni NS, Rege VL. Pemphigus in Goa. J Indian Med Assoc. 1994;92:342-3.
- Kanwar AJ, Ajith C, Narang T. Pemphigus in North India. J Cutan Med Surg. 2006;10:21-5.
- Iamaroon A, Boonyawong P, Klanrit P, Prasongtunskul S, Thongprasom K. Characterization of oral pemphigus vulgaris in Thai patients. J Oral Sci. 2006;48(1):43-6.
- Kanwar AJ, De D. Pemphigus in India. Indian J Dermatol Venereol Leprol. 2011;77(4):439-50.
- Davenport S, Chen SY, Miller AS. Pemphigus vulgaris: clinicopathologic review of 33 cases in the oral cavity. Int J Periodontics Restorative Dent. 2001;21(1):85-90.
- Grando SA. Pemphigus in 21st century. New life to an old story. Autoimmunity. 2006;39:521-30.
- Shamim T, Varghese VI, Shameena PM, Sudha S. Pemphigus vulgaris in oral cavity: Clinical analysis of 71 cases. Med Oral Patol Oral Cir Bucal. 2008;13(10):622-6.
- Iamaroon A, Boonyawong P, Klanrit P, Prasongtunskul S, Thongprasom K. Characterization of oral pemphigus vulgaris in Thai patients. J Oral Sci. 2006;48(1):43-6.
- Camacho-Alonso F, López-Jornet P, Bermejo-Fenoll A. Pemphigus vulgaris. A presentation of 14 cases and review of the literature. Med Oral Patol Oral Cir Bucal. 2005;10(4):282-8.
- Sehgal VN. Pemphigus in India: A note. Indian J Dermatol. 1972;18:5-7.
- Singh R, Pandhi RK, Pal D, Kalla G. A clinicopathological study of pemphigus. Indian J Dermatol Venereol Leprol. 1973;39:126-32.
- Mascarenhas MF, Hede RV, Shukla P, Nadkarni NS, Rege VL. Pemphigus in Goa. J Indian Med Assoc. 1994;92:342-3.
- Kanwar AJ, Ajith C, Narang T. Pemphigus in North India. J Cutan Med Surg. 2006;10:21-5.
- Babu RA, Chandrashekhara P, Kumar KK, Reddy GS, Chandra KLP, Rao V, et al. A study on oral mucosal lesions in 3500 patients with dermatological diseases in south India. Ann Med Health Sci Res. 2014; 4(2):84-93.
- Kumar KA. Incidence of pemphigus in Thrissur district, South India. Indian J Dermatol Venereol Leprol. 2008;74:349-51.

**Cite this article as:** Mahajan A, Kaur J, Manjari M, Sharma S, Bains P, Awal G, et al. Oral pemphigus vulgaris: clinicopathological study of 35 cases at a tertiary care centre in North India. Int J Res Dermatol 2017;3:192-5.