

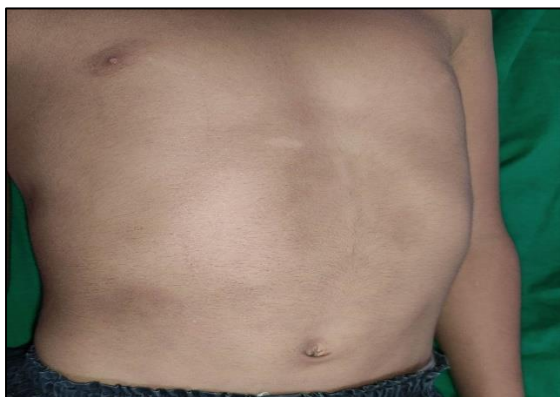## Letter to the Editor

# Idiopathic localised involutinal lipoatrophy in a child involving multiple sites

Sir,

Idiopathic localized involutinal lipoatrophy (ILIL) is a rare form of localized lipoatrophy that arises spontaneously without inflammation.

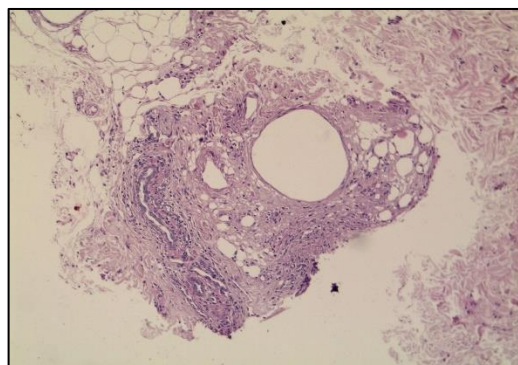
A 6 year old boy presented with depressed skin lesion involving trunk since 3 years. No history of previous trauma, drug intake, injections or prior inflammatory conditions. On examination, well demarcated, non-tender, non-indurated, depressed pigmented plaque seen over centre of abdomen of size 10x7 cm, right side of chest of size 5x4 cm (Figure 1) and over back of size 6x4 cm. A differential diagnosis of morphea and lipoatrophy was made. Routine hematological, biochemical investigations, fasting blood sugar, serum triglycerides, serum TSH and ANA were normal. Ultrasonography of depressed skin lesions showed thinning of subcutaneous plane with increased echoes in right posterior thorax.



**Figure 1: Well demarcated, non-tender, non-indurated, depressed pigmented plaque seen over centre of abdomen of size 10x7 cm, right side of chest of size 5x4 cm.**

Biopsy from the depressed lesion showed epidermis exhibiting basket weave keratin, mild papillomatosis and acanthosis. Papillary and upper dermis showed mild perivascular lymphocytic infiltrate with occasional eosinophils. Dermal collagen fibres are normal, pilo sebaceous gland appear small with other adnexal structures. There is loss of subcutis with shrunken fat globules, within the lobule, adipocytes appear reduced in size, number, with some dilated fat spaces and many tiny adipocytes. Fibrosis, mild infiltrate of lymphocytes, histiocytes, foamy macrophages observed around fat

(Figure 2). As there was no history suggestive of preceeding inflammatory process, normal laboratory findings and classical histopathological involutinal changes, a final diagnosis of idiopathic localized involutinal lipoatrophy was made.



**Figure 2: Loss of subcutis with shrunken fat globules, within the lobule, adipocytes appear reduced in size, number, with some dilated fat spaces and many tiny adipocytes. (H and E, X10).**

ILIL is characterized by selective loss of subcutaneous fat without exudative reaction or fibrosis. It is more common in young females, usually solitary and very few childhood cases have been reported. Pathogenesis is unclear and literature suggests impairment of adipocyte differentiation, adipocyte apoptosis, and mitochondrial dysfunction.<sup>1</sup> Activated macrophages trigger immunologic disorders by secreting variety of cytokines such as fibroblast growth factor-2, platelet-derived growth factor, interleukin-1, tumor necrosis factor- $\alpha$ , and transforming growth factor- $\beta$ , resulting in involution of subcutaneous fat tissue.<sup>2</sup>

Clinically localized involutinal lipoatrophy, presents as an asymptomatic, well demarcated, localized, non-inflamed atrophic depression affecting only one site and commonly involve arms, buttocks, thighs and abdomen. In our case multiple sites were involved. Histologically as seen in our case, ILIL lesions show well developed involutinal changes, exhibiting shrunken fat lobules with retraction of whole fat lobules from surrounding collagenous septa. Within each affected fat lobule, lipocytes are shrunken and retracted resembling embryonic fat tissue.<sup>3,4</sup> ILIL was differentiated from morphea which exhibits pronounced inflammatory infiltrate in subcutaneous fat, and the trabeculae dividing the subcutaneous fat are thickened because of inflammation and deposition of new Collagen.<sup>4</sup> Majority

of cases resolve spontaneously. Anti-inflammatory agents such as steroids, calcineurin inhibitors, and antimalarials can be used in the initial phase when the lesion is expanding.<sup>5</sup> In long-standing lesions, localized fat transplantation may be performed.

We report this case for its rarity, as the child presented with ILIL involving multiple sites. Although skin lesions can resolve spontaneously without treatment, currently in our case the lesions persisted without progression.

**Nithya V. P. S.<sup>1</sup>, Reena Rai<sup>1</sup>, Umamaheswari G.<sup>2</sup>**

<sup>1</sup>Department of Dermatology, <sup>2</sup>Department of Pathology, PSGIMSR, Coimbatore, Tamil Nadu, India

**\*Correspondence to**

Dr. Reena Rai

Email: drreena\_rai@yahoo.co.in

## REFERENCES

1. Giralt M, Domingo P, Villarroya F. Adipose tissue biology and HIV-infection. *Best Pract Res Clin Endocrinol Metab.* 2011; 25(3):487-99.
2. Sharma RK, Gupta M, Negi L. Idiopathic Localized Involutional Lipoatrophy: A Retrospective Study of 12 Cases. *Indian Dermatol Online J.* 2019;10(2):149-52.
3. Fung MA, Requena L. Inflammatory diseases of subcutaneous fat. In: Elenitsas R, Rosenbach M, Murphy GF, Rubin AI, Xu X, editors. *Lever's histopathology of the skin.* 11th ed. Wolters Kluwer: Philadelphia. 2015;610-58.
4. Chang CH, Fang KT, Hong SJ. Morphea-like localized involutional lipoatrophy—a case report associated with family history. *Dermatol Sinica.* 2010;28:113-6.
5. Pai K, Pai S. Localised involutional lipoatrophy: a case report. *Our Dermatol Online.* 2013;4(3):356-7.

**Cite this article as:** Nithya VPS, Rai R, Umamaheswari G. Idiopathic localised involutional lipoatrophy in a child involving multiple sites. *Int J Res Dermatol* 2021;7:753-4.