

Original Research Article

Evaluation of glycolic acid and trichloroacetic acid peels in the treatment of melasma

Bikkasani U. P. Lakshmi Kishan Rao*, K. Satyanarayana Rao

Department of DVL, Mamata Medical College, Khammam, Telangana, India

Received: 16 June 2021

Accepted: 03 July 2021

***Correspondence:**

Dr. Bikkasani U. P. Lakshmi Kishan Rao,

E-mail: druma20@gmail.com

Copyright: © the author(s), publisher and licensee Medip Academy. This is an open-access article distributed under the terms of the Creative Commons Attribution Non-Commercial License, which permits unrestricted non-commercial use, distribution, and reproduction in any medium, provided the original work is properly cited.

ABSTRACT

Background: Melasma is a chronic acquired hypermelanosis of the skin mainly affecting women. The etiopathogenesis of melasma is not fully understood but multiple factors like genetic influences, sunlight exposure, pregnancy, estrogen ingestion and family history are implicated. The present study was aimed to evaluate the therapeutic, efficacy of glycolic acid (GA) and trichloroacetic acid (TCA) superficial chemical peels in melasma patients.

Methods: Fifty patients with clinically diagnosed melasma of either sex attending the outpatient clinic of department of dermatology of Mamata medical college and hospital, Khammam during the period of April 2007 to March 2008 constituted the subject material.

Results: Distribution of melasma patients by duration of lesions showed the duration varied from 6 months to 6 years in both the groups, the difference in the duration of disease in two groups was statistically non-significant. Whereas site involvement showed malar region (96%) was the most commonly affected site followed by forehead (80%) and chin (20%). Study also showed sunlight was the main precipitating factor and the most frequent Fitzpatrick skin phototype was type V. The majority of cases in both the groups pigmentation was homogenous. In both the groups, at the end of three peels, it was observed that maximum cases had moderate improvement. Burning sensation was significantly high in group B compared to group A, erythema was seen in more in group B.

Conclusions: This study proposes to combine both their modalities of chemical peels for better results TCA peels are used initially to get prompt response and then followed by GA peels to further reduce the pigmentation and maintain the effect.

Keywords: Melasma, Fitzpatrick, MASI scoring, Glycolic acid and trichloroacetic acid

INTRODUCTION

Melasma or chloasma is an acquired pigmentary disorder of the face that manifests as symmetric hyper pigmented macules usually over the forehead, cheeks, around eyelids and chin in a mask like distribution.¹ The eponym chloasma is derived from the Greek word chloazein meaning to be green. The condition is more commonly seen in women seen in women with dark complexion of Fitzpatrick skin types (IV and V), especially those living in areas of intense radiation.² The etiopathogenesis of

melasma is not fully understood but multiple factors like genetic influences, sunlight exposure, pregnancy, estrogen ingestion and family history are implicated.

In melasma morphologically the pigmentation is seen in three clinical patterns, that is, centrofacial, malar, mandibular.³ Examination of pigmentation in melasma under Wood's light (wave length 365 nm) helps to determine the location of melanin in the skin as epidermal (more prominent) and dermal types (no enhancement). In visible light epidermal pigmentation

appears brown or black while dermal appears blue in colour due to tyndal effect.⁴

Histologically under light microscopy, three types of melasma are recognized, namely epidermal that has increased melanin predominantly in basal and supra basal epidermis; dermal type that has melanin laden macrophages with in dermis and mixed type featuring both epidermal and dermal pigmentation.⁵ Melasma is a therapeutically challenging condition. Response to the treatment remains incomplete despite various treatment options are available including broad spectrum sunscreens, hypo pigmenting agents like hydroquinone and azelie acid, combination therapies, chemical peels, microdermabrasion and lasers.⁶

Chemical peeling of the skin is one of the new therapeutic armamentariums for melasma. It has been used since time immemorial to smoothen and improve skin texture. It is becoming popular treatment modality in recent years because it is a simple and safe office procedure that requires minimal technical expertise with less minimal side effects.

Chemical peeling produces a controlled destruction of the epidermis or dermis with subsequent re-epithelization by secondary intention.⁶ Among various agents used for chemical peeling, the most important ones are alpha hydroxy acids such as GA, mandelic acid, β -hydroxy acids such as salicylic acid, TCA, phenol, Baker-Gordon's formula, Jessner's solution, resorcinol and carbon dioxide snow.⁷ Chemical peeling results in skin rejuvenation with partial or complete disappearance of actinic changes, wrinkles, pigmentar, dyschromias and depressed scars.⁸

GA and TCA chemical peels have been used along and in combination to treat melasma, however no studies have been carried out on this subject from this part of the country, as far as ascertained. Despite melasma is one of the most common skin problems encountered.⁹

Hence the present study was planned to evaluate the therapeutic, efficacy of GA and TCA superficial chemical peels in melasma patients.

METHODS

Fifty patients with clinically diagnosed melasma of either sex attending the outpatient clinic of department of dermatology of Mamata medical college and hospital, Khammam during the period of April 2007 to March 2008 constituted the subject material.

Study design

A detailed dermatological examination was carried out and the morphology, extent and anatomical location of the lesions were recorded. Based on examination under natural light, the lesions were classified as light brown,

medium brown, dark and bluish-grey in colour. A further division into epidermal or mixed was made using Wood's lamp. An informed consent was taken from all the patients before the procedure after explaining the benefits, side-effects and risks associated with the procedure.

Fifty patients were randomly assigned 25 each in 2 groups (A and B). Group A: this group of individuals were treated with GA peels only and group B: this group of individuals were treated with TCA peels only.

After the treatment, each group severity was assessed by MASI scoring. Priming was carried out by each patient with sun screen (day time) and 5% hydroquinone and 0.025% acid once daily at night time over the lesions for 2 weeks at home before the planned by of peel. The use of priming agents was stopped one day prior to the first peel. Patients were advised to report any adverse effects to the priming agent.

Test peel

Test peel was done with 20% GA/10% TCA in a small 2–3-centimeter circular or square area in the retro auricular region, 2 weeks prior to carrying out full face peeling so as to detect any adverse reaction to the peeling agent, make the patient familiar with the sequelae of the procedure and to use period to prime the skin.

Priming

Patients in groups A and B were advised to apply their respective priming agents (hydroquinone 2% or retinoic acid 0.025%) once daily at night time over the lesions for two weeks at home before the planned day of peel. The use of priming agents was stopped one day prior to the first peel. Patients were advised to report any adverse effects to the priming agent.

Statistical analysis

Statistical analysis of the results was done by calculation the average MASI scores for the 2 groups and evaluation the percentage change in the average MASI scores was done before each peel and thirty days after last peel of treatment, using unpaired t test and one way ANOVA tests. A p value of less than 0.05 was considered significant.

RESULTS

The present study was done to assess the efficacy of GA and TCA chemical peeling in 50 patients of melasma fulfilling the selection criteria. The clinic epidemiologic profile of melasma was recorded and the therapeutic benefit of GA and TCA peeling was assessed among the patients. Patients were randomly allocated into 2 groups A and B. Patients in group A underwent peeling with GA and group B with TCA peels were evaluated.

Patients in both groups had a varied duration of disease. In both the groups, the duration varied from 6 months to 6 years (Table 1). The mean duration of disease in group A was 3.92 ± 2.55 years and in group B was 4.00 ± 2.57 years. Thus, the difference in the duration of disease in two groups was statistically non-significant.

In group A, malar region (96%) was the most commonly affected site followed by forehead (80%) and chin (20%). In group B, similarly, malar region (100%) was most commonly affected site followed by forehead (60%) and nose (36%). No significant statistical difference was found in two groups, regarding the site affected (Table 2).

Majority of our patients exhibited a centrofacial pattern (72%). Malar pattern was seen in 28% while none of the patients had a mandibular pattern (Figure 1).

In group A, sunlight was the main precipitating factor in 18 (72%) cases followed by pregnancy in 10 (40%) cases, cosmetics in 2 (8%) cases, family history in 2 (8%) cases, drugs 2 (8%) cases and thyroid 2 (8%) cases.

In group B, similarly, sunlight was the main precipitating factors in 19 (76%), cases followed by pregnancy in 10 (40%) cases, cosmetics 1 (4%) cases, drugs (OCP's) 5 (20%) cases, thyroid 2 (4%) cases and family history 2 (8%) cases (Table 3).

The most frequent Fitzpatrick skin phototype was type V (71.4%) followed by type IV (28.6%). None of the patients had skin phototypes I, II, III and VI (Figure 2).

Majority of the patients in group A is 1-3 cms and group B is >3 cms. Maximum number of patients presenting for treatment had 2-4 patches (56%) or more than 4 patches (36%) (Table 4).

In group A majority 18 (72%) cases pigmentation was homogenous at some places and speckled at other places. Uniformly homogenous pattern was seen in 6 (24%) while only speckled pattern occurred in 1 (4%) cases.

In group B majority 17 (68%) cases pigmentation was homogenous at some places and speckled at other places. Uniformly homogenous pattern was seen in 4 (16%) only speckled patterns occurred in 4 (16%) cases (Table 5).

In group A, accentuation of pigment under Wood's lamp was seen in 16 (64%) patients signifying an epidermal location of pigment, no enhancement occurred in 5 (20%) indicative of dermal pigment while mixed results were seen in 4 (16%) (Table 6).

In group B, accentuation of pigment under Wood's lamp was seen in 14 (56%) patients signifying an epidermal location of pigment, no enhancement occurred in 4 (16%) indicative of dermal pigment while mixed results were seen in 7 (28%) (Table 6).

Table 1: Distribution of melasma patients by duration of lesions.

Duration (in years)	Group A (%)	Group B (%)
>1	1 (4)	1 (4)
1-3	11 (44)	12 (48)
>3	13 (52)	12 (48)
Range of duration	6 months to 6 years	6 months to 6 years
Mean \pm SD	3.92 ± 2.55	4.00 ± 2.57

t value=0.11, p>0.05 NS.

Table 2: Distribution of melasma patients by site of involvement.

Sites	Group A (%)	Group B (%)	Z value	P value
Forehead	20 (80)	15 (60)	1.54	>0.05 NS
Malar area	24 (96)	25 (100)	1.01	>0.05 NS
Nose	5 (20)	9 (36)	1.26	>0.05 NS

Table 3: Precipitating factors of melasma in group A and group B.

Precipitating factors	Group A (%)	Group B (%)	P value
Sunlight	18 (72)	19 (76)	>0.05 NS
Pregnancy	10 (40)	11 (44)	>0.05 NS
Drugs (OCP's)	2 (8)	5 (20)	>0.05 NS
Thyroid disease	2 (8)	1 (4)	>0.05 NS
Cosmetics	2 (8)	1 (4)	>0.05 NS

Table 4: Distribution of melasma patients according to the number of patches.

Number of patches	Group A and B	Percentage (%)
<2	4	8
2-4	28	56
>4	18	36
Total	50	100

Table 5: Distribution of melasma patients by pattern of pigmentation and size of the lesions in group A and group B.

Pattern of pigmentation	Group A (%)	Group B (%)
Homogenous	6 (24)	4 (16)
Homogenous+speckled	18 (72)	17 (68)
Speckled	1 (4)	4 (16)
Size of the lesions (in cms)		
<1	0	0
1-3	14 (56)	12 (48)
>3	11 (44)	13 (52)

Table 6: Distribution of melasma patients according to the nature of the lesions colour under natural light.

Wood's lamp	Group A (%)	Group B (%)
Epidermal	16 (64)	14 (56)
Dermal	5 (20)	4 (16)
Mixed	4 (16)	7 (28)
Colour		
Light brown	6 (24)	10 (24)
Medium brown	12 (48)	9 (36)
Deep brown	7 (28)	5 (20)
Bluish grey	0	1 (4)

Table 7: Average MASI scores in group A and B.

Groups	No. of patients	Average MASI scores			
		At pre-peel	At the end of 1st peel	At the end of 2nd peel	At the end of 3rd peel
Group A	25	13.20±3.54	11.46±3.31	10.30±3.29	9.16±3.45
Group B	25	12.88±3.43	10.49±3.38	9.01±3.00	8.18±3.00
Total	50	13.04±3.48	10.97±3.34	9.65±3.14	8.67±3.22

Table 8: Overall clinical response in group A and B after 3 peels.

Responses (%)	Group A (%)	Group B (%)	P value
Good (50-75)	3 (12)	3 (12)	>0.05 NS
Moderate (25-50)	13 (52)	19 (76)	<0.10 Sig
Mild (<25)	9 (36)	3 (12)	<0.05 Sig
Poor	0 (0)	0 (0)	0 (0)

Table 9: Side effects observed during chemical peeling in group A and group B.

Reactions	Group A (%)	Group B (%)
Burning sensation	11 (24)	15 (50)
Erythema	8 (32)	14 (56)
Desquamation	4 (16)	6 (24)
Herpes labialis	1 (4)	0
Post inflammatory hyper or hypo pigmentation	0	0

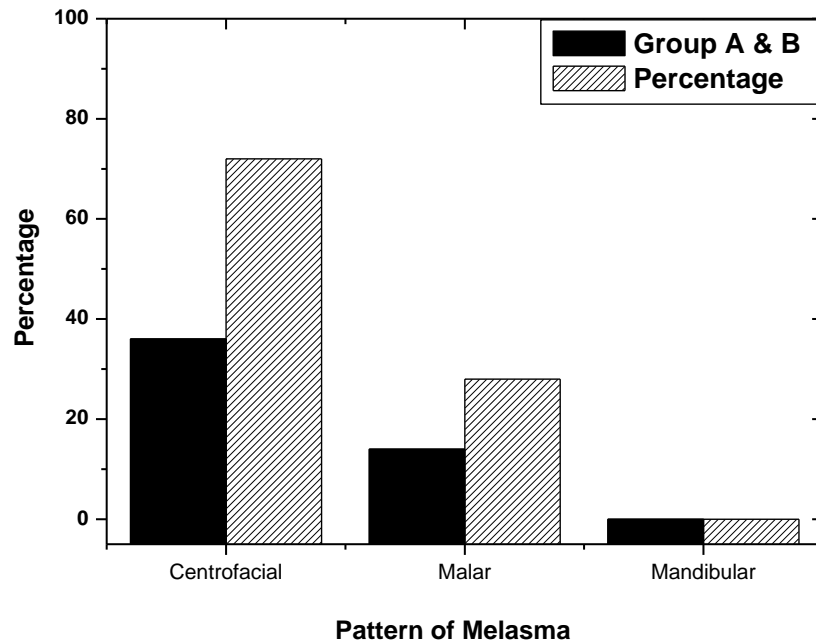


Figure 1: Distribution of melasma patients by anatomical pattern of melasma.

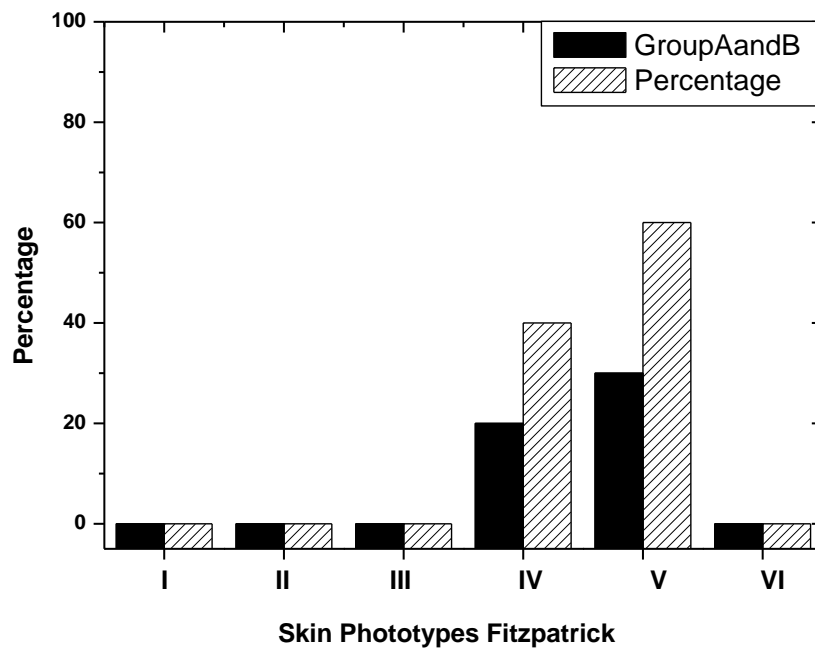


Figure 2: Distribution of melasma patients by skin phototypes.

Majority of our patients had a medium brown colour of melasma lesions under natural light as observed (Table 6).

In both A and B groups, there was constant decrease in MASI scores after each peel as compared to the pre-peel scores (Table 7).

In group A, at the end of three peels, it was observed that maximum cases (52%) had moderate improvement. This was followed by mild improvement in 36% cases and good response seen in 12% cases. Similarly in group B, at the end of three peels, it was observed that maximum cases, 76% had moderate improvement followed by mild and good response seen in 3% cases each (Table 8).

Burning sensation was significantly high in group B compared to group A, erythema was seen in more in group B. Only one case developed herpes labialis. None of the cases developed post-inflammatory hyperpigmentation or hypo pigmentation following the peel in both the group (Table 9).

DISCUSSION

Melasma is one of the common pigmentary anomalies of the skin it is characterized clinically with the occurring of localized symmetric hypermelanosis of the face predominantly in young females and usually exacerbated by sunlight and artificial UVA and UVB. In the present study we correlated the efficacy of GA with TCA chemical peeling in the treatment of melasma. In the present study the main precipitating factor was sunlight. This was consistent with the findings of Javaheri et al also reported sun exposure.¹⁰ Similar observations were also found that aggravating factors in melasma were pregnancy, sun exposure, hormonal therapy and cosmetics.¹¹ These factors corroborate well with factors in the present study.

The present study shows that cosmetic is one of the significant factors in the etiopathogenesis of melasma. This may be due to their indiscriminate use in this modern area where our results are in accordance with study done by Grimes where cosmetics as one of the important factors in the etiopathogenesis of melasma.¹²

Present study showed no statistically significant difference when the pre-peel MASI scores of the two groups were compared. In group A, the MASI came down following three was also found to be statistically significant. Whereas on comparing the two groups, reduction of MASI score was found to be statistically insignificant these findings are in agreement with study done by Sarkar et al.¹³

On studying the percentage improvement in MASI the difference in the percentage reduction of MASI in the two groups was found to be statistically insignificant. The overall therapeutic response with regards to percentage reduction in MASI and grades of improvement was compared in both the groups, the overall clinical improvement was better in group B however this difference was statistically insignificant. In previous study by Kalla et al observed that glycolic acid group required a greater number of peels as compared to TCA group.¹⁴ This finding corroborates with the observation in the present study.

Chun et al reported a good clinical response in 55% patients of melasma with TCA as compared to 12% in the present study.¹⁵ Also, Gupta et al reported maximum beneficial effects with 52% glycolic acid for 3 minutes in melasma.¹⁶ The results being well consistent with that of the present study. Kalla et al in their study also showed an inverse relationship between duration of disease and

therapeutic response, that is, less improvement in patients' long duration of pigmentation. Also, their study showed that in patients with disease duration of 1-3 years, response with TCA was more whereas GA was more effective when duration of onset was <1 year.

Side effects during peeling in both the groups was that, in group A, burning sensation and erythema were seen in each of 44% cases. In group B, burning sensation and erythema were seen in 52% and 56% cases, respectively. The difference in both of these reaction in the two groups was found to be statistically significant which is consistent with the Sarkar et al, Gupta et al reported only focal erythema and mild burning during the GA peels, in their study.

Kalla et al in their study observed relapse in 8% cases and hyperpigmentation in 4% cases. They further observed that relapse and hyperpigmentation were 25% with TCA as compared to 5.9% in GA, during follow up period of 3 months. Grover et al reported complications in the form of post inflammatory hyperpigmentation (2 patients) and hypo pigmentation (1 patient) following GA peels out of 41 patients included in their study. However, no significant complications were observed by Chun group with TCA peels in melasma, similar to the findings noted in our study.

In a study conducted by Kala group, TCA patients experienced more local irritant effects like tingling, burning sensation and post peel desquamation as compared to GA thus tolerability profile of glycolic acid peels was found to be better as regards the local irritant reaction.

From the observations of the present study the precipitating factors of melasma are sunlight, pregnancy, followed by cosmetics. Melasma is a female predominant, affecting young adults including the malar and forehead with centrofacial pattern of involvement with type IV and V Fitzpatrick skin types. Both GA and TCA are equally effective as peeling agents in treatment of melasma, although the response with TCA was rapid initially and tolerability in terms of less local irritant reactions is better with GA peels than TCA.

Limitations

Limitations of our study were observer bias in the MASI scoring which was eliminated conducting scoring by a single-blinded independent person to observe the response to chemical peeling to both TCA and GA.

CONCLUSION

To conclude from the observations of the present study both GA and TCA were equally effective as peeling agents in treatment of melasma, although the response with TCA was rapid initially and tolerability in terms of less local irritant reactions is better with GA peels than

TCA. Further this study proposes to combines both their modalities of chemical peels for better results TCA peels are used initially to get prompt response and then followed by GA peels to further reduce the pigmentation and maintain the effect.

Funding: No funding sources

Conflict of interest: None declared

Ethical approval: The study was approved by the institutional ethics committee

REFERENCES

1. Pathak MA, Fitzpatrick TB, Kraus EW. Usefulness of retinoic acid in the treatment of melasma. J Am Acad Dermatol. 1986;15:894-9.
2. Sanchez NP, Pathak MA, Sato S, Fitzpatrick TB, Snachez JL, Mihm MC. Melasma: a clinical, light microscopic, ultra-structural and immunofluorescence study. J Am Acad Dermatol. 1981;4(6):698-710.
3. Vacquez M, Maldonado H, Banaman C, Sanchez JL. Melasma in men: a clinical and histologic study. Int J Dermatol. 1988;27(1):25-7.
4. Gilchrist BA, Fitzpatrick TB, Anderson RR, Parrish JA. Localization of melanin pigmentation in the skin with Wood's lamp. Br J Dermatol. 1977;96(3):245-8.
5. Lever WF, Schaumburg LG. Pigmentary disorders. Histopathology. 7th ed. Philadelphia, PA: JB Lippincott; 1983: 448-93.
6. Thappa DM. Melasma (chloasma): a review with current treatment options. Indian J Dermatol. 2004;49(4):165-76.
7. Baumann L. Chemical peeling cosmetic dermatology. Principles and Practice. In: Baumann L, eds. 1st ed. New York: Mc Graw Hill Companies; 2002: 173-86.
8. Savant SS, Mehta N. Superficial and medium depth chemical peeling. In: Savant SS, Atal-Shah R, Gore D, eds. Textbook and Atlas of Dermatosurgery and Cosmetology. 1st ed. ASCAD Publishers; 1998.
9. Coleman WP, Futrell JM. The glycolic acid trichloroacetic acid peel. J Dermatol Surg Oncol. 1994;20(1):76-80.
10. Javaheri SM, Handa S, Kaur I, Kumar B. Safety and efficacy of glycolic acid facial peel in Indian women with melasma. Int J Dermatol. 2001;40(5):354-7.
11. Handel AC, Miot LDB, Miot HA. Melasma: a clinical and epidemiological review. An Bras Dermatol. 2014;89(5):771-82.
12. Grimes PE. Melasma: etiologic and therapeutic consideration. Arch Dermatol. 1995;131(12):1453-7.
13. Sarkar R, Kaur C, Bhalla M, Kanwar AJ. The combination of glycolic acid peels with a topical regiment in the treatment of Melasma in Dark skinned patients: a comparative study. Dermatol Surg. 2002;28(9):828-32.
14. Kalla G, Anush G, Kachhawa D. Chemical peeling- Glycolic acid versus trichloroacetic acid in melasma. Indian J Dermatol Venereol Leprol. 2001;67(2):82-4.
15. Chun YE, Lee JB, Lee KH. Focal trichloroacetic acid peel method for benign pigmented lesions in dark skinned patients. Dermatol Surg. 2004;30:512-6.
16. Gupta RR, Mahajan BB, Garg G. Chemical peeling: Evaluation of glycolic acid in varying concentrations and time intervals. Indian J Dermatol Venereol Leprol. 2001;67(1):28-9.

Cite this article as: Rao BUPLK, Rao KS. Evaluation of glycolic acid and trichloroacetic acid peels in the treatment of melasma. Int J Res Dermatol 2021;7:623-9.