

## Original Research Article

# A study on the cutaneous manifestations of patients with internal malignancy attending a cancer center in Kanyakumari District

Nivin Simon, Mulamoottil George Varghese, A. J. S. Pravin\*, M. K. Padmaprasad, S. Rajagopal, M. Vijayabharathi, Sushma I.

Department of Dermatology, Sree Mookambika Institute of Medical Sciences, Kanyakumari, Tamil Nadu, India

**Received:** 15 June 2021

**Accepted:** 31 July 2021

### \*Correspondence:

Dr. AJS Pravin,

E-mail: [pajspravin@gmail.com](mailto:pajspravin@gmail.com)

**Copyright:** © the author(s), publisher and licensee Medip Academy. This is an open-access article distributed under the terms of the Creative Commons Attribution Non-Commercial License, which permits unrestricted non-commercial use, distribution, and reproduction in any medium, provided the original work is properly cited.

## ABSTRACT

**Background:** Cutaneous metastasis from an internal malignancy is rare and usually occurs at the later stages. Cutaneous changes may also be the presenting feature of some underlying malignancies. To determine the frequency of cutaneous manifestations in cancer patients attending the Cancer centre of Sree Mookambika Institute of Medical Sciences, Kanyakumari.

**Methods:** This was a prospective hospital-based study. 218 patients with malignancies involving various organs, attending the Cancer Centre of Sree Mookambika Institute of Medical Sciences, Kanyakumari, were recorded for a period of 6 months from October 2020 to February 2021. Approval from the Institutional research ethical committee was obtained.

**Results:** In our study, the most common non-specific cutaneous manifestation was generalized pruritis, observed in 17.88% of the patients, followed by acquired ichthyosis in 12.38% of the patients, and herpes zoster in 11.46% of the patients. Specific cutaneous manifestations included cutaneous metastatic infiltrates, observed in 5.04% of the patients.

**Conclusions:** Skin metastases may herald the recurrence of a malignancy after treatment and usually indicate a poor prognosis.

**Keywords:** Malignancy, Cutaneous, Metastasis, Breast

## INTRODUCTION

Internal malignancies involve various skin changes, among which some are related to the malignancy, such as malignant cutaneous infiltrates, some are treatment-related, mainly due to the toxic effect of the drugs taken, and some are non-specific.<sup>1</sup> Various internal malignancies give rise to cutaneous changes due to their immunological, metabolic, and metastatic consequences. The single most basic biologic process that characterizes a malignant tumor is the ability to produce secondary deposits (metastases) in distant sites. Generalized pruritus is one of the common cutaneous manifestations of a cutaneous metastasis.<sup>2</sup> The skin is an infrequent site for metastasis and was listed by

one study as low as the eighteenth of the most common sites.<sup>3</sup> Cutaneous metastases may appear at any age. Considering, however, the increased incidence of malignant disease later in life, most cutaneous metastases occur during or after the fifth decade of life.<sup>4</sup>

Cutaneous metastases are relatively uncommon but it is important to consider them. In some cases, they may precede a malignancy. Contiguous metastases are the most common in carcinoma of the breast and oral cavity and often herald the recurrence of a malignancy after surgery.<sup>1</sup> The trunk and the scalp are favored sites for distant metastases. The mortality rate is usually high with cutaneous metastases, although early recognition gives

some chance of survival, especially in patients that present themselves with cutaneous metastases.<sup>5</sup> Cutaneous metastasis from an internal malignancy is relatively uncommon, with the incidence rate ranging from 0.7% to 10.4% as reported in various case series.<sup>6</sup> These metastatic deposits indicate a higher stage of malignant disease and, as in any other metastatic tumor deposits in a patient under treatment, signify a lack of response of the malignancy to treatment. The common sites of skin metastasis from a lung cancer are the head, neck, chest, and abdomen.<sup>7</sup> As skin metastases may be suspected and detected earlier compared to metastases in other organs, the clinician should be cognizant of the various visual aspects of such lesions, and the pathologist should be aware of the various patterns of metastatic deposits in the skin. A biopsy evaluation of these deposits often yields clues as to the probable site of the primary tumor, based on the histological appearance of the deposits.

### Aim

The study was aimed at determining the frequency of cutaneous manifestations in patients with internal malignancy attending a tertiary care centre in Kanyakumari district.

### METHODS

A prospective hospital-based study was undertaken in oncology department of a medical college and lasted for a period of 6 months from October 2020 through February 2021. Approval from the institutional research ethical committee was obtained.

#### Study population

Patients of all age groups and both sexes with malignancy were eligible for the study.

#### Inclusion criteria

Cases confirmed to be malignant with skin manifestations; the course of malignancy and the course of skin disease should run a parallel course; the relation between the skin disease and the malignancy should be uniform.

#### Exclusion criteria

Cases confirmed with malignancy, without skin changes, cases with any other disease altering or causing the cutaneous dermatosis.

#### Study methodology

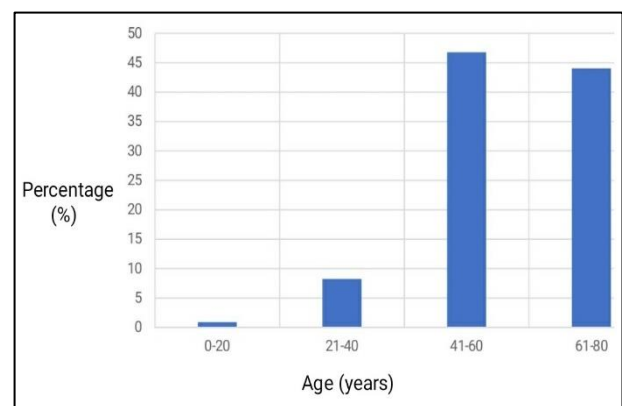
Detailed clinical and cutaneous examinations were performed for all patients. Relevant investigations were performed as the need arose. Specific investigations such as skin biopsies were performed for patients with specific features, such as cutaneous infiltrates. The relevant clinical

data, including the duration and type of the malignancy and the cutaneous features, were recorded.

Age, gender, type of carcinoma and cutaneous manifestations were considered as the outcome variables. Descriptive analysis was carried out by frequency and proportion for categorical variables. P value <0.05 was considered statistically significant. IBM SPSS version 22 was used for statistical analysis.

### RESULTS

The data was collected and the results were analyzed. As for the age distribution of the patients, the highest number of patients was between 40–60 years old (46.78%), followed by 44.03% of the patients between 61–80 years old and 8.25% of the patients between 21–40 years old.



**Figure 1: Age distribution among patients.**

**Table 1: Age distribution among the patients.**

Age distribution (years)	No. of patients	Percentage
0-20	2	0.91
21-40	18	8.25
41-60	102	46.78
61-80	96	44.03
<b>Total</b>	<b>218</b>	<b>100</b>

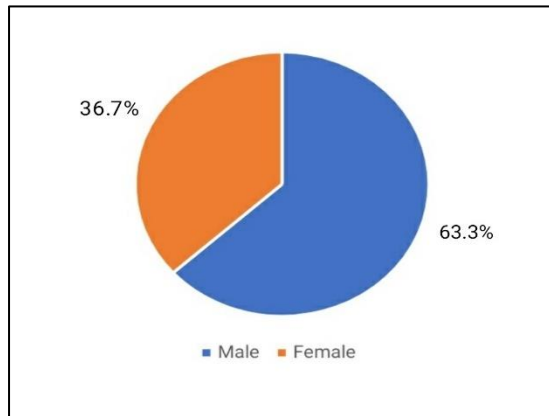
**Table 2: Gender wise distribution.**

Sex	No. of patients	Percentage (%)
<b>Male</b>	<b>138</b>	<b>63.3</b>
<b>Female</b>	<b>80</b>	<b>36.7</b>

There were only 0.91% of patients below the age of 20 years. The study comprised 138 males and 80 females and the male-to-female ratio was 1.7 to 1.

In our study, the most common non-specific cutaneous manifestation was generalized pruritis, observed in 17.88% of the patients, followed by acquired ichthyosis in 12.38% of the patients, and herpes zoster (Figure 1) in 11.46% of the patients. Specific cutaneous manifestations

included cutaneous metastatic infiltrates, observed in 5.04% of the patients.



**Figure 2: Gender wise distribution.**

**Table 4: Types of malignancies among the patients.**

Types of malignancy	No. of patients	Percentage
Breast carcinoma	51	23.38
Carcinoma cervix	20	9.17
Leukemia	20	9.17
Lymphoma	19	8.71
Lung carcinoma	12	5.50
Carcinoma prostate	10	4.58
Carcinoma ovary	9	4.12
Carcinoma oesophagus	9	4.12
Carcinoma larynx	8	3.66
Carcinoma endometrium	7	3.21
Carcinoma tongue	7	3.21
Brain tumours	7	3.21
Carcinoma with unknown primary	6	2.75
Carcinoma bladder	5	2.29
Carcinoma penis	5	2.29
Carcinoma colon	5	2.29
Carcinoma rectum	4	1.83
Carcinoma thyroid	3	1.37
Carcinoma stomach	3	1.37
Renal cell carcinoma	3	1.37
Hepatocellular carcinoma	2	0.91
Carcinoma pancreas	2	0.91
Carcinoma nasopharynx	1	0.45
<b>Total</b>	<b>218</b>	<b>100</b>

## DISCUSSION

The age distribution (Table 1) in our study saw most number of patients belonging the age group 41-60. This was slightly different from the studies by Puri et al in which most patients (32.3%) were in the age group 60-69

years and by Hassan et al. in which most (24.4%) were in the age group 55-64.<sup>8</sup>

Our study comprised 138 males (63.3%) and 80 females (36.7%) and the male: female ratio was 1.7: 1. This was similar to the findings in studies by Ayyamperumal et al and Hassan et al, where the male to female ratio was 1.8:1 and 1.3:1 respectively.<sup>1,9</sup>

In our study, the most common malignancy (Table 3) was carcinoma of the breast, which was observed in 23.38% of the patients, followed by carcinoma of the cervix and leukemia, each in 9.17%, lymphomas, in 8.71%, carcinoma of lung in 5.50%, prostate in 4.58%, ovary and esophagus in 4.12% each, larynx in 3.66%, carcinoma tongue, endometrium, brain tumors in 3.21% each, carcinoma with unknown primary in 2.75%, carcinoma of bladder, penis, colon in 2.29% each, rectum in 1.83%, carcinoma of the stomach, thyroid, and renal cell carcinoma in 1.37% each, carcinoma of the , in 2.29% of the patients, pancreas, hepatocellular carcinoma in 0.91% each, and nasopharyngeal carcinoma in 0.45% of the patients. This is in contrast to findings by Wani et al, Hassan et al and Rajagopal et al which determined carcinoma of esophagus (19%), colorectal carcinoma (20%) and lymphomas (8%), respectively as the leading causes of malignancies.<sup>9-11</sup>

In our study, the most common non specific cutaneous manifestations were generalized pruritis, observed in 17.88% of the patients, followed by acquired ichthyosis in 12.38%, herpes zoster (Figure 5) in 11.46%, pyoderms in 9.63%, dermatophytosis in 6.42%, seborrheic dermatitis in 5.96%, eczemas in 4.58%, candidal intertrigo and radiation dermatitis each in 4.12%, oral ulcers and nail pigmentation (Figure 6) in 2.75%, paronychia and erythroderma in 1.83% each, scabies, urticaria, contact dermatitis, cherry angiomas and papular urticaria in 1.37% each; photodermatitis in 0.91%, molluscum contagiosum and warts in 0.45% each. A study by Hassan et al also showed that generalized pruritus was the most common non-specific skin manifestation observed. In another study by Wani et al, xerosis and herpes zoster (2.4% each) were the most common non-specific cutaneous manifestations.<sup>9,10</sup>

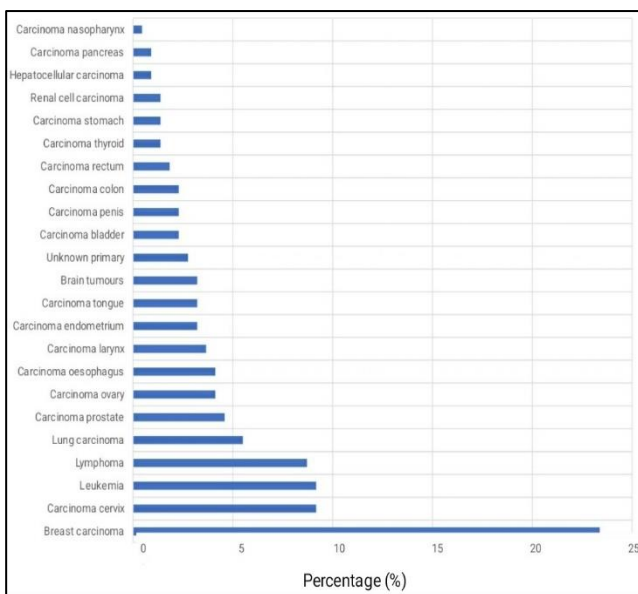
Specific skin manifestations included cutaneous metastatic infiltrates in 5.04% of the patients in our study. This was similar to the findings obtained in studies by Hassan et al and Kilaru et al, in which specific skin manifestations were cutaneous metastases observed in 6.3% and 6% of patients respectively.<sup>11,12</sup>

A cutaneous metastasis from an internal malignancy indicates a late stage of the disease. The skin is the eighteenth most common site for cutaneous infiltrates, which is rare. Some of the internal malignancies, such as carcinoma of the breast, have a tendency to produce cutaneous infiltrates. The incidence of a cutaneous

metastasis in our study was 5.04%. Cutaneous infiltrates are usually multiple.

**Table 4: Cutaneous manifestations among the patients.**

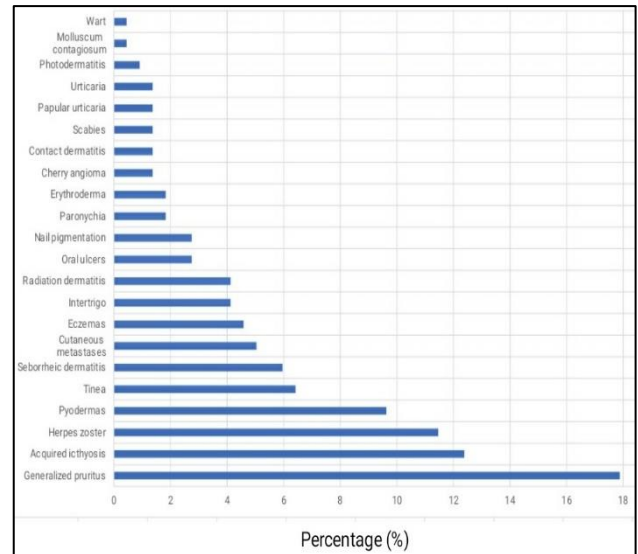
Cutaneous manifestations	No. of patients	Percentage
<b>Generalized pruritus</b>	39	17.88
<b>Acquired ichthyosis</b>	27	12.38
<b>Herpes zoster</b>	25	11.46
<b>Pyodermas</b>	21	9.63
<b>Tinea</b>	14	6.42
<b>Seborrheic dermatitis</b>	13	5.96
<b>Cutaneous metastases</b>	11	5.04
<b>Eczemas</b>	10	4.58
<b>Intertrigo</b>	9	4.12
<b>Radiation dermatitis</b>	9	4.12
<b>Oral ulcers</b>	6	2.75
<b>Nail pigmentation</b>	6	2.75
<b>Paronychia</b>	4	1.83
<b>Erythroderma</b>	4	1.83
<b>Cherry angioma</b>	3	1.37
<b>Contact dermatitis</b>	3	1.37
<b>Scabies</b>	3	1.37
<b>Papular urticaria</b>	3	1.37
<b>Urticaria</b>	3	1.37
<b>Photodermatitis</b>	2	0.91
<b>Molluscum contagiosum</b>	1	0.45
<b>Wart</b>	1	0.45



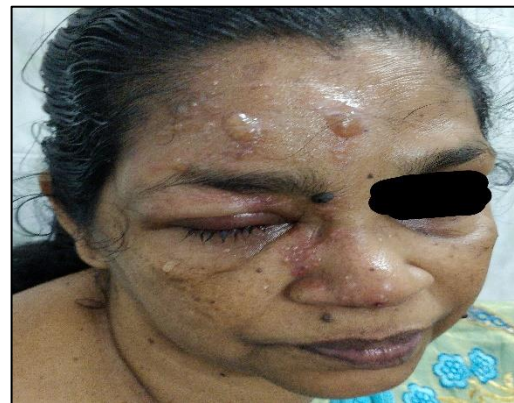**Figure 3: Types of malignancies among the patients.**

A cutaneous metastasis usually arises from carcinoma of the colon and lungs in males and from the colon, ovary, and breast in females. In our study, cutaneous infiltrates were the most common in the chest wall, followed by the abdomen, the face, and the extremities.

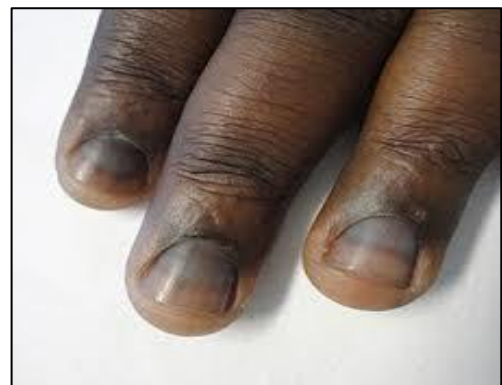The skin often mirrors changes in the internal milieu, and skin metastases may herald the recurrence of a malignancy after treatment.



**Figure 4: Cutaneous manifestations among the patients.**



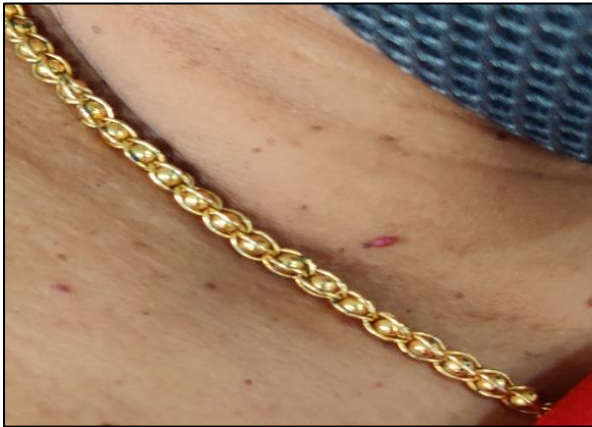**Figure 5: Herpes zoster in a 46-year-old female with carcinoma of the breast.**



**Figure 6: Nail pigmentation in a 48-year-old male secondary to vincristine.**



A cutaneous metastasis may appear at any age, but most cutaneous metastases occur during or after the age of 55 years. The interval between the onset of the symptoms of the primary malignancy and the onset of the cutaneous metastasis ranged from three months to two years. The shortest interval was three months in carcinoma of the lungs and the longest was two years in carcinoma of the breast.



**Figure 7: Cherry angiomas in a 46-year-old female with carcinoma of the ovary.**

The common malignancies that give rise to cutaneous metastases are carcinoma of the lung and colon in males and carcinoma of the colon and ovary in females. In our study, the chest was the most common site for a cutaneous metastasis, followed by the abdomen. Metastasis to the skin gives a poor chance of survival and a hopeless outcome.

## CONCLUSION

Cutaneous metastases indicating signs of recurrence as well as widespread metastases give poor prognosis and reduce the length of the survival period. It is important to recognize a cutaneous metastasis in time as it may precede an internal visceral metastasis, especially because early recognition helps in prolonging the survival of the patient. The morphological features of the primary tumor are often reflected in the cutaneous metastatic deposits, and attempts to suggest a possible primary site during a skin biopsy evaluation help the clinician in narrowing down the primary tumor possibilities and in initiating specific radio-imaging and other relevant investigations for the patient's management as early as possible.

*Funding: No funding sources*

*Conflict of interest: None declared*

*Ethical approval: The study was approved by the institutional ethics committee*

## REFERENCES

1. Ayyamperumal A, Tharini GK, Ravindran V, Parveen B. Cutaneous manifestations of internal malignancy. *Indian J Dermatol.* 2012;57:260-4.
2. Fett N, Haynes K, Probert KJ, Margolis DJ. 5-year malignancy incidence in chronic pruritus patients: A population-based cohort study aimed at limiting unnecessary screening practices. *J Am Acad Dermatol.* 2014;70:651-8.
3. Wright TS. Cutaneous manifestations of malignancy. *Curr Opin Pediatr.* 2011;23:407-11.
4. Badwe RA, Dikshit R, Laversanne M, Bray F. Cancer incidence trends in India. *Jpn J Clin Oncol.* 2014;44:401-7.
5. Wong CY, Helm MA, Kalb RE, Helm TN, Zeitouni NC. The presentation, pathology, and current management strategies of cutaneous metastasis. *N Am J Med Sci.* 2013;5:499-504.
6. Sittart JA, Senise M. Cutaneous metastasis from internal carcinomas: A review of 45 years. *An Bras Dermatol.* 2013;88:541-4.
7. Owen CE. Cutaneous manifestations of lung cancer. *Semin Oncol.* 2016;43:366-9.
8. Puri S, Ashat M, Pandey A, Goel NK, Singh A, Kaushal V. Socio-demographic characteristics of cancer patients: Hospital based cancer registry in a tertiary care hospital of India. *Indian J Cancer.* 2014;51:1-4.
9. Hassan I, Zeerak S, Kuchay S, Bashir S, Bhat YJ, Mubashir S, et al. Cutaneous changes in internal malignancy: Study from a tertiary care center. *Indian J Dermatol Venereol Leprol.* 2017;83:276.
10. Wani MA, Jan FA, Khan NA, Pandita KK, Khurshid R, Khan SH. Cancer trends in Kashmir; common types, site incidence and demographic profiles: National Cancer Registry 2000-2012. *Indian J Cancer.* 2014;51:133-7.
11. Rajagopal R, Arora P N, Ramasastry C V, Kar P K. Skin changes in internal malignancy. *Indian J Dermatol Venereol Leprol.* 2004;70:221-5.
12. Kilaru KR, Kaja K, Garimella VR. Cutaneous manifestations of underlying malignancies presenting to a tertiary care teaching hospital. *Int J Res Dermatol.* 2019;5:57-62.

**Cite this article as:** Simon N, Varghese MG, Pravin AJS, Padmaprasad MK, Rajagopal S, Vijayabharathi M et al. A study on the cutaneous manifestations of patients with internal malignancy attending a cancer center in Kanyakumari District *Int J Res Dermatol.* 2021;7:697-701.