

Case Report

An immunologic intrigue: psoriasis vulgaris developing on pemphigus foliaceus

Deepali C. Tarate*, Rachita Misri, Vinod K. Khuranna

Department of Dermatology, Hindu Rao Hospital and North Delhi Medical College, Delhi, India

Received: 09 May 2021

Accepted: 02 June 2021

***Correspondence:**

Dr. Deepali C. Tarate,

E-mail: drdeepalitarate9@gmail.com

Copyright: © the author(s), publisher and licensee Medip Academy. This is an open-access article distributed under the terms of the Creative Commons Attribution Non-Commercial License, which permits unrestricted non-commercial use, distribution, and reproduction in any medium, provided the original work is properly cited.

ABSTRACT

Pemphigus foliaceus is an autoimmune blistering disease characterized by superficial flaccid blisters, erosions, scales and crusts on the seborrheic areas of the face and trunk. Mucosal involvement is seldom seen. The first report by Bloom in 1929, stated the coexistence of pemphigus foliaceus and psoriasis vulgaris. Since then, very few cases of psoriasis coexistent with autoimmune bullous diseases have been reported in which psoriasis had preceded or simultaneously presented with pemphigus foliaceus. We reported a rare case where psoriasis vulgaris developed in case of pemphigus foliaceus after 20 years.

Keywords: Pemphigus foliaceus, Co-existent psoriasis vulgaris, Psoriatic arthritis, Rituximab

INTRODUCTION

Pemphigus foliaceus is an autoimmune blistering disease characterized by superficial flaccid blisters, erosions, scales and crusts in the seborrheic distribution. Mucosal involvement is seldom seen. Histopathologically, acantholysis of granular layer with acantholytic cells and intra epidermal deposition of immunoglobulin-G against desmoglein1 and complement component3 (C3) is seen.

The first report by Bloom in 1929 stated the coexistence of pemphigus foliaceus and psoriasis vulgaris.¹ Since then, very few cases of psoriasis coexistent with autoimmune bullous diseases have been reported in which psoriasis had preceded or simultaneously presented with pemphigus foliaceus. We reported a rare case where psoriasis vulgaris developed in case of pemphigus foliaceus after 20 years.

CASE REPORT

A 61 year old male patient presented with few itchy red raised scaly lesions over trunk and extremities since one year. The lesions over the extremities were reddish, dry, extremely itchy and topped with adherent whitish scales. Also few crusted lesions were present since few weeks over the chest and back. The patient was a known case of pemphigus foliaceus (biopsy proven) since 20 years and self-medicated intermittently with oral corticosteroids since past 2 years. On enquiry, no change was noticed by patient in the morphology of these lesions over the years. There was associated pain in small joints of hands and feet since last few months. The pain was intermittent in nature, of moderate intensity involving the distal interphalangeal joints and not associated with any morning stiffness. The patient had also developed chronic side effects of corticosteroids like cushingoid habitus, glaucoma, osteoporosis and hypertension.

Cutaneous examination showed multiple well defined superficial erosions topped with semi adherent hyperpigmented crusts over the back and chest (Figure 1). Nikolsky's sign (marginal and distant) was negative. The lesions over the lower extremities were few well defined erythematous plaques of various sizes with whitish adherent scaling, seen bilaterally symmetrically over knees and shins (Figure 2). Skin biopsy was taken from a plaque on the left lower extremity and crusted lesion over the back.

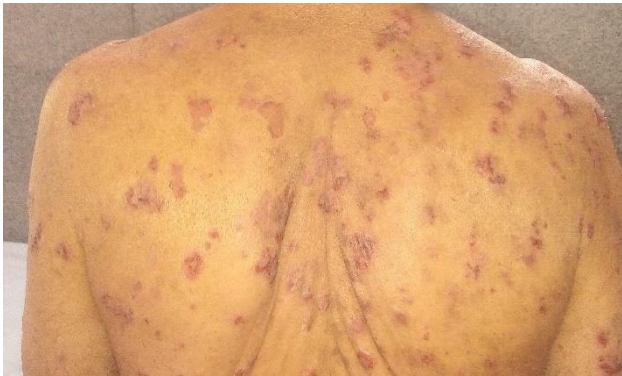

Figure 1: Pemphigus foliaceus-well defined superficial erosions topped with semi adherent hyperpigmented crusts over the back and chest.

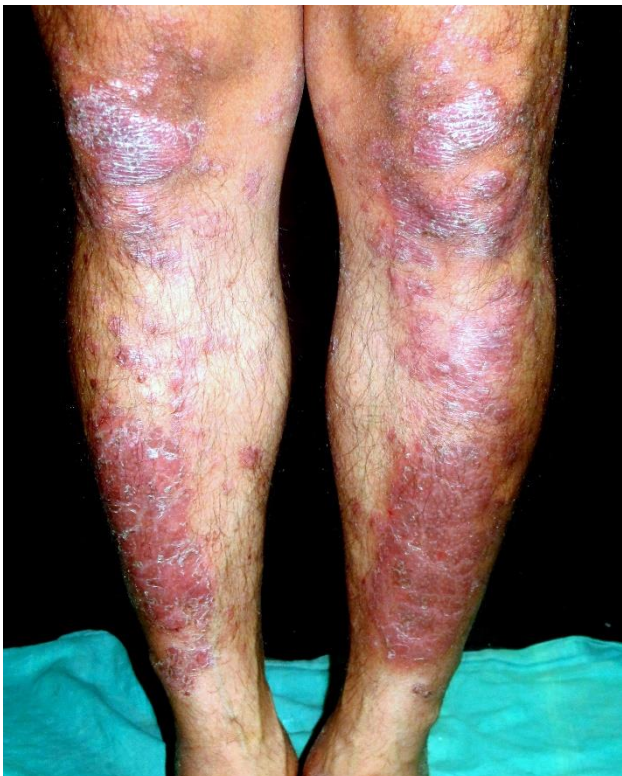

Figure 2: Psoriasis vulgaris-well defined erythematous plaques of various sizes with whitish adherent scaling seen bilaterally symmetrically over knees and shins.

Histopathology of leg lesion showed features of parakeratosis, hypogranulosis, Munro's micro abscesses,

spongiform pustules of Kojog, elongation of rete ridges along with mild lymphocytic dermal infiltrate, consistent with psoriasis vulgaris (Figure 3). The back lesion on histopathology showed granular layer acantholysis with presence of acantholytic cells in the cavity and eosinophilic spongiosis. Direct immunofluorescence done for the back lesion showed fish net pattern with deposition of IgG over the epidermis (Figure 4). Thus we reached a diagnosis of pemphigus foliaceus with coexistent psoriasis vulgaris and psoriatic arthritis.

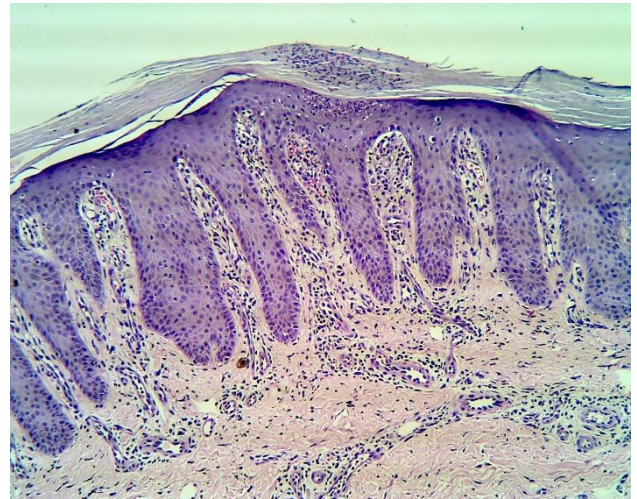


Figure 3: Haematoxylin and eosin stain (40×)-parakeratosis, hypogranulosis, Munro's micro abscesses, spongiform pustules of Kojog, elongation of rete ridges along with mild lymphocytic dermal infiltrate.

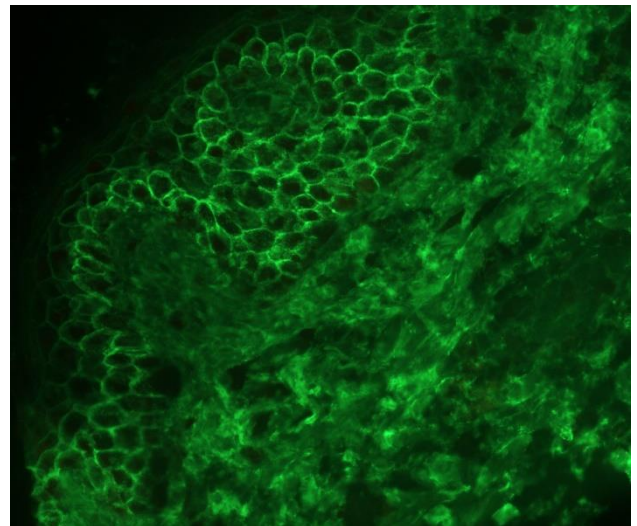


Figure 4: Direct immunofluorescence-shows fish net pattern with intercellular deposition of IgG in superficial layers of epidermis.

All the baseline investigations (haemogram, liver function tests, renal function tests), screening for tuberculosis and hepatitis markers were normal. Radiographs of the chest, hands and feet were within

normal limits. The dual energy X-ray absorptiometry (DEXA) scan showed osteopenia. Ophthalmological investigations were within normal limits. As patient had developed severe side effects of corticosteroids, we considered starting the patient on rituximab as per the rheumatoid arthritis protocol. Since the investigations were within normal limits, the patient was pre medicated and given first infusion of rituximab 1 gm over 6-8 hours with adequate monitoring. After 15 days the second infusion was administered. Topical steroids and emollients along with antihistamines were continued. And tablet methotrexate 15 mg/week and tablet leflunomide 20 mg daily was started for psoriatic arthritis. The skin lesions started healing by 2 weeks and over 3 months completely healed. There were no active lesions since last few months and patient was maintained on tablet methotrexate (10 mg/week), tablet leflunomide (20 mg) and emollients.

DISCUSSION

Psoriasis has been reported to be associated with systemic lupus erythematosus, bullous pemphigoid, myasthenia gravis and ulcerative colitis, suggestive of a predisposition to autoimmune disease.² Amongst the blistering diseases, bullous pemphigoid was followed by pemphigus vulgaris was seen co-existing with psoriasis vulgaris.^{3,4} Literature search showed only eight cases of coexistence of these pemphigus foliaceus and psoriasis vulgaris (Table 1).^{5,6} Also one of the cases showed concurrent development of pemphigus foliaceus and psoriasis vulgaris and one showed pemphigus preceding psoriasis.^{6,7} Our case is rare as psoriasis vulgaris presented 20 years after the onset of pemphigus foliaceus incidentally.

Table 1: Cases of patients with pemphigus foliaceus coexisting with psoriasis in english literature.^{5,6}

S. no.	Age (in years)/gender	Time gap between psoriasis and pemphigus foliaceus	Ongoing treatment of psoriasis when pemphigus foliaceus developed	Pemphigus foliaceus treatment taken	Author
1	34/F	Concurrent development	None	Azathioprine; prednisolone	Lee et al
2	45/M	Not available	PUVA* ¹	Prednisolone	Aghassi and Dover
3	72/M	52 years	None	Prednisolone	Tomasini et al
4	38/M	Not available	None	Methotrexate	Perez et al
5	51/M	8 months	None	Prednisolone	Yokoo et al
6	77/F	7 years	None	Prednisolone	Giomi et al
7	40/F	10 years	None	Injection methotrexate (i.m.)	Lee and Ro
8	66/F	2 months	PF preceded psoriasis* ³	Methylprednisolone pulse	Abbas et al

PUVA-psoralen ultraviolet A; i.m.=intramuscularly; *³=single other case where pemphigus foliaceus was preceded by psoriasis (pustular type here).

The exact pathogenesis is still not clear. The likely postulates are presence of HLA-DR4 haplotype in both diseases, dual role of IL-8 (IgG autoantibodies inducing production of IL-8 in keratinocytes and role of IL-8 in forming neutrophilic pustules).^{8,9} Phototherapy may also trigger production of endogenous pemphigus autoantibodies and significant decreased suppressor T cell activity in psoriasis pemphigus foliaceus has been treated successfully with oral corticosteroids and immunosuppressants along with topical medications. Patients resulting in increased production of autoantibodies against skin antigens.¹⁰ Corticosteroids used for treatment of vesiculobullous diseases could be a trigger for pustular psoriasis.⁴

The treatment protocol for these co existent diseases is not known, a combination of immunosuppressant (azathioprine, methotrexate) for psoriasis and corticosteroids for pemphigus and have been used in few cases (Table 1).^{5,6} In literature, few reports of rituximab

showed good response (eighty percentage achieving complete remission) for pemphigus vulgaris and pemphigus foliaceus as per the rheumatoid arthritis protocol. The effect of rituximab on psoriasis has been intriguing. It has also been reported to be effective in recalcitrant cases of psoriasis vulgaris and psoriatic arthritis and paradoxically precipitated the disease.¹¹⁻¹⁴

CONCLUSION

We reported a rare case in which pemphigus foliaceus was co-existent with psoriasis vulgaris and psoriatic arthritis in which the latter developed after two decades.

ACKNOWLEDGEMENTS

We would like to thank Dr. Meenakshi Batrani for histopathology and direct immunofluorescence reporting and images at Dr. Kubba, dermatopathology centre, New Delhi.

Funding: No funding sources

Conflict of interest: None declared

Ethical approval: Not required

REFERENCES

1. Bloom D. Psoriasis with superimposed bullous eruption. *Med J Rec.* 1929;130:246.
2. Hsu LN, Armstrong AW. Psoriasis and autoimmune disorders: a review of the literature. *J Am Academy Dermatol.* 2012;67(5):1076-9.
3. Rao R, Gupta A, Yunis F, Handettu S, Chandrashekar B. Coexistence of psoriasis with bullous pemphigoid. *Indian Dermatol Online J.* 2012;3(2):119-2.
4. Ohata C, Ishii N, Koga H, Fukuda S, Tateishi C, Tsuruta D, et al. Coexistence of autoimmune bullous diseases (AIBDs) and psoriasis: A series of 145 cases. *J Am Acad Dermatol.* 2015;73(1):50-5.
5. Kwon HH, Kwon IH, Chung JH, Youn JI. Pemphigus foliaceus associated with psoriasis during the course of narrow-band uvb therapy: a simple coincidence? *Ann Dermatol.* 2011;23:281-4.
6. Abbas D, Rana R, Alireza M, Sareh S, Behnam R. A case of pemphigus foliaceus and pustular psoriasis with a brief review of literature. *Our Dermatol Online.* 2017;8(4):406-9.
7. Lee CW, Ro YS, Kim JH. Concurrent development of pemphigus foliaceus and psoriasis. *Int J Dermatol.* 1985;24(5):316-7.
8. Perez GL, Agger WA, Abellera RM, Dahlberg P. Pemphigus foliaceus coexisting with IgA nephropathy in a patient with psoriasis vulgaris. *Int J Dermatol.* 1995;34(11):794-6.
9. Kato K, Hanafusa T, Igawa K, Tatsumi M, Takahashi Y, Yamanaka T, et al. A rare case of annular pustular psoriasis associated with pemphigus foliaceus. *Ann Dermatol.* 2014;26(2):260-1.
10. Aghassi D, Dover JS. Pemphigus foliaceus induced by psoralen UV-A. *Arch Dermatol.* 1998;134(10):1300-1.
11. Heelan K, Al-Mohammed F, Smith MJ, Knowles S, Lansang P, Walsh S, et al. Durable remission of pemphigus with a fixed-dose rituximab protocol. *JAMA Dermatol.* 2014;150(7):703-8.
12. Chang YS, Lee H, Chen W, Hsiao K, Chen M, Tsai C, et al. Treatment of psoriasis with rituximab. *J Am Acad Dermatol.* 2012;66(5):184-5.
13. Cohen JD. Successful treatment of psoriatic arthritis with rituximab. *Ann Rheumatic Dis.* 2008;67(11):1647-8.
14. Dass S, Vital EM, Emery P. Development of psoriasis after B cell depletion with rituximab. *Arthritis Rheum.* 2007;56(8):2715-8.

Cite this article as: Tarate DC, Misri R, Khuranna VK. An immunologic intrigue: psoriasis vulgaris developing on pemphigus foliaceus. *Int J Res Dermatol* 2021;7:609-12.