

## Original Research Article

# Mask associated dermatosis: unmasking the challenges- a cross sectional study

Ketki, Sonali Gupta, Vijay Paliwal, Rachita Mathur, Deepak K. Mathur\*

Dermatology, Venereology and Leprosy, SMS Medical College, Jaipur, Rajasthan, India

**Received:** 04 May 2021

**Accepted:** 31 May 2021

**\*Correspondence:**

Dr. Deepak K Mathur,

E-mail: [drdkmathur@yahoo.co.in](mailto:drdkmathur@yahoo.co.in)

**Copyright:** © the author(s), publisher and licensee Medip Academy. This is an open-access article distributed under the terms of the Creative Commons Attribution Non-Commercial License, which permits unrestricted non-commercial use, distribution, and reproduction in any medium, provided the original work is properly cited.

### ABSTRACT

**Background:** The novel coronavirus, referred to as SARS-COV 2 causing COVID 19, has become a great health challenge to the mankind. After its origin from Wuhan, China, it spread all over the globe within a short period of time. World Health Organization (WHO) officially declared COVID 19 as pandemic on 11th March, 2020. Aerosoles or droplets are the commonest mode of infection through respiratory tract making it mandatory to wear masks as a preventive measure.

**Methods:** It is a cross-sectional study conducted over patients attending the out patients department of Dermatology. They were observed for presence of dermatosis over the face and categorized according to nature of dermatoses.

**Results:** We observed 385 patients, 200 (52%) patients had new dermatoses and 185 (48%) patients noticed flare of existing dermatoses. The predominant new dermatoses were dermatophytosis, indentations, sweat induced dermatitis, urticaria, pressure urticaria developing with indentations, contact dermatitis to metal and other materials in 49 (24.5%), 42 (21%), 42 (21%), 38 (19%), 19 (9.5%) and 10 (5%) cases respectively. The flared dermatoses were acne, rosacea, plane warts and molluscum contagiosum in 120 (64.8%), 24 (12.9%), 22 (11.9%) and 17 (9.2%) cases respectively. Koebnerisation of vitiligo and lichen planus was also seen in few subjects.

**Conclusions:** The prolonged use of face mask may cause various infective and non infective facial dermatoses. In the current scenario, it is mandatory to wear face mask as a preventive measure hence it is important to wear the mask properly. However, care of the mask as well as breaks from the mask are important factors to avoid the development of mask associated dermatosis.

**Keywords:** COVID-19, Facial dermatosis, Mask associated dermatosis

### INTRODUCTION

In December 2019, an outbreak of unexplained cases of pneumonia was reported from Wuhan, China which was thought to have originated from the seafood market of Wuhan. Soon the cases began to rise rapidly indicating the possibility of human to human transmission. It was then identified to be caused by a novel strain of coronavirus, now named severe acute respiratory syndrome CoV-2 (SARS-CoV-2) and the disease was named COVID-19, that spreads primarily through droplets, respiratory

secretions and direct contact with infected surface.<sup>1</sup> The disease was announced a Public Health Emergency of International Concern on January 30, 2020 and on 11th March, 2020 Covid-19 was declared a pandemic.<sup>2</sup> In view of rising cases all over the world, WHO urged all countries to take preventive measures to prevent the transmission of infection. Various measures like wearing face mask, social distancing, frequent washing of hands or use of sanitizers, restriction of gathering and travelling were imposed to “break the chain” in spread of the infection.

With extreme social distancing being unsustainable and complete lockdown being devastating for the economy, universal use of face mask has been advocated that is a well known and established strategy to control transmission of respiratory infections.<sup>3</sup> The use of face masks has become the “new normal”. Due to the global shortage of surgical masks and N95 respirators, the US Centers for Disease Control and Prevention (CDC) have recommended the use of cloth mask or a cloth face cover for general public.<sup>4</sup>

The prolonged use of facial mask may result in several skin problems, most notably, irritant contact dermatitis (ICD), contact urticaria and allergic contact dermatitis (ACD), acne or flare up of existing dermatoses like acne, pigmentation, rosacea, dermatophytoses, seborrheic dermatitis etc.<sup>5</sup> The present study was undertaken to study the occurrence and pattern of various facial dermatosis attributable to prolonged use of face masks as preventive measure to COVID 19.

**METHODS**

This observational study was conducted in the Dermatology Out patient department (OPD) in a tertiary care hospital of North India. All the patients aged more than 18 years attending the OPD from September 2020 to December 2020 were enrolled for the study after obtaining proper consent. All the patients were observed for any facial dermatosis either primary or aggravated after use of face mask. The demographic and clinical details like duration of symptoms, type of face mask and average duration of mask use, morphology and site of lesions, occupation of the patients were noted on a predesigned proforma. Statistical analysis was done by assessing the categorical data in the form of absolute numbers and percentages using the software Statistical package for social sciences (SPSS).

**RESULTS**

*Age and sex distribution*

Total of 385 patients were studied, majority of the patients were in age group between 20-59 years accounted for 60% (231) cases followed by 22% (85) cases in <20 years age group and 18% (69) cases comprised the elderly age group of >60 years. Males outnumbered the females, 64% (246) cases were males while 36% (139) cases were females.

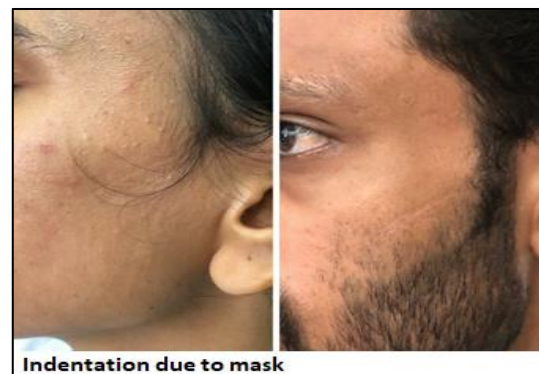*Clinical details*

We observed 385 patients, of which 200 (52%) patients had new dermatoses and 185 (48%) patients noticed flare of existing dermatoses. The predominant new dermatoses were dermatophytosis, indentations, sweat induced dermatitis, urticaria, pressure urticaria developing with indentations, contact dermatitis to metal and other materials in 49 (24.5%), 42 (21%), 42 (21%), 38 (19%), 19 (9.5%), 10 (5%) and cases respectively. The flared

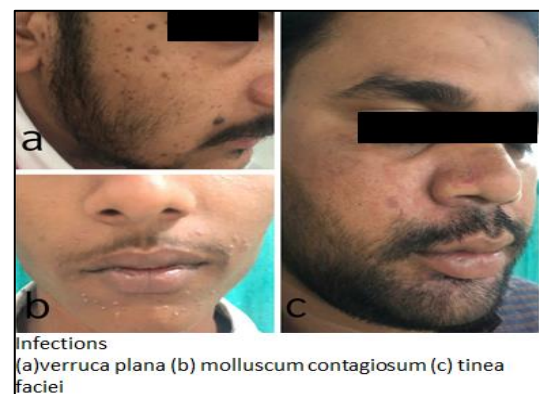
dermatoses were acne, rosacea, plane warts and molluscum contagiosum in 120 (64.8%), 24 (12.9%), 22 (11.9%) and 17 (9.2%) cases respectively. Koebnerisation of Vitiligo and Lichen planus was observed in 2(1.08%) subjects. (Table 1) (Figure 1) (Figure 2) (Figure 3) (Figure 4)

**Table 1: Clinical details of the patients.**

New Dermatoses	No of cases	Aggravation of Dermatoses	No of cases
<b>Dermatophytosis</b>	49	Acne flare up	120
<b>Indentations</b>	42	Plane warts	22
<b>Urticaria</b>	38	Molluscum contagiosum	17
<b>Urticaria with indentations</b>	10	Rosacea	24
<b>Contact dermatitis</b>	19	Koebnerisation of LP	1
<b>Sweat Dermatitis</b>	42	Koebnerisation of vitiligo	1
<b>Total</b>	200	<b>Total</b>	185



**Figure 1: Indentation due to mask.**

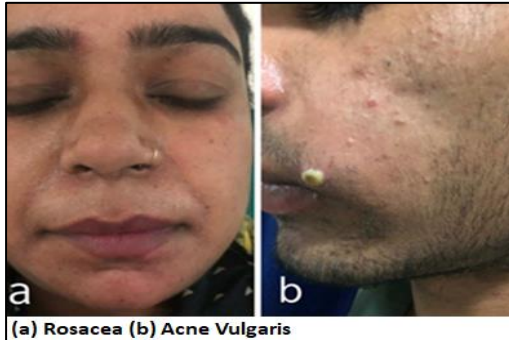

**Figure 2: Infections; (a) verruca plana, (b) molluscum contagiosum and (c) tinea faciei.**

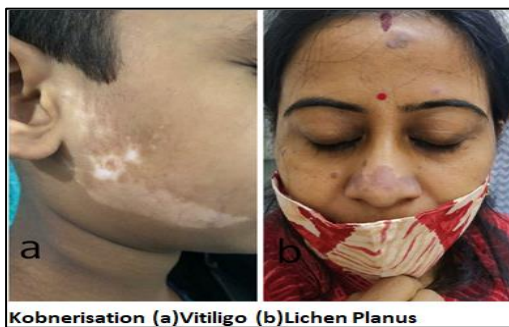The predominantly affected sites were cheeks seen in 73% (281) cases followed by nasal bridge, auricular region, chin and jaw line in 16% (61), 7% (26), 3% (11) and 1.5% (6) cases respectively.

**Type of the mask**

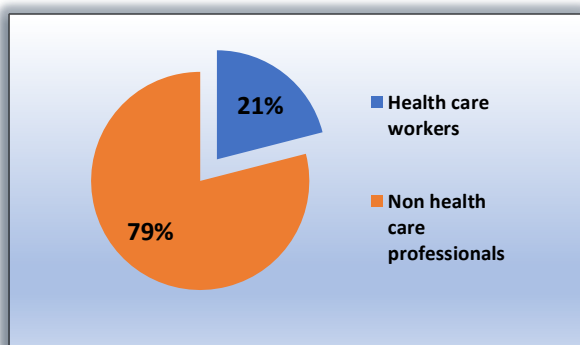
Majority of the participants (65% / 250) were using simple cloth masks. The N95 and surgical mask were used by 28% (107) and 7.2% (28) subjects respectively. Majority of participants were non health care professionals (79%), a small group of subjects were health care professionals comprising only 21% cases. (Figure 5)



**Figure 3: (a) Rosacea and (b) acne vulgaris.**



**Figure 4: Koberisation; (a) Vitiligo and (b) lichen planus.**



**Figure 5: Occupation of patients.**

**DISCUSSION**

The global pandemic caused by COVID-19 has not only heightened the need to use face masks as a safety measure but has also highlighted the problems associated with such preventive gears. The personal protective equipment such

as face mask and hand gloves have led to an increase in the incidence of cutaneous problems related to their use.

The adverse skin reactions caused by prolonged wearing of masks include acne flare up, urticaria, allergic contact dermatitis, irritant contact dermatitis and skin dryness, pressure effect on the nose and friction erosions.<sup>6</sup>

During the previous Severe acute respiratory syndrome (SARS) epidemic, several facial dermatosis were reported due to the wearing of polypropylene N95 (FFP2) respirators. According to a report from Singapore during the SARS outbreak in 2003, 35.5% Health care workers reported facial dermatoses including acne (59.6%), facial itch (51.4%), and rash (35.8%) from N95 mask use.<sup>6</sup>

In a recent survey among frontline workers, the prevalence rate of skin damage related to enhanced prevention measures during the COVID 19 pandemic was documented as 97% includes dryness, tightness, and desquamation were reported as common symptoms and the nasal bridge was the most affected site.<sup>7</sup>

Allergic contact dermatitis due to adhesives or other parts of the respirator masks such as rubber straps and metal clips has also been reported.<sup>6</sup> Adhesives that are used in surgical masks to affix the blue/white strip of textile enfoldng the nasal clip contain a preservative dibromodicyanobutane, which has been identified as an allergen and can cause contact dermatitis.<sup>8</sup>

A former study has pointed out that more than one-third of health care workers had complains of acne, facial itching, and even dermatitis from wearing N95 mask. Several factors including humidity, warm environment and occlusion due to local pressures have been proposed to explain the exacerbation of these conditions.<sup>9</sup>

Two studies done via questionnaire in China have shown that the prevalence of skin damage related to enhanced preventive measures to frontline health care workers during the COVID 19 crisis was 74-97%. Lin et al reported that hands were the most common site affected. This was followed by the cheeks, nasal bridge and auricular areas.<sup>10</sup> Lan et al, reported the nasal bridge as most commonly affected site, the other sites were the hands, cheeks, and forehead. They observed dryness and tightness as commonest symptoms, other symptoms were pruritus and burning/pain which increased with increased duration of time.<sup>7,10</sup>

The acne breakouts due to mask use has led to the coining of the term “Maskne” which has been considered as a variant of acne mechanica. A clinical criteria has been proposed for maskne which includes onset of acne within 6 weeks of start of regular face mask use or exacerbation of acne over the masked area, a distinct pattern, which the authors have referred to as the O-zone, and exclusion of differential diagnoses, including perioral dermatitis,

seborrheic dermatitis, pityrosporum folliculitis, and acne rosacea.<sup>11</sup>

Long term use of occlusive masks cause hyperhydrated state of epidermis which results in maceration of skin, erosions and may further aggravate contact dermatitis. Donning of these masks over prolonged periods of time creates a humid microclimate which favors the flare-up of acne. Another possible mechanism of the flare up can be a consequence of simple pilosebaceous duct occlusion due to local pressure on the skin from the close-fitting masks. The humid environment created due to wearing of masks for long hours can not only cause acne breakout but also make a favorable environment for the growth of fungus on the skin. Reusing or sharing the same masks, improper hygiene, wearing masks that fit too tightly may further aggravate the spread of fungal and viral infections of the skin. Increased cases of dermatophytosis, verruca vulgaris, molluscum contagiosum can be thus seen due to fomite spread of these pathogens.

We also observed koebnerisation of various dermatosis like vitiligo and lichen planus on the face probably linked to friction and trauma secondary to face mask use. The koebnerisation was actively managed and patients were asked to wear soft cloth masks.

These dermatoses can cause severe distress in the patients which can further lead to avoidance of face mask use. Therefore, it is of supreme importance that people should be counseled about the preventive measures against development of these conditions. In a consensus of Chinese experts on protective measures against barrier dysfunction on prolonged use of masks, following measures were described:

#### ***Protective measures for pressure injury***

##### *The choice of masks*

A properly fitted mask that is not too tight should be worn that can prevent against indentations and erosions. Alternatively, masks can be used in different ways to avoid sustained pressure and friction on the same site.

##### *Application of moisturizers or gel*

Application of moisturizers before wearing masks has been advocated that helps to lubricate the skin and reduce friction thus restores the barrier function.

##### *Management of skin indentation*

Most of the mild skin indentations resolve spontaneously. In cases of distressing redness or swelling, hydrophatic compresses can be done which involves three to four layers of gauze soaked by cold water or normal saline and applied for about 20 minutes every 2 to 3 hours followed by application of moisturizers. Over heated water, ethanol and other irritants should not be applied directly to the face.

##### *Management of severe erosions*

Severely blistered skin can lead to secondary infections, to prevent these erosions hydrophatic compresses with povidone iodine diluted by normal saline at a ratio of 1:9 can be used on face. It is encouraged to apply medical dressing after hydrophatic compress. Alternatively, topical antibiotic ointments such as compound polymyxin B, mupirocin, or fusidic acid on infected skin has also been recommended.

##### *Management of skin dryness and scales*

Closed and humid environments caused by water in exhaled air may cause skin barrier dysfunction and lead to subsequent skin dryness and scales. Applying high-potent moisturizers before and after wearing masks is paramount to prevent such discomfort.

##### *Management of other dermatoses aggravated by masks or goggles*

The management of acne vulgaris includes:

Moisturizers containing oil control ingredients should be used before and after using of masks. In case of mild papules and pustules, benzoyl peroxide or topical antibiotic can be used with topical retinoids for comedones at night time. Severe acne vulgaris should be treated as per the guidelines of acne management.

##### *Other facial skin disorders*

Sweat induced facial dermatitis, seborrheic dermatitis, and rosacea can be aggravated by wearing masks and goggles. Preventive measures includes:

Control time of wearing preventive equipment. Use gauze inside masks. Apply moisturizers before donning and after doffing masks. Adhere to previous treatments under the guidance of dermatologist. Consult dermatologists if sustained aggravation exists.<sup>12</sup>

American Academy of Dermatology also issued guidelines to prevent acne breakouts with prolonged mask use. They recommend cleansing and moisturizing the face daily, protection of lips by applying petroleum jelly, avoiding the makeup when wearing a mask and trying new skin care products that can irritate your skin along with refraining from certain skin care products if the face becomes irritated. They also advise to wear the right mask, wash cloth masks regularly and take a 15-minute mask break every 4 hours.

## **CONCLUSION**

In conclusion the role of masks in prevention of respiratory infection is well established but the ongoing pandemic has also highlighted certain disadvantages of using it, making it a double edged sword. However, avoiding the use of mask should never be encouraged in such times and utmost

importance should be given in prevention of development and treatment of dermatosis associated with use of face mask. The people prone to these dermatoses should be counseled regarding proper use of mask, care of the facial skin according to ambience like use prior application of moisturisers, avoidance of alcohol based cleansers over the face, care of the mask like washing, reuse, avoid too tight mask, and avoidance of makeup & other cosmetics before wearing the mask. Treatment of mask associated dermatoses should be tailored according to the individuals need.

*Funding: No funding sources*

*Conflict of interest: None declared*

*Ethical approval: The study was approved by the institutional ethics committee*

## REFERENCES

1. World Health Organization. Novel Coronavirus (2019-nCoV) Situation Report - 1. Geneva: WHO; 2020. Accessed on 3<sup>rd</sup> March 2021.
2. Timeline: WHO's COVID-19 response. Available at <https://www.who.int/news-room/detail/27-04-2020-who-timeline---covid-19>. Accessed on 3<sup>rd</sup> March 2021.
3. Esposito S, Principi N, Leung CC, Migliori GB. Universal use of face masks for success against COVID-19: evidence and implications for prevention policies. *Eur Respir J*. 2020;55(6):2001260.
4. Centers for Disease Control and Prevention. Coronavirus Disease 2019 (COVID-19). How to Protect Yourself & Others. Available at <https://www.cdc.gov/coronavirus/2019-cov/prevent-getting-sick/prevention.html>. Accessed on 3<sup>rd</sup> March 2021.
5. Balato A, Ayala F, Bruze M. European Task Force on Contact Dermatitis statement on coronavirus 19 disease (COVID-19) outbreak and the risk of adverse cutaneous reactions. *J Eur Acad Dermatol Venereol*. 2020.
6. Foo CC, Goon AT, Leow YH, Goh CL. Adverse skin reactions to personal protective equipment against severe acute respiratory syndrome--a descriptive study in Singapore. *Contact Dermatitis*. 2006;55(5):291-4.
7. Lan J, Song Z, Miao X. Skin damage among health care workers managing coronavirus disease-2019. *J Am Acad Dermatol*. 2020;82(5):1215-6.
8. Al Badri FM. Surgical mask contact dermatitis and epidemiology of contact dermatitis in healthcare workers. *Curr Allergy Clin Immunol*. 2017;30(3):183-8.
9. Elston DM. Occupational skin disease among health care workers during the coronavirus (COVID-19) epidemic. *J Am Acad Dermatol*. 2020;82(5):1085-6.
10. Lin P, Zhu S, Huang Y, Li L, Tao J, Lei T et al. Adverse skin reactions among healthcare workers during the coronavirus disease 2019 outbreak: a survey in Wuhan and its surrounding regions. *Br J Dermatol*. 2020;183(1):190-2.
11. Teo WL. Diagnostic and management considerations for "maskne" in the era of COVID-19. *J Am Acad Dermatol*. 2021;84(2):520-1.
12. Yan Y, Chen H, Chen L. Consensus of Chinese experts on protection of skin and mucous membrane barrier for health-care workers fighting against coronavirus disease 2019. *Dermatologic Therapy*. 2020;e13310.

**Cite this article as:** Ketki, Gupta S, Paliwal V, Mathur R, Mathur DK. Mask associated dermatosis: unmasking the challenges- a cross sectional study. *Int J Res Dermatol* 2021;7:547-51.