

## Case Report

# Paint brush hair: a case report

Rajesh Munusamy\*, Aishwarya Lakshmi Sekar

Department of Dermatology, Venereology and Leprosy, Mahatma Gandhi Medical College and Research Institute, Sri Balaji Vidyapeeth University, Puducherry, India

**Received:** 03 May 2021

**Accepted:** 31 May 2021

**\*Correspondence:**

Dr. Rajesh Munusamy,

E-mail: [gillmarajesh@gmail.com](mailto:gillmarajesh@gmail.com)

**Copyright:** © the author(s), publisher and licensee Medip Academy. This is an open-access article distributed under the terms of the Creative Commons Attribution Non-Commercial License, which permits unrestricted non-commercial use, distribution, and reproduction in any medium, provided the original work is properly cited.

### ABSTRACT

Trichorrhexis nodosa (TN) is a hair shaft disorder presenting with whitish nodes all over the hair (diffuse form) or localized to an area (localized form) and could be either congenital or acquired. TN is ultimately a response to physical or chemical trauma that leads to formation of nodes along the hair shaft. Here, we reported a case of TN of the beard, diagnosed clinically and through trichoscopy. Patient was advised to shave his beard hair and to avoid brushing completely. On follow-up, the patient was symptomatically better. Based on this, TN of the beard was confirmed.

**Keywords:** Hair shaft, Trichorrhexis nodosa, Trichoscopy

### INTRODUCTION

TN is a hair shaft disorder presenting with whitish nodes over the hair and could be either congenital or acquired. The acquired form is due to physical or chemical trauma which is more common than the congenital form.<sup>1</sup>

Here, we reported a case of acquired TN of the beard caused due to repeated trivial trauma.

### CASE REPORT

A 26 year old male presented to the dermatology outpatient department with history of multiple whitish spots over the beard hair since 3 months, with increased fragility at these spots (Figure 1). The patient admitted frequent brushing of his beard hair with a pocket comb. There was no history of bleaching, using hair cosmetics, or hair straightening. No similar lesions were seen on scalp hair or other hairy sites. No history of similar complaints in the family. Light microscopy and trichoscopy using videodermoscopy was done in beard hair which showed tiny nodules as thrust paint brushes as

if two brushes were thrust into each other (Figure 2 and 3). Patient was advised to shave his beard hair and to avoid brushing completely. On follow-up, the patient was symptomatically better. Based on this, TN of the beard was diagnosed.

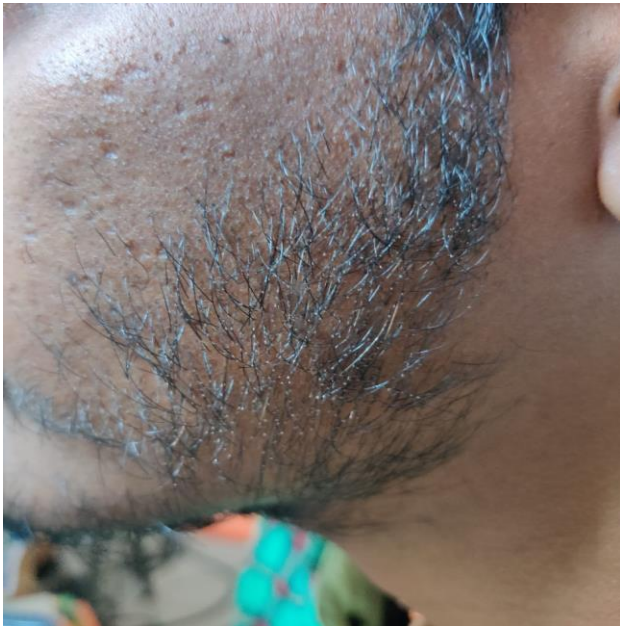### DISCUSSION

Acquired TN is a common hair shaft disorder associated with hair fragility due to cuticle repair as a response to thermal injury, mechanical or chemical trauma.<sup>2</sup> The exposed cortical fibers separate and fray, causing a nodular swelling of the hair shaft at intervals. Individual cortical fibers start to fracture, producing the appearance of two paint brushes thrust into one another.<sup>3</sup>


The condition is classified into an acquired form and a primary congenital form, which is usually associated with multi-system syndromes.<sup>1,4</sup>

Acquired form results from excessive or repeated trauma caused by frequent brushing, scalp massage and repeated ultraviolet exposure and chemical trauma includes

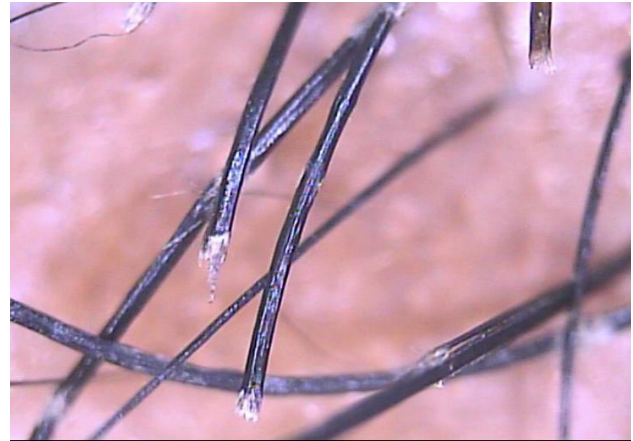
excessive salt water bathing, shampooing, setting and dyeing of hair.<sup>3,5</sup> It could also be due to malnutrition or endocrinopathy, especially iron deficiency and hypothyroidism.<sup>6</sup> TN can also affect brittle hairs with underlying structural weakness apart from normal hairs like pili torti, monilethrix, pseudomonilethrix and trichorrhexis invaginata which are more susceptible to trauma.<sup>3</sup> Characteristic presentation includes white flecking, dry and lustreless hair with abnormal fragility and inability to attain normal hair length because of premature breakage of the hair fiber.<sup>1,4</sup>



**Figure 1: Multiple whitish nodes seen over the beard hair.**



**Figure 2: Light microscopy of hair showing thrust paint brushes appearance (hair mount, ×40).**



**Figure 3: Trichoscopy using videodermoscopy shows broken hair shafts with frayed ends appearing as a paint brush).**

Trichoscopy is one of the recent advances in diagnostic dermatology. It allows examination of subtle clinical patterns of skin lesions and subsurface skin structures not normally visible to the unaided eye.<sup>7</sup> At low magnification, nodular thickenings along the hair shaft, which appear light in the darker hair shaft.<sup>7</sup> At higher magnification, trichoscopy shows numerous small fibers, which produce a picture resembling two brooms or brushes aligned in opposition.<sup>4</sup>

Congenital TN is a rare condition that becomes apparent at birth or infancy.<sup>8</sup> TN can be associated with argininosuccinic aciduria, Menkes' kinky hair syndrome, Netherton's syndrome, hypothyroidism or trichothiodystrophy.<sup>9</sup> Common concurrent symptoms are mental retardation, motor defects, growth failure and seizures. Other associated symptoms may include nail and skin changes (ichthyosis), photosensitivity, ocular dystrophy and infertility.<sup>1</sup>

Acquired TN falls into three basic categories: proximal, distal and localized.<sup>1</sup>

#### **Acquired localised**

It generally is accompanied by a pruritic dermatosis such as seborrhoeic dermatitis, pediculosis capitis, contact dermatitis or lichen simplex, predominantly over scalp, beard or moustache, leading to repeated scratching. The hair is faded, lighter and lusterless. The condition eventually resolves spontaneously.<sup>3</sup>

#### **Acquired proximal**

It is common in blacks who use caustic chemicals while styling hair, causing breakage in the proximal hair shaft, leading to alopecia in areas subject to friction from brushing or sleeping.<sup>3</sup>

### **Acquired distal**

It is common in white or Asian individuals, where the nodes appear on the distal ends of hair shaft, which looks lustreless and shows splitting.

Trichoscopically, trichorrhexis invaginata and hair casts can be considered as possible differential diagnosis.<sup>9</sup> Clinically, differentials include dandruff, pediculosis and others shaft abnormalities like pilli annulate.<sup>1</sup>

Treatment options in acquired TN are aimed at avoiding the incriminated offending agent. The use of oils and conditioners can be advised to reduce the hair shaft cuticular damage by reducing the hair comb friction.<sup>10</sup>

### **CONCLUSION**

TN is most commonly an acquired condition and recurrent mechanical trauma is a major contributing factor for hair shaft fragility. This case highlights the localised form of TN confined to the beard and the use of trichoscopy and light microscopy as diagnostic modalities in aiding the clinical diagnosis.

*Funding: No funding sources*

*Conflict of interest: None declared*

*Ethical approval: Not required*

### **REFERENCES**

1. Gari SA. A case of acquired trichorrhexis nodosa after applying new hair spray. J Saudi Soc Dermatol Dermatol Surg. 2013;17(2):73-5.

2. Camacho-Martínez F. Localized trichorrhexis nodosa. J Am Acad Dermatol. 1989;20(4):696-7.

3. Whiting DA. Structural abnormalities of the hair shaft. J Am Acad Dermatol. 1987;16(1):1-25.

4. Rudnicka L, Olszewska M, Waśkiel A, Rakowska A. Trichoscopy in hair shaft disorders. Dermatol Clin. 2018;36(4):421-30.

5. Miyamoto M, Tsuboi R, Oh-I T. Case of acquired trichorrhexis nodosa: scanning electron microscopic observation. J Dermatol. 2009;36(2):109-10.

6. Medscape. Fact sheet: Trichorrhexis Nodosa, 2020. Available at: <https://emedicine.medscape.com/article/1073664-overview>. Accessed on 11 March 2021.

7. Kharkar V, Gutte R, Thakkar V, Khopkar U. Trichorrhexis nodosa with nail dystrophy: diagnosis by dermoscopy. Int J Trichology. 2011;3(2):105-6.

8. Rogers M. Hair shaft abnormalities: part I. Australas J Dermatol. 1995;36(4):179-84.

9. Shah S, Ankad BS. Trichoscopy of an isolated trichorrhexis nodosa: a case report. Ind Dermatol Online J. 2017;8(5):386.

10. Martin AM, Sugathan P. Localised acquired trichorrhexis nodosa of the scalp hair induced by a specific comb and combing habit: a report of three cases. Int J Trichology. 2011;3(1):34.

**Cite this article as:** Munusamy R, Sekar AL. Paint brush hair: a case report. Int J Res Dermatol 2021;7:590-2.