

Case Report

Linear lupus panniculitis of scalp: a case report from north-east India

Nandakishore Thokchom, Erika Salam*, Nandita Bhattacharjee, Linda Kongbam

Department of Dermatology and VL, Regional Institute of Medical Sciences, Imphal, Manipur, India

Received: 15 February 2021

Revised: 19 March 2021

Accepted: 23 March 2021

*Correspondence:

Dr. Erika Salam,

E-mail: erikasalam01@gmail.com

Copyright: © the author(s), publisher and licensee Medip Academy. This is an open-access article distributed under the terms of the Creative Commons Attribution Non-Commercial License, which permits unrestricted non-commercial use, distribution, and reproduction in any medium, provided the original work is properly cited.

ABSTRACT

Lupus panniculitis of scalp is an uncommon manifestation of lupus erythematosus, which presents as non-scarring linear, arched, or annular alopecia along the lines of Blaschko. A 7 year old child presented with localised linear non-scarring alopecia on scalp. Examination revealed a single linear alopecic patch on the left parietal scalp. There were no associated systemic complaints. Skin biopsy showed atrophic lining epithelium, diffuse and nodular lymphocytic and plasma cells infiltrates in the superficial and deep dermis, lobular inflammatory infiltration of lymphocytes, histiocytes and plasma cells, with minimal involvement of septa in the subcutaneous tissue. Antinuclear Antibody (ANA) and anti-ds DNA tests were negative. Patient responded well with regrowth of terminal hair within 3 weeks to a combination treatment of hydroxychloroquine, topical and intralesional steroids, and topical calcineurin inhibitor. Linear lupus panniculitis of scalp should be considered in cases of patterned, non-scarring alopecia. Regular follow-up is also essential due to the possibility of recurrence and development of systemic lupus erythematosus.

Keywords: Lupus, Panniculitis, Linear, Alopecia, Scalp

INTRODUCTION

Lupus panniculitis (LP) is a rare form of chronic cutaneous lupus erythematosus involving deep dermis and subcutaneous fat. Scalp is involved in 16.7% cases which may present as indurated erythematous plaque leading to scarring alopecia in classic lupus panniculitis, or as non-scarring alopecia. Linear lupus panniculitis of scalp (LLPS) is a unique type of lupus panniculitis resulting in non-scarring alopecia along the Blaschko's line.¹

CASE REPORT

A 7 years old child presented to the dermatology OPD with a 4 months history of an itchy localized, non-scarring hair loss on scalp in a linear pattern. It initially started as an erythematous swelling over the vertex of

scalp, which then, progressed to involve the left fronto-parietal area of scalp in a linear pattern, followed by loss of hair after 1 month. There was no history of trauma or atopy and no family history of similar complaints or autoimmune disease.

Cutaneous examination revealed a single, mildly erythematous, tender, non-scarring alopecic patch, studded with few erythematous papules, in a linear pattern measuring approximately 1x8 cm² extending from the vertex to the left fronto-parietal area of scalp (Figure 1). Hair pull test was negative. There was no involvement of other hair bearing areas, nails and mucosa. Lymphadenopathy was absent and systemic examination findings were normal.

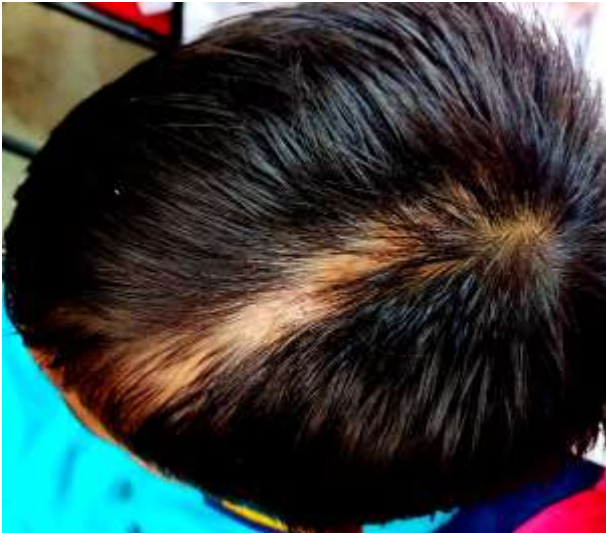

Figure 1: Before treatment.

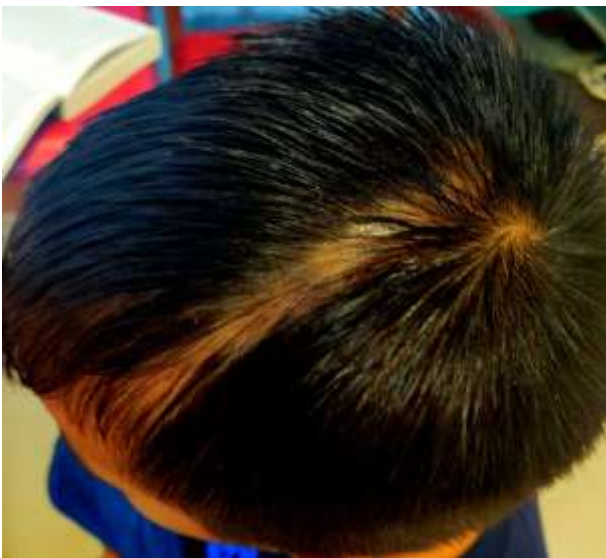

Figure 2: Hair regrowth after 1 month of treatment.

Skin biopsy from scalp revealed atrophic epidermis, diffuse and nodular lymphocytic and plasma cells infiltrates in the superficial and deep dermis. The subcutaneous tissue shows lobular inflammation with infiltrates composed of lymphocytes, histiocytes and plasma cells, with minimal septal involvement (Figure 3). ANA and anti-ds DNA were also negative. All routine blood investigations were normal.

LLPS was diagnosed based on the clinical and histopathological findings. He was started on oral hydroxychloroquine 100 mg daily, 0.05% clobetasol propionate cream and tacrolimus 1% ointment along with intralesional triamcinolone injections given 3 weekly for a total of 4 doses. Good clinical response was observed at regular follow-ups (Figure 2). Complete regrowth of hair was seen after 5 months (Figure 4), following which the medications were tapered and stopped.

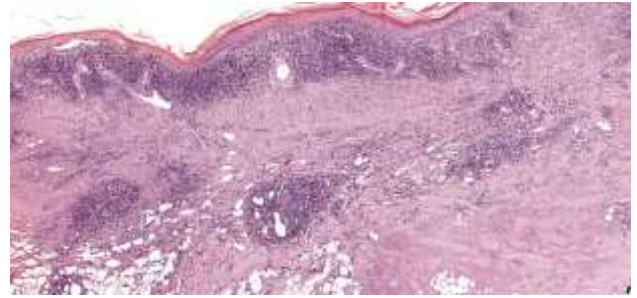


Figure 3: HPE from scalp, 10X skin biopsy showing atrophic epidermis, diffuse and nodular lymphocytic and plasma cells infiltrates in the superficial and deep dermis with lobular inflammation composed of lymphocytes, histiocytes and plasma cells, with minimal septal involvement in the subcutaneous tissue.



Figure 4: Complete hair regrowth seen after 5 months.

DISCUSSION

Cutaneous lupus panniculitis preferentially affect the face and scalp areas. The resulting lesions may resemble alopecia areata or non-scarring linear alopecia.² Though linear morphology is the most common, it can also present as arch-shaped, annular and ulcer pattern.³ Nagai et al reported the first case of LLPS.⁴

Majority of LLPS cases have been reported from East-Asia, with non-scarring alopecia along Blaschko's lines, being the major presentation without other body involvement. Male predominance and non-scarring alopecia were reported in LLPS in contrast to classical LP, in which female predominance and scarring alopecia are common. A younger age of onset have also been described which was also evident in our case.⁵

Clinically, LLPS is characterized by a reversible course, with fewer associations with SLE.⁵ Our case presented with erythema, tenderness of scalp which is similar to the findings in other studies but lacked atrophy and follicular plugging which were reported by others.⁵ Luengarun et al reported parietal area of scalp to be the most common site of involvement, which was also observed in our case.⁶

Histologically, LLPS is characterised by lobular panniculitis with lymphoplasmacytic infiltration. ANA positivity was noted in only 17% cases, which is in contrast to lupus panniculitis, which show an ANA positivity rate of 70%.⁵ Our case showed similar histologic findings with negative ANA and anti-ds DNA.

Alopecia areata, trichotillomania, and traction alopecia can all clinically resemble and manifest as linear alopecia.⁵ A thorough history, clinical examination, and histopathology are essential to confirm LLPS.

Treatment of our patient consisted of hydroxychloroquine, topical steroid, topical calcineurin inhibitor, and intralesional steroid, similar to treatment regimens used in other published cases, with the aim of decreasing disease associated inflammation to promote hair regrowth.^{1,5} Significant clinical improvement was noted, with complete re-growth of hair after 5 months.

CONCLUSION

Alopecia is not an uncommon complaint, but alopecia in a linear distribution is a rare presentation. LLPS should be considered as a differential diagnosis in a case of linear non-scarring alopecia presenting with additional features such as erythema and scalp tenderness. Early diagnosis and long-term follow-up are required to avoid risk of scarring, recurrence and to monitor disease progress.

Funding: No funding sources

Conflict of interest: None declared

Ethical approval: Not required

REFERENCES

1. Udompanich S, Chanprapaph K, Suchonwanit P. Linear and annular lupus panniculitis of the scalp: case report with emphasis on trichoscopic findings and review of the literature. *Case Rep Dermatol.* 2019;11(2):157-65.
2. Kiritsi D, Diaz-Cascajo C, Hoffmann R, Happle R, Jakob T, Kern JS. A band-like balding disorder. *The Lancet.* 2014;383(9917):e14.
3. Lueangarun S, Subpayasarn U, Chakavittumrong P, Tempark T, Suthiwartnarueput W. Lupus panniculitis of the scalp presenting with linear alopecia along the lines of Blaschko. *Clinic Experi Dermatol.* 2017;42(6):705-7.
4. Nagai Y, Ishikawa O, Hattori T, Ogawa T. Linear lupus erythematosus profundus on the scalp following the lines of Blaschko. *Eur J Dermatol.* 2003;13(3):294-6.
5. Chen YA, Hsu CK, Lee JY, Yang CC. Linear lupus panniculitis of the scalp presenting as alopecia along Blaschko's lines: A distinct variant of lupus panniculitis in East Asians? *J Dermatol.* 2012;39(4):385-8.
6. Lueangarun S, Subpayasarn U, Tempark T. Distinctive lupus panniculitis of scalp with linear alopecia along Blaschko's lines: a review of the literature. *Internat J Dermatol.* 2019;58(2):144-50.

Cite this article as: Thokchom N, Salam E, Bhattacharjee N, Kongbam L. Linear lupus panniculitis of scalp: a case report from north-east India. *Int J Res Dermatol* 2021;7:473-5.