

Case Report

The enigma of adult onset Henoch Schoenlein purpura and leucocytoclastic Vasculitis: a case report

Vasudha A. Belgaumkar, Ravindranath B. Chavan*,
Nitika S. Deshmukh, Ranjitha K. Gowda

Department of Skin and VD, B. J. Government Medical College, Pune, Maharashtra, India

Received: 13 February 2021

Accepted: 11 March 2021

***Correspondence:**

Dr. Ravindranath B. Chavan,

E-mail: drravindranathchavan@gmail.com

Copyright: © the author(s), publisher and licensee Medip Academy. This is an open-access article distributed under the terms of the Creative Commons Attribution Non-Commercial License, which permits unrestricted non-commercial use, distribution, and reproduction in any medium, provided the original work is properly cited.

ABSTRACT

Leukocytoclastic vasculitis (LCV), also known as hypersensitivity vasculitis is a small vessel inflammatory disease which mainly involves the postcapillary venules. It can be idiopathic or secondary to connective tissue diseases, infection, malignancy. A 39 year old male presented with a recurrent episode of multiple palpable purpurae over the legs, trunk, back and upper limbs with diffuse abdominal pain, bloody diarrhoea and arthralgia. Anti-nuclear antibodies (ANA) were positive, but ANA profile was equivocal. Histopathological examination confirmed leukocytoclastic vasculitis. A final diagnosis of Henoch Schoenlein purpura (HSP) was reached based on EULAR Criteria. He was treated with tapering doses of prednisolone, hydroxychloroquine and bed rest with limb elevation. All symptoms and lesions gradually resolved. Various sub-types of cutaneous small vessel vasculitis may mimic each other, warranting a meticulous evaluation. Adult onset HSP though rare must be considered in the differential diagnosis of LCV, which might be the presenting manifestation of an underlying connective tissue disease. Hence long-term follow-up with stringent clinical and laboratory monitoring is recommended.

Keywords: Leukocytoclastic vasculitis, Henoch Schoenlein purpura, Hypersensitivity vasculitis

INTRODUCTION

Vasculitis refers to inflammation of the blood vessels leading to tissue destruction with or without organ damage. It is classified as small, medium or large vessel vasculitis and may be either idiopathic or associated with an underlying disease. Cutaneous LCV is usually confined to small-vessel involvement of skin with rare extracutaneous manifestations in less than 30% of the cases.¹ The terms cutaneous LCV, cutaneous small-vessel vasculitis and cutaneous leukocytoclastic angiitis are all used interchangeably for this type of skin-predominant vasculitis. We report an adult male who presented with the key clinical features of cutaneous leukocytoclastic

angiitis and was diagnosed as Henoch Schoenlein purpura.

CASE REPORT

A 39 year old male presented with multiple itchy, reddish raised lesions over the trunk, limbs and back since one month. Lesions initially appeared over the legs, gradually progressing to involve the thighs, abdomen and upper limbs. He denied history of photosensitivity, fever, coryza, cough, constitutional or systemic symptoms and antecedent drug intake but reported occurrence of a similar episode one year ago which had resolved spontaneously. Examination showed multiple partially

blanchable purpuric papules distributed bilaterally over the lower and upper limbs, trunk, abdomen and back, palms and soles. Face was conspicuously spared. Deep dermal tenderness sign was positive. Edema with tenderness were present over hands and feet. Few coalescing haemorrhagic vesicles with central necrosis and crusting were seen on the left forearm (Figures 1-4). Mucosae were unremarkable. A week later, during his stay in the dermatology ward, he developed pain and swelling in both knee joints with abdominal cramps, bloody diarrhoea and burning micturition. Based on the history and clinical findings, we kept cutaneous small vessel vasculitis due to cutaneous LCV or adult-onset Henoch Schoenlein purpura as our differential diagnosis.

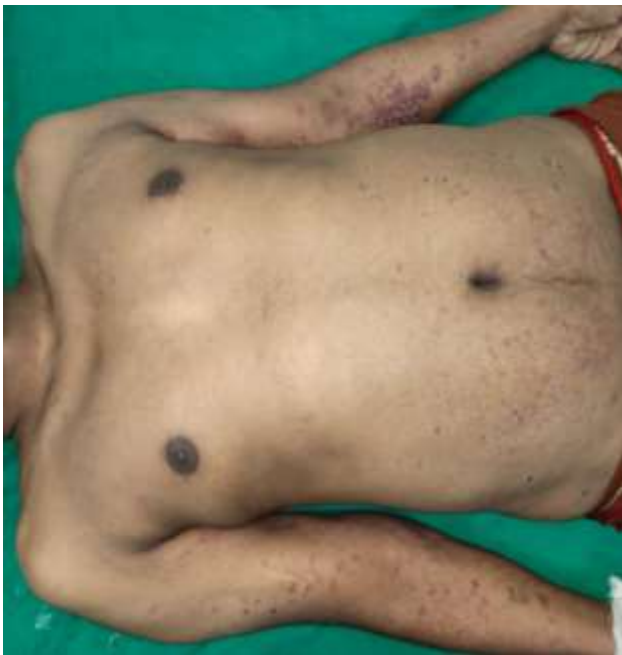

Figure 1: Multiple petechiae over the lower abdomen, arms with coalescing haemorrhagic vesicles with central necrosis and crusting.

Routine investigations like complete blood count, liver function tests and renal function tests were within normal limits. 24-hour urinary protein showed microalbuminuria. Stool examination showed occult blood.

His CRP was positive and ESR was elevated (47 mm/hr). RA (Rheumatoid factor), ASO (Anti Streptolysin O) titre and screening for Hepatitis B and C, HIV-ELISA and VDRL were also negative. Ultrasonography of abdomen and pelvis, Chest X-ray, Doppler of bilateral lower limbs, radiological examination of the knee joints were unremarkable. His ANA (ELISA) was positive while the ANA blot by enzyme Immuno-Assay was inconclusive.

Histopathology of the lesion showed unremarkable epidermis with moderate to focally dense perivascular collection of neutrophils, lymphocytes, macrophages and occasional eosinophilic inflammatory infiltrate with extravasation of RBCs and focal karyorrhexis which were

consistent with the findings of leukocytoclastic vasculitis (Figure 5). Immunofluorescence and serum IgA levels could not be performed because of the financial constraints. A final diagnosis of adult-onset Henoch Schoenlein purpura was made based on EULAR criteria (European alliance of associations for rheumatology) criteria.

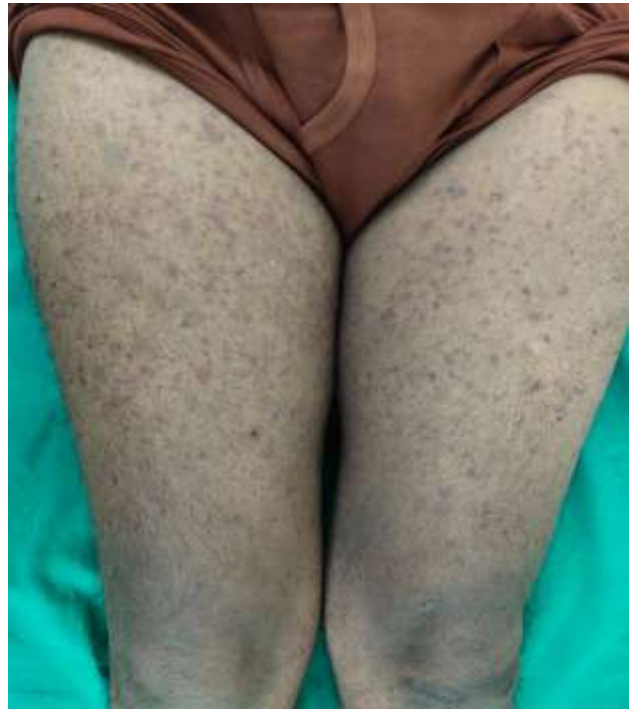

Figure 2: Petechiae over the anterior thighs.

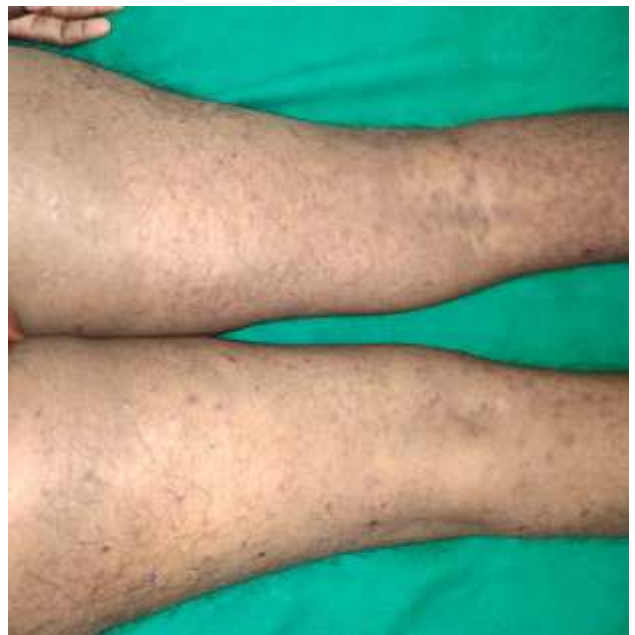

Figure 3: Petechiae over the posterior thighs.

He was started on intravenous antibiotics (ceftriaxone 1 gm IV 12 hourly, metronidazole 400 mg IV 8 hourly)

along with prednisolone (0.75 mg/kg/day for 5 days) which was gradually tapered to 0.5 mg/kg/day as the existing lesions flattened and started resolving, Tablet hydroxychloroquine 400 mg twice a day and vitamin C supplements (Figure 6). Supportive measures like limb elevation and rest were also given. Gradually his abdominal and joint complaints regressed with marked improvement in lesions. Currently he is under regular follow-up.

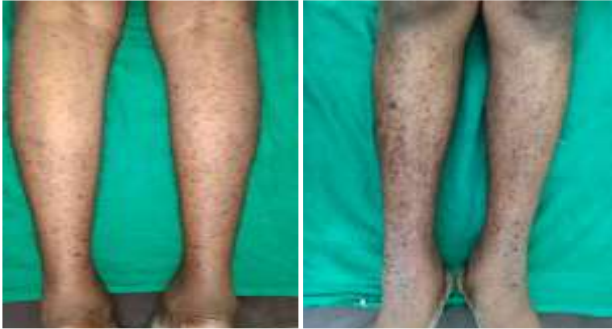

Figure 4: Petechiae over the legs.

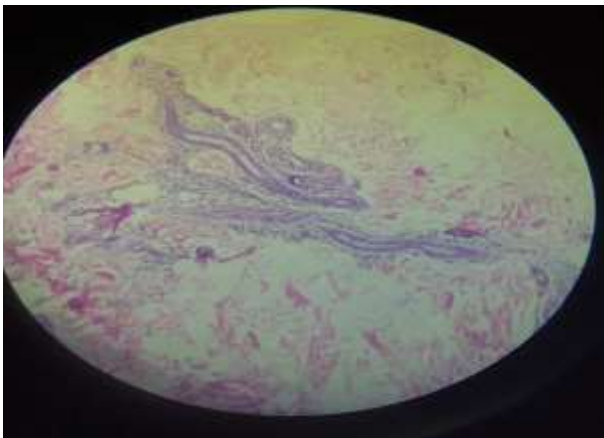


Figure 5: Hematoxylin and eosin stain 40x showing focally dense perivascular collection of neutrophils, lymphocytes, macrophages and occasional eosinophilic inflammatory infiltrate with exocytosis of RBCs and focal karyorrhexis.

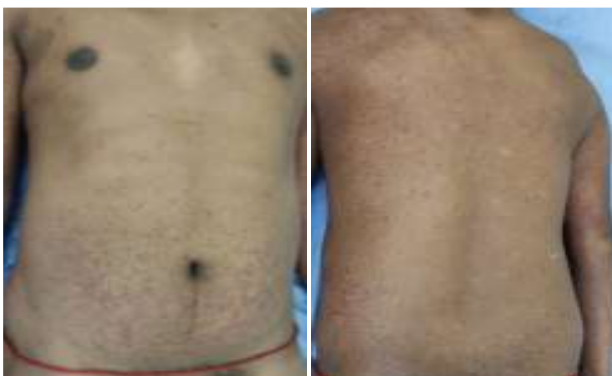

Figure 6: Resolution of lesions over the trunk and back.

DISCUSSION

Small vessel vasculitis can be classified as primary and secondary. Primary causes include Henoch Schoenlein purpura, essential mixed cryoglobulinemia and cutaneous leukocytoclastic vasculitis while secondary causes comprise drugs, infections (Table 1).²

LCV is a small vessel vasculitis characterized histopathologically by immune complex-mediated vasculitis of the dermal capillaries and venules. Cardinal clinical features of cutaneous leukocytoclastic angiitis include palpable purpura, lower extremity location, small vessel involvement.³⁻⁵ Only one-third of patients may present with trunk and upper extremity involvement as seen in our case.⁶

LCV is idiopathic in approximately 50% of the cases. Other causes include infection (15-20%), inflammatory disease (15-20%), drugs (10-15%), and malignancy (<5%).⁷ Infections and drugs are the most common triggers for secondary leukocytoclastic vasculitis.⁸ It can be seen in association with underlying systemic autoimmune diseases, chronic infections, and malignancies.

Post-infectious leukocytoclastic vasculitis is most often seen after streptococcal upper respiratory tract infection. Other infectious triggers include, but are not limited to, *Mycobacterium*, *Staphylococcus aureus*, *Chlamydia* and HIV. In our case, a definitive infective focus could not be identified. Although the patient experienced an episode of bloody diarrhoea with abdominal cramps, these symptoms could be attributed to a manifestation of the vasculitis itself rather than gastrointestinal infection.

Several drugs reported to be associated with leukocytoclastic vasculitis are beta-lactams, erythromycin, clindamycin, vancomycin, sulphonamides, furosemide, allopurinol, NSAIDs, amiodarone, gold, thiazides, phenytoin, beta-blockers, TNF-alpha inhibitors, selective serotonin reuptake inhibitors, metformin, warfarin, valproic acid, among many others. There was no contributory drug history in our case.

Neoplastic causes include, leukemias, visceral tumors such as intestinal adenocarcinoma and lung cancer, all of which were excluded.

Systemic diseases like systemic lupus erythematosus (SLE), Sjogren syndrome, inflammatory bowel disease, Behcet disease, and rheumatoid arthritis, cryoglobulinemic vasculitis, hypocomplementemic urticarial vasculitis, and erythema elevatum diutinum are also associated with leukocytoclastic vasculitis.⁹ As LCV is a well-documented non-specific cutaneous manifestation of SLE, we performed a thorough evaluation for any associated connective tissue diseases, but were unable to find any evidence other than a positive ANA, which might indicate the possibility of an unspecified

connective tissue disorder.¹⁰ However, our patient did not meet the requisite criteria for SLE or any other autoimmune disorder.

Table 1: Classification and causes of vasculitis.

Dominant vessel involved	Primary	Secondary
Large arteries	giant cell arteritis Takayasu's arteritis	aortitis associated with RA infection (e.g., syphilis)
Medium arteries	classical PAN Kawasaki disease	infection (e.g., hepatitis B)
Small vessels and medium arteries	Wegener's granulomatosis Churg-Strauss syndrome microscopic polyangiitis	vasculitis 2 to RA, SLE, Sjögren's syndrome drugs infection (e.g., HIV)
Small vessels (leukocytoclastic)	Henoch-Schönlein purpura essential mixed cryoglobulinaemia cutaneous leukocytoclastic vasculitis	drugs infection (e.g., Hepatitis B, C)

One of the differentials in this case was adult onset HSP, a disease that shares many clinicopathological features with LCV. According to the EULAR 2010 criteria, a patient is said to have HSP if he/she has palpable purpura, not thrombocytopenic/petechiae (mandatory criteria) with at least or more than one of the following; diffuse abdominal pain, histopathology is typical LCV with predominant IgA deposits or proliferative glomerulonephritis with predominant IgA deposits, arthritis or arthralgias, renal involvement (proteinuria >0.3 g/24 h or >30 mmol/mg of urine albumin to creatinine ratio on a spot morning sample; and/or hematuria, red blood cell casts >5 red cells per high power field or ≥2+ on dipstick or red blood cell casts in the urinary sediment).¹¹ Our patient had non-thrombocytopenic palpable purpura (a mandatory criteria) along with histopathological evidence of LCV, arthralgia, diffuse abdominal pain and microalbuminuria, thereby satisfying 3 out of 5 criteria. However, we could not demonstrate the pathognomonic IgA deposition on direct immunofluorescence staining due to lack of resources. HSP commonly occurs in children (90%) with only 3.4 to 14.3 cases per million reported in the adult population.¹² Important predictors of renal disease are age of onset, presence of renal impairment, hematuria and abdominal pain at onset, persistent eruption and renal pathology with fibrinoid necrosis and number of sclerotic glomeruli.¹³

Like LCV, HSP is thought to be triggered by a broad spectrum of antigens comprising infectious agents, tumours, auto-immune connective tissue disorders, drugs.

Evaluation of patients presenting with small vessel vasculitis should include complete and differential blood count, erythrocyte sedimentation rate, urine analysis with microscopy, liver and renal function tests, infectious serologies/cultures (blood, urine, swabs), chest X-ray, ultrasonography of abdomen and pelvis, Hepatitis B, C, HIV screening, skin biopsy (haematoxylin and eosin, direct immune fluorescence) and stool examination.

Additional investigations constitute RA factor, ASO titres, antinuclear antibody/extractable nuclear antigen, complement (CH50, C3, C4), anti-double stranded DNA (anti-ds DNA), antineutrophil cytoplasmic antibodies (proteinase-3/myeloperoxidase), gastrointestinal evaluation/stool guaiac test for occult blood.

Patients with idiopathic cutaneous LCV may exhibit various disease patterns as seen in our patient. Most cases self-resolve within 3-4 weeks. Some patients may flare only intermittently, perhaps for 2 weeks every other year; others have recurrent flares every 3-6 months or intractable disease with new lesions almost every day or week for years. Our patient had a history of similar episode in the past which had resolved spontaneously.

Identifying and controlling triggers or exacerbating factors such as prolonged standing, alcohol use or specific drug use can help as can wearing compression stockings and keeping the feet elevated. Bed rest can accelerate the regression of skin lesions.

Diet has long been implicated as an inciting factor for clinical cutaneous manifestations such as LCV. Two case series have shown moderate success in the treatment of cutaneous LCV with empiric elimination diets. Bland, low-antigenic diets were shown to prevent recurrences of palpable purpura, as well as to decrease serum levels of either immune complexes or cryoglobulins.¹⁴

Colchicine (0.6-1.8 mg/day) and dapsone (anti-inflammatory effect) have shown clinical resolution in patients with vasculitis. Prednisolone (initial doses of 0.5-1 mg/kg daily), with prolonged tapering to prevent rebound, can be very effective to treat acute or single episode of LCV. For recurrent, chronic, symptomatic idiopathic vasculitis, steroid-sparing agents, such as azathioprine, mycophenolate mofetil, and cyclosporine can be given.¹⁴

Most common organ involved in LCV is the skin, which mainly manifests as palpable purpura predominantly on dependent areas such as lower limbs and buttock region, however, other dermatological lesions such as maculopapular rash, urticaria, nodules and ulceration can be the presenting complaints. Our case presented with vesico-bullous and hemorrhagic necrotic skin lesions,

which occur in 35% individuals.^{12,15} In 50% of cases of LCV, other systems such as renal, gastrointestinal, pulmonary, cardiovascular, and central nervous may be involved. Vasculitis involving the kidneys associated with hematuria and proteinuria can be life-threatening.¹⁶

CONCLUSION

Adult-onset Henoch Schoenlein purpura, although rare and likely to be missed, deserves a place in the differential diagnosis of cutaneous small vessel vasculitis. Management of cryptogenic leukocytoclastic vasculitis can be challenging. All patients presenting with palpable purpura must undergo thorough workup to identify any underlying cause. Also, more research is warranted to establish if LCV and HSP are harbingers of connective tissue disease emphasising the need for a long-term follow-up with stringent clinical and laboratory monitoring.

Funding: No funding sources

Conflict of interest: None declared

Ethical approval: Not required

REFERENCES

1. Leukocytoclastic Vasculitis. Available at: <https://www.ncbi.nlm.nih.gov/books/NBK482159/>. Accessed on 2 March 2021.
2. Abdgawad M. History, classification and pathophysiology of small vessel vasculitis. Updates in the diagnosis and treatment of vasculitis. Intech Open. 2013:1-30.
3. Piubelli MLM, Felipe-Silva A, Kanegae MY, Ferraz CFP. Fatal necrotizing Candida esophagitis in a patient with leukocytoclastic cutaneous vasculitis and ankylosing spondylitis. Autops Case Rep. 2019;9(2):e2018070.
4. Younger DS, Carlson A. Dermatologic aspects of systemic vasculitis. Neurol Clin. 2019;37(2):465-73.
5. Alqorain NAA, Aljabr ASH, Alghamdi NJ. Cutaneous polyarteritis nodosa treated with pentoxifylline and clobetasol propionate: a case report. Saudi J Med Med Sci. 2018;6(2):104-7.
6. Einhorn J, Levis JT. Dermatologic diagnosis: leukocytoclastic vasculitis. Perm J. 2015;19(3):77-8.
7. Rheumatology advisor. Leukocytoclastic vasculitis. Available at: <https://www.rheumatologyadvisor.com/home/decision-support-in-medicine/rheumatology/leukocytoclastic-vasculitis/>. Accessed on 2 March 2021.
8. Fekete GL, Fekete L. Cutaneous leukocytoclastic vasculitis associated with erlotinib treatment: A case report and review of the literature. Exp Ther Med. 2019;17(2):1128-31.
9. Li X, Xia J, Padma M, Ma Z, Tian Y. Cutaneous leukocytoclastic vasculitis as the first manifestation of malignant syphilis coinfecting with human immunodeficiency virus. J Cutan Pathol. 2019;46(5):393-5.
10. Borahay MA, Kelly BC, Harirah HM. Systemic lupus erythematosus presenting with leukocytoclastic vasculitis and seizure during pregnancy. Am J Perinatol. 2009;26(6):431-5.
11. Yang YH, Yu HH, Chiang BL. The diagnosis and classification of Henoch-Schönlein purpura: an updated review. Autoimmun Rev. 2014;13(4-5):355-8.
12. Jithpratuck W, Elshenawy Y, Saleh H, Youngberg G, Chi DS, Krishnaswamy G. The clinical implications of adult-onset henoch-schonlein purpura. Clin Mol Allergy. 2011;9(1):9.
13. Pillebout E, Thervet E, Hill G, Alberti C, Vanhille P, Nochy D. Henoch-Schönlein Purpura in adults: outcome and prognostic factors. J Am Soc Nephrol. 2002;13(5):1271-8.
14. Russell JP, Gibson LE. Primary cutaneous small vessel vasculitis: approach to diagnosis and treatment. Int J Dermatol. 2006;45(1):3-13.
15. Pillebout E, Thervet E, Hill G, Alberti C, Vanhille P, Nochy D. Henoch-Schönlein Purpura in adults: outcome and prognostic factors. J Am Soc Nephrol. 2002;13(5):1271-8.
16. Agrawal SR, Rajput A, Jain AP. Leukocytoclastic vasculitis and acute allergic interstitial nephritis following ceftriaxone exposure. J Pharmacol Pharmacother. 2014;5(4):268-70.

Cite this article as: Belgaumkar VA, Chavan RB, Deshmukh NS, Gowda RK. The enigma of adult onset Henoch Schoenlein purpura and leukocytoclastic Vasculitis: a case report. Int J Res Dermatol 2021;7:482-6.