

## Original Research Article

# Fractional erbium-YAG laser vs platelet rich plasma in acne scar: a comparative study

Neeti Kumari, Arun Kumar\*, Jitendra S. Bist, Anil K. Mehta

Department of Dermatology, Venereology and Leprosy Shri Guru Ram Rai Institute of Medical and Health Sciences Dehradun, Uttarakhand, India

**Received:** 07 December 2020

**Revised:** 25 December 2020

**Accepted:** 28 Decemberr 2020

### \*Correspondence:

Dr. Arun Kumar,

E-mail: drarunkumar007@gmail.com

**Copyright:** © the author(s), publisher and licensee Medip Academy. This is an open-access article distributed under the terms of the Creative Commons Attribution Non-Commercial License, which permits unrestricted non-commercial use, distribution, and reproduction in any medium, provided the original work is properly cited.

### ABSTRACT

**Background:** Facial acne scar is a common complication of acne vulgaris leading to social isolation, lack of self-confidence and depression that warrants multiple treatment approach. In recent years, fractional erbium-yttrium aluminum garnet (er-YAG) 2940 nm laser and platelet-rich plasma (PRP) have been used independently or in combination with other resurfacing modalities in treating acne scars with variable outcomes. The objective of this study is to compare the therapeutic responses and safety of fractional erbium-YAG 2940 nm laser and platelet-rich plasma in atrophic post acne scars.

**Methods:** Patients were randomly divided into two groups (30 each), receiving six sittings of fractional er-YAG laser and PRP every month. Response was evaluated 4 weeks after each treatment session using Goodman and Baron qualitative acne scar grading system, photographic assessment by 2 blinded dermatologist and patients own satisfaction.

**Results:** Both treatment modalities showed improvement of acne scars, but the improvement with fractional er-YAG laser (27% marked and 70% moderate response) treatment was higher in comparison to PRP (10% marked and 67% moderate response) in terms of acne scar grade severity ( $p=0.33$ ). Similar results were obtained on photographic assessment ( $p=0.015$  and  $0.021$ ), and patient's own satisfaction ( $p=0.011$ ), respectively. Pain and stinging score were lower in er-YAG group while down time for same was shorter in PRP.

**Conclusions:** Both er-YAG laser and PRP showed significant improvement in atrophic acne scar while former showing slightly superior response with lesser adverse effects.

**Keywords:** Acne scars, Erbium-YAG laser; Platelet-rich plasma

### INTRODUCTION

Acne vulgaris is a chronic inflammatory disease of the pilosebaceous unit characterized by open and closed comedones along with papules, pustules and nodules of varying degree of inflammation and depth.<sup>1</sup> The pathogenesis of acne is multifactorial, including increased biology of sebaceous gland, sebum production, follicular hyper keratinization, *Propionibacterium acnes* (*P. acnes*) proliferation, hormonal factors, nutrition,

activation of toll-like receptor 2 (tlr-2), many cytokines production and genetic predisposition.<sup>2</sup>

Facial acne scar is a common complication of acne vulgaris mostly attributed to delayed treatment which can further lead to social isolation, lack of self-confidence and depression and hence warrants proven and safe treatment modalities.<sup>3</sup>

Acne scar can be atrophic, hypertrophic and keloidal. Atrophic acne scars have been further classified

morphologically according to their depth and width into rolling, box, icepick scars which determines the choice of treatment modality.<sup>4</sup>

Goodman and baron in 2006 proposed a qualitative global grading system, which has been used for assessment of atrophic acne scar due to its ease of use and universal application. Based on the severity of acne it rates them as macular, mild, moderate and severe.<sup>5</sup>

Various treatment modalities have been used in the past for the treatment of acne scar with variable outcomes such as medical, procedural and surgical. Laser resurfacing is one such approach which is very effective and easy to use. The standard laser which has been used vastly for scar resurfacing is fractional CO<sub>2</sub> and Erbium-YAG laser. The 2940 nm fractional er-YAG laser is 10 times more selective for water chromophores than CO<sub>2</sub> laser.

Fractional laser acts by fractional photo thermolysis causing microscopic wound by creating micro-thermal zones therefore treating 20, 40 or 90% of the area. Due to selective photo thermolysis healing is quick with a shorter recovery period and improvement in skin texture, wrinkles, pigmentation, scar and overall lesser side effects. Also, with these lasers adverse effects like erythema and post inflammatory hyperpigmentation (PIH) are very less.<sup>6</sup>

Platelet-rich plasma (PRP) treatment is performed via injection of autologous high concentration of platelets in a small volume of plasma. The most important contents of platelets are present in the alpha granule containing more than 30 bioactive substances. The bioactive substances such as platelet-derived growth factor (PDGF), transforming growth factor (TGF)- $\beta$ 1,  $\beta$ 2, epidermal growth factor, and mitogenic growth factors such as platelet-derived angiogenesis factor and fibrinogen promote wound healing, angiogenesis and tissue remodeling.<sup>7</sup>

## METHODS

A prospective randomized controlled study was conducted after taking approval of the institutional ethics committee amongst, patients attending general out patient department of dermatology, venereology and leprosy at Shri Guru Ram Rai institute of medical and health sciences, Patel Nagar, Dehradun, Uttarakhand for a duration of 18 months from November 2018 to April 2020.

Sixty patients were randomly selected from our outpatient clinic who were willing to go for the study. The participants who had multiple bilateral acne scar, aged between 18-35 years, any gender and not on any topical or systemic treatment for acne scar for at least a month prior to study period were included. Whereas patients with active cutaneous infection at the site of

treatment, e.g., Herpes simplex infection or staphylococcus infection, having risk of Koebnerization; e.g., Unstable psoriasis or vitiligo, photo aggravated systemic illness e.g., SLE, with synthetic fillers in the treatment area, keloidal tendency, immunosuppression, bleeding tendency were excluded from the study.

After taking history and clinical examination patient were randomly divided into two groups (of 30 each) based on inclusion and exclusion criteria. Group A received six sessions of Er-YAG laser while group B received six sessions of platelet rich plasma over the multiple scars every month. Clinical grading was noted based on Goodman and Baron grading scale four weeks post each treatment session and digital photographs were taken for further evaluation. The treatment protocol, procedure, need of pre- and post-treatment photographs were fully described to each patient and informed consent was taken. Further the work got approval from institutional ethics committee of SGRRIM and HS Dehradun, prior to execution of the study.

Er-YAG Laser protocols: Patient were given three passes (horizontal, vertical and oblique) of Fr-Er-YAG laser in the treatment area with fluence of 800mj/p at first session, increasing to 1000 mjp at second session and 1200 mjp in remaining third to sixth session. Fourth pass was given over scar with higher fluences of 1000, 1200, and 1400 mjp respectively.

PRP protocols: In our study we prepared PRP with double spin method. 30-45 ml of venous blood was collected in 4 sterile sodium citrate tube. In first spin each tube was centrifuged at 1500 rpm for 15 min. Plasma and buffy coat were cautiously collected and transferred to plain tubes without anticoagulant and subjected to second spin at 3000rpm for 15 min. The upper two third contains platelet poor plasma (PPP) and lower one third platelet rich plasma (PRP) with platelet pellets deposited at the bottom. Thus 30-35 ml blood gives roughly 4-5 ml of PRP having a four to seven-fold of increased platelet count of at least 1 million/cumm.

After taking aseptic precautions, PRP was then injected intradermally using 30 G insulin syringes into the base of the scar and treatment area. Remaining PRP was instilled topically followed by local massage. Oral antibiotic course was given for 5 days.

## Statistical analysis

Statistical was done using software (SPSS, version 20.0 statistical package). Continuous variables were evaluated using mean and standard deviation. P value was considered significant if it was <0.05. Kappa value was used to compare agreement between observers and patients. Agreement was considered strong if kappa value was >0.7.

**Assessment**

Pre- treatment and post-treatment scars were graded by the same physician using Goodman and Baron scale and improvement in the grades were noted.

Photographic assessment- color photographs were taken using a digital still camera at the baseline, 1<sup>st</sup>, 3<sup>rd</sup> and 6<sup>th</sup> session. Photographs were assessed for the degree of improvement comparing the same with baseline by two blinded dermatologist and improvement was graded as grade 1=minimal (0-25%), grade 2=moderate (26-50%), grade 3=marked (51-75%), grade 4=excellent (76-100%).

Similarly, patients' satisfaction regarding the improvement of acne scars during the course of intervention:<sup>8,9</sup> grade 1=minimal/slightly satisfied (0-25%); grade 2=moderate/partially satisfied (26-50%); grade 3=marked/greatly satisfied (51-75%); grade 4=excellent/completely satisfied (76-100%) was also done.

Patients were also evaluated for any adverse reaction on every visit.

**RESULTS**

A total of 60 patients were enrolled in the study with age ranging from 18-35 years and with similar mean age 24.67±3.92 year in er-YAG laser and 25.07±4.54 years in PRP. There were 63.0% female and 33.0% male in the Er-YAG Laser group in comparison to 70.0% female and 30.0% male in the PRP group.

**Table 1: Pre-treatment and post-treatment grades.**

Grades	Pre Treatment (%)		Post treatment (%)		P value
<b>Er-YAG laser</b>					
Macular	0	0	11	37	0.001
Mild	3	10	16	53	
Moderate	25	83	3	10	
Severe	2	7	0	0	
<b>PRP</b>					
Macular	0	0	3	10	0.023
Mild	1	3	18	60	
Moderate	26	87	9	30	
Severe	3	10	0	0	

The mean of acne severity grade pre-treatment was 2.97±0.41 in er-YAG and 3.07±0.37 in PRP which reduced to 1.73±0.64 in er-YAG laser and 2.20±0.61 in PRP (p=0.005) after the last sitting (post-treatment).

Pre-treatment in both groups: majority of the participants had moderate grades 25 (83%) in er-YAG and 26 (87%) in PRP. This improved to macular (37%) and mild (53%) in er-YAG in comparison to PRP treated subjects with mild (60%) and moderate (30%) improvement.

**Photographic assessment**

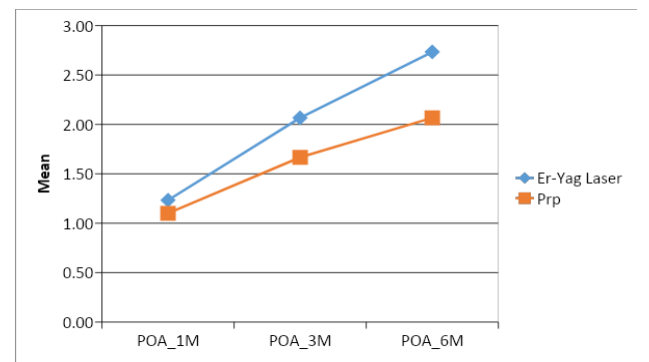
Photographic assessment by blinded dermatologist reported excellent, marked and moderate improvement in 7, 33 and 57% respectively in the er-YAG laser group. The same was nil, 10, and 67% in the PRP group.

**Table 2: Photographic assessment post-treatment.**

Improvement grades	Er-YAG laser (%)		PRP (%)		Total	P
<b>Minimal 1</b>	1	3	7	23	8	0.015
<b>Moderate 2</b>	17	57	20	67	37	
<b>Marked 3</b>	10	33	3	10	13	
<b>Excellent 4</b>	2	7	0	0	2	
<b>Total</b>	30	100	30	100	60	

**Self-evaluation by patient**

Majority of the patients experienced marked to excellent response in (60%) er YAG laser in contrast to PRP where majority reported minimal to moderate response i.e., 77% at the end of final sitting.



**Figure 1: Patients own satisfaction post each session.**

**Table 3: Patients own satisfaction.**

Variables		Group				Total	P value
Grade	Improvement (%)	Er-YAG laser		PRP			
1	Minimal (0-25)	1	3	5	17	6	0.011
2	Moderate (25-50)	11	37	18	60	29	
3	Marked (50-75)	13	43	7	23	20	
4	Excellent (75-100)	5	17	0	0	5	
Total		30	100	30	100	60	

Both er-YAG and PRP groups show substantial agreement between observers whereas agreement of patients with both the observers is only slight due to higher patients' own satisfaction scores for improvement in acne scar severity.

**Table 4: Agreement between observers and with patient satisfaction.**

Variable	PA 1	PA 2	PA 1	PO A	PA 2	PO A
<b>Er-YAG laser</b>						
Kappa value	0.883		0.318		0.321	
P	0.000		0.001		0.010	
<b>PRP</b>						
Kappa value	0.873		0.504		0.587	
P	0.000		0.000		0.000	

PA1-Photographic assessment by first blinded dermatologist, PA2-Photographic assessment by second blinded dermatologist, POA-Patient own assessment.

**Adverse effects**

Erythema was observed immediately by all the participants in both the group which resolved in majority of the patients after 7 days. Pin point hemorrhage followed by crusting persisted for 4-7 days in er-YAG group, which resolved within 2-3 days in PRP group. PIH developed in both the groups after about seven days of treatment but persisted in 20% of patients' belonging to er-YAG laser versus only 10% who received PRP.

**DISCUSSION**

In the absence of any standard protocol, numerous treatment modalities have been used for the treatment of acne scar such as topicals, chemical peels, micro needling, surgical procedure, including laser and PRP with variable outcomes. Although lot of literature have been published on single modality use of er-YAG laser or PRP for acne scars, only few studies have compared the two with regard to its efficacy and safety.<sup>10</sup>

Both PRP and fractional er-YAG laser are found to be effective and safe for the treatment of acne scar but er-YAG laser was found to be superior with respect to objective assessment done by dermatologist, patient's own satisfaction and tolerance, indicating a higher efficacy of fractional er-YAG laser than PRP.

The wavelength of er-YAG laser is 2940 nm, corresponding to the peak absorption coefficient of water. It is absorbed 12 times or more by water-containing cutaneous tissue than the 10,600 nm wavelength of the CO<sub>2</sub> laser.<sup>11</sup> Thus fractional er-YAG laser via fractional photo thermolysis creates micro-thermal zones in the skin, therefore treating 20, 40 or 90% of the area producing lesser ablative and coagulative depth than

fractional CO<sub>2</sub> laser yielding comparable efficacy with lower downtime and lesser side effects.<sup>12</sup>

The study demonstrates that the er-YAG laser is more effective as compared to PRP in the treatment of acne scar as 97% in er-YAG and 77% in the PRP group showed more than 25% improvement. Similar results were obtained in previous studies done by Jeong and Kutlubay et al.<sup>13,14</sup> Blinded dermatologists assessed marked improvement in 40% subjects of the er-YAG group. Similarly, majority of patients evaluated themselves with marked to excellent response in er-YAG laser group (60%) implying better satisfaction rating by patient with the same probably due to additional improvement in fine line, pores, and overall rejuvenation. Similar results were postulated in earlier studies for patient's satisfaction scores.<sup>15-19</sup>

Both er-YAG and PRP groups demonstrated substantial agreement among the observers ( $\kappa=0.883$ ) for improvement in acne scar severity whereas agreement of patients with both the observers ( $\kappa=0.318, 321$ ) was only slight due to higher grades of patients' own satisfaction. Similar observations in the agreement were noted by Nirmal et al and Goldust et al.<sup>17,18</sup>

In the present study when acne scar types were compared for response with laser, rolling scars showed better response with statistically significant difference ( $p=0.022$ ). Similar responses were observed for rolling and box scar with fractional laser in comparison to icepick scar in previous studies.<sup>15,18</sup> This can be attributed to deeper depth of ice pick scar than the ablative depth of the laser.<sup>4</sup>

The results revealed that the majority of participants receiving PRP showed minimal (23%) to moderate (67%) change with respect to grade change. Photographic assessment done by blinded dermatologists also noted minimal (27%) to moderate (60%) improvement with similar responses perceived by patients as well. These results coincide with previous studies by Gulanikar and Al Teib et al with an improvement in scar grade, clinical appearance, and patient satisfaction compared with their baseline measurements.<sup>16,20</sup> In Babu et al study baseline mean of grades ( $3.27\pm0.25$ ) improved to final grade ( $2.87\pm0.48$ ) which was comparable to present study.<sup>21</sup> Further the improvement was better in the present study which can be attributed to a greater number of treatment sessions and longer duration of follow-up.

Lee, Chawla, Asif and Ibrahim et al in their work combined PRP as an adjunct to laser and micro needling and found that PRP was more effective as combined treatment than either modality alone.<sup>22-24</sup> This can be explained by the fact that platelets contain alpha-granules and secrete several growth factors, such as transforming growth factor-beta, platelet-derived growth factor, vascular endothelial growth factor, and others.<sup>26</sup> These growth factors and other proteins, such as adhesion

molecules and chemokines, interact with the local environment to promote cell differentiation, proliferation, and regeneration and enhance proliferation of human adipose tissue.

In the present study erythema and edema occurred immediately which was resolved within 7 days. Pinpoint hemorrhage followed by crusting was more with the er-YAG group as compared to PRP and resolved within 5-7 days.

Post inflammatory hyperpigmentation which developed by 7 days in both the groups persisted post-treatment more in er-YAG (20%) which is consistent with the findings of Jeong (22%) and Mauskiatti et al (35%) in contrast to Chatra (1.25%), Nirmal (2%) and Al Teib (8%). The higher incidence of side effects in er-YAG can be attributed to the long pulse used resulting in more thermal damage. Patients treated with PRP reported PIH in fewer subjects (10%) as seen with Gulanikar et al in only one patient and none in Babu et al. The reason for less pigmentation in the PRP group might be that TGF- $\beta$ , which is released by PRP, is also known to decrease melanogenesis.

Pain score at each sitting was lower with er-YAG (3.33 $\pm$ 1.15) laser in comparison to PRP (4.43 $\pm$ 1.57) showing a decreasing trend with subsequent sittings in both the groups. Mean pain scores in er-YAG lasers are consistent with the findings of Osman (4.27 $\pm$ 1.61) and Manuskaitti et al (3.5 $\pm$ 1.7).<sup>27,28</sup> Statistically significant difference (p=0.003) was seen in mean pain score, thereby making less invasive procedures like er-YAG laser more acceptable.

### Limitations

The sample size was moderate, therefore drawing inferences for various subcategories might not be statistically significant.

### CONCLUSION

Fractional er-YAG laser holds an advantage as it can provide a variable range of thermal depths with early healing and lesser adverse effects. Minimal pain makes it more acceptable as compared to CO<sub>2</sub> laser and PRP. In present study, both er-YAG laser and PRP, alone showed significant improvement in atrophic acne scar while former reported slightly superior response as 97% of the subjects showed more than 25% improvement as compared to only 77% in PRP. Similar observations were noted by the blinded observers and the patient themselves for fractional er-YAG laser. Thus, it can be said that the versatile er-YAG laser is a safe and effective modality in the treatment of acne scars.

*Funding: No funding sources*

*Conflict of interest: None declared*

*Ethical approval: The study was approved by the institutional ethics committee*

### REFERENCES

1. Rook's textbook of dermatology, 9<sup>th</sup> edition. Edited by Griffiths. Barker, Bleiker, Chalmers, Creamer, Blackwell Publishing Ltd. Cole GT. 2010;9(90):90-1.
2. Kurokawa I, Danby FW, Ju Q, Wang X, Xiang LF, Xia L et al. New developments in our understanding of acne pathogenesis and treatment. *Experim dermatol.* 2009;18(10):821.
3. Chuah SY, Goh CL. The Impact of Post-Acne Scars on the Quality of Life Among Young Adults in Singapore. *J Cutaneous Aesthetic Surg.* 2015;8(3):153-8.
4. Jacob CI, Dover JS, Kaminer MS. Acne scarring: a classification system and review of treatment options. *J Am Acad Dermatol.* 2001;45(1):109-17.
5. Goodman GJ, Baron JA. Postacne scarring: a qualitative global scarring grading system. *Dermatologic Surg.* 2006;32(12):1458-66.
6. Loesch M, Somani AK, Kingsley MM, Travers JB, Spandau DF. skin resurfacing procedures new and emerging options. *Clin Cosmetic Investig Dermatol.* 2014;7(6):231-41.
7. Tavares Filho JM, Belerique M, Franco D, Porchat CA, Franco T. Tissue expansion in burn sequelae repair. *Burns.* 2007;33:246-51.
8. Al-Dhalimi M, Jaber A. Treatment of atrophic facial acne scars with fractional Er:Yag laser. *J Cosmet Laser Ther.* 2015;17(4):184-8.
9. Osman MA, Shokeir HA, Fawzy MM. Fractional Erbium-Doped Yttrium Aluminum Garnet Laser Versus Microneedling in Treatment of Atrophic Acne Scars: A Randomized Split-Face Clinical Study. *Dermatol Surg.* 2017;43(1):S47-56.
10. Thiboutot DM, Abanmi A, Araviiskaia E, Baron Cabal MI, Bettoli V. Practical management of acne for clinicians: an international consensus from the global alliance to improve outcomes in acne. *J Am Acad Dermatol.* 2018;2(1):1-23.
11. Tanzi EL, Alster TS. Single-pass carbon dioxide versus multiple pass Er:YAG laser skin resurfacing: a comparison of postoperative wound healing and side-effect rates. *Dermatol Surg.* 2003;29:80-4.
12. Manuskiatti W, Triwongwanat D, Varothai S, Eimpunth S, Wanitphakdeedecha R. Efficacy and safety of a carbon-dioxide ablative fractional resurfacing device for treatment of atrophic acne scars in Asians. *J Am Acad Dermatol.* 2010;63:274-83.
13. Jeong JT, Park JH, Kye YC. Resurfacing of pitted facial acne scars using Er:YAG laser with ablation and coagulation mode. *Aesthetic Plast Surg.* 2003;27(2):130-4.
14. Kutlubay Z, Gokdemir G. Treatment of atrophic facial acne scars with the Er:YAG laser: a Turkish experience. *J Cosmet Laser Ther.* 2010;12:65-72.
15. Chathra N, Mysore V. Resurfacing of facial acne scars with a new variable-pulsed Er:YAG laser in

- Fitzpatrick skin types IV and V. *J Cutan Aesthet Surg*. 2018;11:20-5.
16. Moustafa T, Hassan I, Eisa M, Ahmed I, Aya G, Essam N. Fractional Erbium-YAG Laser and Platelet-Rich Plasma as Single or Combined Treatment for Atrophic Acne Scars: A Randomized Clinical Trial. *Dermatol Therapy*. 2019;9:10.
  17. Goldust M. The efficacy and safety of Er:YAG laser for treatment of atrophic acne scars *Glob Dermatol*. 2014;1(2):47-50.
  18. Nirmal B, Pai SB, Sripathi H. Efficacy and safety of erbium-doped yttrium aluminium garnet fractional resurfacing laser for treatment of facial acne scars. *Indian J Dermatol Venereol Leprol*. 2013;79(2):193-8.
  19. Cenk H, Sarac G. Effectiveness and safety of 2940-nm multifractional Er:YAG laser on acne scars. *Dermatol Ther*. 2020;e14270.
  20. Gulanikar AD, Vidholkar R. Efficacy of platelet-rich plasma in acne scars. *Clin Dermatol Rev*. 2019;3:109-14.
  21. Babu AM, Shettyvh Goel S, Eram H. A comparative study of efficacy and safety of platelet rich plasma versus fractional co2 laser in the treatment of post acne scars. *Int j res Dermatol*. 2019;5:254-8.
  22. Lee JW, Kim BJ, Kim MN. The efficacy of autologous platelet rich plasma combined with ablative carbon dioxide fractional resurfacing for acne scars: a simultaneous split-face trial. *Dermatol Surg*. 2011;37(7):931-8.
  23. Chawla S. Split face comparative study of microneedling with PRP versus microneedling with vitamin C in treating atrophic post acne scars. *J Cutan Aesthet Surg*. 2014;7(4):209-12.
  24. Asif M, Kanodia S, Singh K. Combined autologous platelet-rich plasma with microneedling verses microneedling with distilled water in the treatment of atrophic acne scars: a concurrent split-face study. *J Cosmet Dermatol*. 2016;15(4):434-43.
  25. Ibrahim MK, Ibrahim SM, Salem AM. Skin microneedling plus platelet-rich plasma versus skin microneedling alone in the treatment of atrophic post acne scars: a split face comparative study. *J Dermatolog Treat*. 2018;29:281-6.
  26. Ibrahim ZA, El-Ashmawy AA, Shora OA. Therapeutic effect of microneedling and autologous platelet rich plasma in the treatment of atrophic scars: a randomized study. *J Cosmet Dermatol*. 2017;16:388-99.
  27. Osman MA, Shokeir HA, Fawzy MM. Fractional Erbium-Doped Yttrium Aluminum Garnet Laser Versus Microneedling in Treatment of Atrophic Acne Scars: A Randomized Split-Face Clinical Study. *Dermatol Surg*. 2017;43(1):S47-56.
  28. Manuskiatti W, Iamphonrat T, Wanitphakdeedecha R, Eimpunth S. Comparison of fractional erbium-doped yttrium aluminum garnet and carbon dioxide lasers in resurfacing of atrophic acne scars in Asians. *Dermatol Surg*. 2013;39:111-20.

**Cite this article as:** Kumari N, Kumar A, Bist JS, Mehta AK. Fractional erbium-YAG laser vs platelet rich plasma in acne scar: a comparative study. *Int J Res Dermatol* 2021;7:223-8.