

## Original Research Article

# A study of clinical and dermoscopic features in alopecia areata at a tertiary referral center

Nikhil N., Mamatha P.\*, Hanumanthayya K.

Department of Dermatology, Vydehi Institute of Medical Sciences and Research Center, Bengaluru, India

**Received:** 27 September 2020

**Accepted:** 12 October 2020

**\*Correspondence:**

Dr. Mamatha P.,

E-mail: [drmamathapappala@yahoo.com](mailto:drmamathapappala@yahoo.com)

**Copyright:** © the author(s), publisher and licensee Medip Academy. This is an open-access article distributed under the terms of the Creative Commons Attribution Non-Commercial License, which permits unrestricted non-commercial use, distribution, and reproduction in any medium, provided the original work is properly cited.

### ABSTRACT

**Background:** Alopecia areata (AA) is a common chronic inflammatory disease causing unpredictable non scarring form of hair loss. Dermoscopy is a clear cut as well as valuable method done in a noninvasive manner to study the signs of alopecia areata. Aim was to elucidate the various clinical characteristics and dermoscopic findings of alopecia areata.

**Methods:** A total of 150 patients were examined using a dermlite dermoscope at dermatovenereology OPD of Vydehi Hospital. Detailed history, clinical features, associated changes, severity and dermoscopic findings were noted.

**Results:** In our study males (54.7%) were more than females (45.35%) with the ratio of 1.2:1. Mean age of the patients was 25 years. Mean duration of the disease was around 6 months. The most common type noted in our study was patchy alopecia (76%) and most common affected site was scalp (frontal and parietal region) (49.35%). 28% of the people have itching, otherwise it is mostly asymptomatic. Stress was a triggering factor in 24.70% patients. Nail changes in the form of pitting seen in 20.7% patients. The various dermoscopic findings observed in our study are yellow dots (80%), short vellus hair (74.7%), exclamation hair (34%), black dots (28%), broken hair (25.3%).

**Conclusions:** Short vellus hair and yellow dots are seen in most cases of our study. They vary according to the activity of the disease and treatment. Yellow dots, black dots and tapering hair indicate active disease, while short vellus hairs indicate remission.

**Keywords:** Dermoscopy, Alopecia areata, Yellow dots, Short vellus hair

### INTRODUCTION

Alopecia areata (AA) is a hair loss disorder which is common, clinically heterogenous, immune-mediated, and non-scarring.<sup>1</sup> The global prevalence is approximately 0.1 to 0.2% with a lifetime risk of 1.7%.<sup>2</sup> AA accounts for 25% of all alopecia cases presenting to the dermatologists and 2-3% of all new outpatient dermatology services in the USA and the UK, 3.8% in China, and 0.7% in India.<sup>3</sup> It can occur at any age but incidence is higher among younger individuals.

AA is an autoimmune disease, driven by cytotoxic T lymphocytes directed against the hair follicle. Of late,

signaling pathways that converge on downstream effector janus kinases have been identified in the pathogenesis of AA.<sup>4</sup> Clinically AA is subcategorized according to pattern into patchy, reticular, ophiasis, sisaipho, diffuse and according to the extent of involvement into alopecia totalis, alopecia universalis and alopecia sub totalis.<sup>5</sup>

Diagnosis is based mainly on the clinical presentation and is corroborated by histology. Clinically it presents as well circumscribed round or oval bald patches with smooth surface and characteristic exclamation hair. Doubtful cases have to be confirmed with biopsy which is a painful procedure. Trichoscopy provides a non-invasive option

that can be used to establish the diagnosis and monitor the progression.

Trichoscopy is the term introduced in 2006 by Rudnicka et al for the use of dermoscope for the evaluation of hair and scalp in health and disease.<sup>6</sup> Dry dermoscopy is ideal because it has a blocking filter against light reflection from the skin surface.<sup>7</sup> It magnifies subtle clinical surface features of skin lesion as well as exposes some sub surface skin structures, normally not visible even with a magnifying lens.<sup>3</sup> The key dermoscopic features of AA are yellow dots, black dots, broken hairs, exclamation point hairs and short vellus hairs.<sup>8</sup> With this knowledge we conducted a study to evaluate various dermoscopic pattern in AA that help in diagnosing and assess the disease severity.

**METHODS**

*Study design*

This is a cross-sectional study, which was carried out on total 150 patients both male and female with Alopecia Areata (AA) in the Department of Dermatology, Venereology and Leprosy at Vydehi Institute of Medical Sciences and Research Centre, Whitefield, Bengaluru, Karnataka, India. Institutional ethical committee clearance was obtained.

The study was time bound from January 2017 to June 2018. Inclusion criteria being all diagnosed patients of AA who were willing to provide informed consent. Exclusion criteria being hair loss due to all other causes including androgenetic alopecia. Informed written consent of the participating patients was taken. A pre-structured proforma was used to collect the baseline data. Detailed history was taken, and clinical and dermatological examination was done and disease severity was graded. The hair and scalp were evaluated using a dermoscope (Dermlite, 3 Gen LLC, San Juan Capistrano, CA, USA) with 10x magnification and polarised filters for follicular and interfollicular patterns. Additional investigations including skin biopsy were done as and when required.

Disease severity was graded according to SALT score (severity of alopecia tool).<sup>9</sup> In this the entire scalp is divided in to four parts based on the surface area. They are as follows: (a) top (40%=0.4), (b) posterior (24%=0.24), (c) right side (18%=0.18), (d) left side (18%=0.18). Percentage of hair loss in each area is determined independently and is multiplied by the percentage of hair covered in that area of scalp and summing the products of each area will give the SALT score. It is graded as follows: S0- no hair loss, S1-25% hair loss, S2-26% to 50% hair loss, S3-51% to 75% hair loss, S4-76% to 99% hair loss & S5-100% hair loss. Where S is scalp hair. And B0- no body hair loss, B1-some body hair loss, B2-100% body hair loss. B stands for body hair.

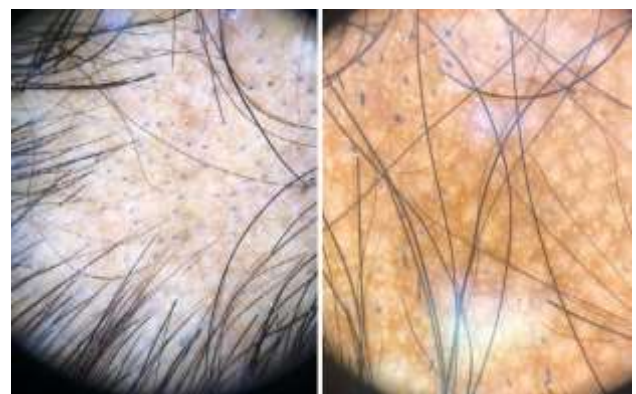
Statistical analysis of the data was done using SPSS version 21 obtaining continuous variables and expressed as mean.

**RESULTS**

One hundred and fifty patients of AA were included in the study. Out of 150 patients (Pts) 54.7% (82 Pts) were males while 45.3% (68 Pts) were females. Most of the patients were in the age group of 21-30 years (30.7%) followed by 31-40 years (28.0%). Most of the lesions have onset less than 6 months (Table 1). 68.66% (103 Pts) presented with asymptomatic patches, 28% (42 Pts) have itching and 3.3% (5 pts) have paraesthesia.

**Table 1: Demographic details of study population.**

Parameters	Number	Percentage
<b>Gender</b>		
Female	68	45.3
Male	82	54.7
<b>Age distribution</b>		
≤10	8	5.3
11-20	21	14.0
21-30	46	30.7
31-40	42	28.0
41-50	25	16.7
>50	8	5.3
<b>Associated factors</b>		
Stress	37	24.7
Illness	13	8.7
<b>Duration of disease</b>		
<6 months	114	76.0
>6 months	36	24.0



**Figure 1: Dermoscopic image-red arrow showing broken hair, yellow arrow showing tapering hair, blue arrow showing black dots and green arrow showing yellow dots.**

Stress was a triggering factor in 24.7% (37) of pts. Frontal and parietal regions were the commonest sites affected accounting for 49.3%. patchy alopecia was mostly seen in our study. It accounted for 76%, followed by alopecia universalis (8.7%). 59.3% cases are seen with

1-3 patches, pitting in the nails was seen in 20.7% of patients. 4.9% patients have specific nail changes such as thinning and trachyonychia (Table 2). In 8.7% patients AA lesions were seen on the beard. In all patient's hair pull test was done at the margin of the lesions to assess the activity. It was positive in 60% patients. According to SALT scoring, 46% patients are in S2 severity (Table 3).

**Table 2: Clinical patterns and associated nail changes.**

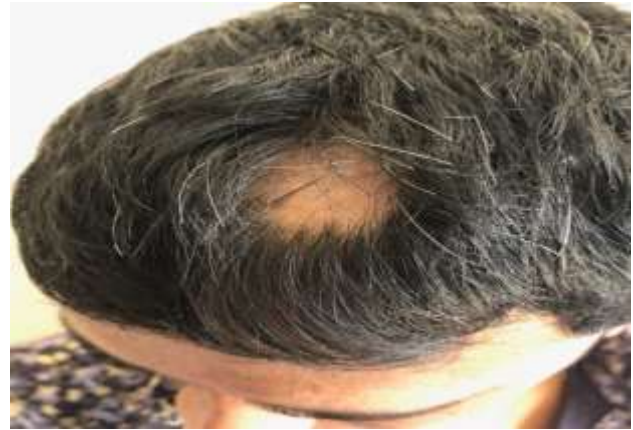Parameter	Frequency (N)	Percentage
<b>Number of patches</b>		
>7	11	7.3
1-3	89	59.3
4-7	21	14.0
<b>Diffuse</b>	29	19.3
<b>Associated symptoms</b>		
Asymptomatic	103	68.6
Itching	42	28.0
Paraesthesia	5	3.3
<b>Pattern of arrangement</b>		
AT	3	2.0
AU	13	8.7
Ophiasis	10	6.7
Patchy	114	76.0
Reticular	5	3.3
Sisaphio	5	3.3
<b>SITE</b>		
Frontal, Parietal	74	49.3
Parietal	39	26.0
Temporal	37	24.7
<b>Nail changes</b>		
No	112	74.6
PITS	31	20.7
SH	7	4.9

**Table 3: SALT scoring.**

SALT scoring	Frequency	Percentage
<b>0-24 (S1)</b>	24	16.0
<b>25-49 (S2)</b>	69	46.0
<b>50-74 (S3)</b>	14	9.3
<b>75-99 (S4)</b>	11	7.3
<b>100 (S5)</b>	32	21.3
<b>Total</b>	150	100.0

**Table 4: Dermoscopic findings.**

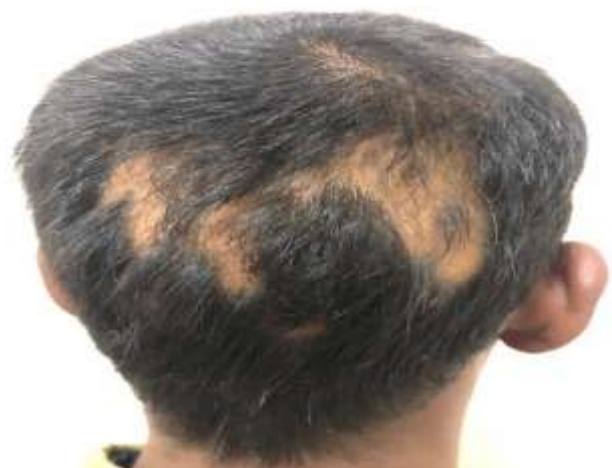Dermoscopic findings	Frequency	Percent
<b>Yellow dots</b>	120	80.0
<b>Black dots</b>	42	28.0
<b>Tapering exclamation hair</b>	51	34.0
<b>Broken hair</b>	38	25.3
<b>Short vellus hair</b>	112	74.7



**Figure 2: Solitary patch of alopecia areata in the fronto parietal region.**

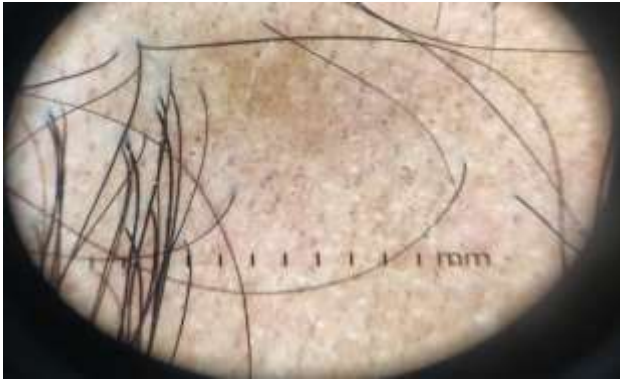


**Figure 3: Dermoscopic image-yellow arrow showing tapering hair, blue arrow showing black dots and green arrow showing yellow dots.**



**Figure 4: Multiple patches of alopecia areata over occipital region.**

Dermoscopy findings noted in our study are as follows: - yellow dots are seen in 120 Pts (80%), black dots seen in 42 patients (28%), short vellus hair seen in 112 pts (74.7%), exclamation hair seen in 51 Pts (34%), and broken hair seen in 38 pts (25.3%) (Table 4) (Figure 1 and 3).



**Figure 5: Dermoscopic image- yellow arrow showing short vellus hair.**

**DISCUSSION**

Alopecia areata (AA) is a relatively common autoimmune hair loss condition seen in dermatology clinics. Dermoscopy shows many peculiar findings in AA. In our study the mean age of participants was 25 years which is in accordance with other studies. (Table 5) (Jha et al, Hegde et al, Mane et al, Thomas et al).<sup>7,10-12</sup> Greater prevalence of alopecia was seen in 20 to 40 years of age. According to the sex distribution, 54.7% were males and 45.30% were females. Majority of the studies have shown male predominance which was similar to our study. (Table 6). In our study male to female ratio is 1.2: 1.

Ranawaka, in his hospital-based observational study of 290 adults aged 18 years or above showed that majority of patients (82.2%, n=218) were with duration less than 6 months (within 1 month 46.8%, 2 to 6 months 35.4%). The other 17.30% of patients were with AA of duration greater than 6 months.<sup>13</sup> In our present study majority of patients are with duration less than 6 months which is similar to above study. AA is generally asymptomatic, but about 14% of patients may experience a burning sensation or pruritus in the affected area.<sup>14</sup> Our study also showed 28% of patients with itching. Sellami et al proved significant psychological impact between AA, alexithymia and depression.<sup>15</sup> In our study also 24.7% of patients were with stress. Coming to site of involvement, in our study frontal and parietal sites are commonly involved accounting to 49.3% (Figure 2), followed by occipital site (26%) (Figure 4), which is in contrast to a study by Hegde et al where occiput was greatly involved (49.1%) followed by frontal and vertex (34.5% each). In a study by Mane et al also most common sites involved were occipital (28 pts) and parietal regions (24 pts).<sup>10,11</sup>

In the same study of Hegde et al patients with Patchy patterns were more in number (73.3%) followed by ophiasis involvement which is 12%. AU and AT accounted for least percentage.<sup>10</sup> In our study also same pattern distribution was seen i.e. patchy pattern was most common. Our study showed greater number of patients with lesions 1-3 (59.3%) (Figure 4) which is similar to studies by Guttikonda et al and Ranawaka et al.<sup>3,13</sup>

**Table 5: Comparison of age groups of AA with other studies.**

Study	Study subjects (N)	Mean age of the patients (years)	Range of age group (years)
<b>Our study</b>	150	25	21-50
<b>Hegde et al</b>	75	26.94	15-30
<b>Jha et al</b>	72	24.43	21-40
<b>Mane et al</b>	66	26.85	7-45
<b>Thomas et al</b>	71	-	20-40

**Table 6: Comparison of gender distribution of AA with other studies.**

Study	Study subjects (N)	Male: female ratio	Greater predominance
<b>Our study</b>	150	1.2:1	Males (54.7%)
<b>Hegde et al</b>	75	2.57:1	Males (72%)
<b>Jha et al</b>	72	1.3:1	Males (56.94%)
<b>Mane et al</b>	66	2.3:1	Males (69.7%)
<b>Thomas et al</b>	71	2.5:1	-
<b>Guttikonda et al</b>	50	1.173:1	Females

In our study face involvement was seen in 14% of patients followed by beard. This was similar to the study by Hedge et al (14.8%) and Mane et al (13.64%).<sup>10,11</sup> Pitting was most common nail change seen in our study accounting to 20.7% which is in concordance with other studies like Chelidze et al (20%) and Gandhi et al (28%).<sup>16,17</sup> Apart from pitting other changes noticed where trachyonychia and nail plate thinning similar to Bains et al.<sup>18</sup>

In a study by Bapu et al, the most common severity was S1 (72.4%).<sup>19</sup> Mahmoudi et al observed 53.3% of patients with S5 severity.<sup>20</sup> In a study by Bains and Kaur S1 severity was common (26.9%) followed by S2 (21.2%).<sup>18</sup> In our study S2 was most common accounting for 46%.

Table 7 shows the comparison of dermoscopic features of our study with other studies.

On Dermoscopy of AA various findings observed are as follows: - yellow dots (YDS): yellow dots present as round or polycyclic yellow to yellow pink dots that represent distension of affected follicular infundibulum with keratinous material. In our study yellow dots are seen in 80% (120) of patients. These are in concordance with studies done by Jha et al and other studies (Guttikonda et al).<sup>3,7</sup> Yellow dots are not easy to observe in pigmented skin so they are less in some studies. It is the most sensitive dermoscopic feature of AA. It is also found in androgenetic alopecia, telogen effluvium and dissecting cellulitis.

**Table 7: Dermoscopic features.**

Dermoscopic features	Hegde et al <sup>10</sup> (n=75)	Jha et al <sup>7</sup> (n=72)	Inui et al <sup>21</sup> (n=300)	Mane et al <sup>11</sup> (n=66)	Our study (n=150)
<b>Yellow dots</b>	57.33% (n=43)	79.16% (n=57)	63.70% (n=191)	81.80% (n=54)	80.0% (n=120)
<b>Black dots</b>	84% (n=63)	70.8% (n=51)	44.30% (n=133)	66.60% (n=44)	28.0% (n=42)
<b>Broken hairs</b>	37.33% (n=28)	43.05% (n=31)	45.70% (n=137)	55.40% (n=36)	25.3% (n=38)
<b>Short vellus hair</b>	68% (n=51)	44.44% (n=32)	72.70% (n=218)	40.90% (n=27)	74.7% (n=112)
<b>Exclamation mark</b>	18.67% (n=14)	31.9% (n=23)	31.70% (n=95)	12.1%(n=8)	34% (n=51%)

Black dots formerly called as “cadaverized hairs” are residues of pigmented hairs broken or destroyed at scalp level. In our study BDs are seen in 28% (42) cases, whereas it was higher in other studies like Hedge et al (67.7%), Mane et al (67.7%) and Inui et al (44.3%).<sup>21</sup> Black dots correlate with disease activity.<sup>10,11</sup>

Broken hairs broken hairs are seen in 27.3% of cases in our study whereas it is 37.33% and 43.05% in other studies. They result from transverse fracture of terminal hair shaft. They are not specific to AA, also seen in trichotillomania.

Exclamation mark hairs also called as tapering hairs. Exclamation mark hair are short broken hair that taper towards the root and are also lighter in color. Normal exclamation mark hairs which are visible to the naked eye, are approximately 1.0 cm long whereas trichoscopy allows visualization of exclamation mark hairs that are 1-2 mm long, called as micro exclamation hair” which is useful for early diagnosis of AA. It is seen in 34% in our cases, whereas it is 31.7% in Inui et al and 12.1% in Mane et al. These are considered as marker of disease activity.<sup>11,21</sup>

*Short vellus hair (SVH):* These are seen as new, thin and un pigmented hairs with in the patch (Figure 5). They have prognostic significance, which means they indicate the potential for regrowth in AA. They are seen in 74.7% cases in our study similar to Hegde et al (68%), Mane M et al (72.7%). Inui et al found SVH only in 40.9% of patients the difference could be attributed to different phases of disease. Like Mane et al and Inui et al we could not find any association between dermoscopic findings and various patterns of AA.<sup>10,11,21</sup>

Dermoscopy findings differ according to the activity of the disease. Our experience shows that yellow dots, black dots, broken hair and tapering hairs are a very consistent marker of disease activity whereas short vellus hairs indicates the potential for regrowth in AA.

## CONCLUSION

Patchy alopecia was the most common pattern seen in our study. The most common dermoscopic findings observed are yellow dots, short vellus hair, followed by exclamation mark hair, black dots and broken hair. single

dermoscopic feature may not be enough to reach a diagnosis of AA, constellation of findings such as black dots, tapering hairs, yellow dots, broken hairs and short vellus hair are diagnostic for AA.

*Funding: No funding sources*

*Conflict of interest: None declared*

*Ethical approval: The study was approved by the institutional ethics committee*

## REFERENCES

- Villasante Fricke AC, Miteva M. Epidemiology and burden of alopecia areata: a systematic review. Clin Cosmet Investig Dermatol. 2015;8:397-403.
- Pawar S, Talanikar HV, Patvekar M. Study of disease activity and its severity among patients of alopecia areata with the help of dermoscopic findings. Med Puls Int J Medic. 2017;3(1):10-2.
- Guttikonda AS, Aruna C, Ramamurthy DV, Sridevi K, Alagappan SK. Evaluation of clinical significance of dermoscopy in alopecia areata. Ind J Dermatol. 2016;61(6):628.
- Korta DZ, Christiano AM, Bergfeld W, Duvic M, Ellison A, Fu J, et al. Alopecia areata is a medical disease. J Americ Acade Dermatol. 2018;78(4):832-4.
- Mushtaq S, Raihan M, Lone A. Alopecia Areata - A literature Review. Int Arch BioMed Clin Res. 2017;3(1):7-10.
- Rudnicka L, Olszewska M, Majsterek M, Czuwara J, Slowinska M. Presence and future of dermoscopy. Expe Revi Dermatol. 2006;1:769.
- Jha AK, Udayan UK, Roy PK, Amar AK, Chaudhary RK. Dermoscopy of alopecia areata—a retrospective analysis. Dermatol Practic Concep. 2017;7(2):53.
- Pratt CH, King LE Jr, Messenger AG. Alopecia areata. Nat Rev Dis Primers. 2017;3:17011.
- Seetharam KA. Alopecia areata: An update. Ind J Dermatol Venereol Leprol. 2013;79:563-75.
- Hegde SP, Naveen KN, Athanikar SB, Reshme P. Clinical and dermoscopic patterns of alopecia areata: A tertiary care centre experience. Int J Trichol. 2013;5(3):132.
- Mane M, Nath AK, Thappa DM. Utility of Dermoscopy in alopecia areata. Ind J Dermatol. 2011;56(4):407-11.

12. Thomas EA, Kadyan RS. Alopecia areata and autoimmunity: a clinical study. *Ind J Dermatol.* 2008;53(2):70-4.
13. Ranawaka RR. An observational study of alopecia areata in Sri Lankan adult patients. *Ceylon Med J.* 2014;59(4):128-31.
14. Bolduc C, Elston DM. Alopecia Areata Clinical Presentation. Available at: <https://emedicine.medscape.com/article/1069931-clinical>. Accessed on 11 June 2020.
15. Sellami R, Masmoudi J, Ouali U, Mnif L, Amouri M, Turki H, et al. The relationship between alopecia areata and alexithymia, anxiety and depression: a case-control study. *Ind J Dermatol.* 2014;59(4):421.
16. Chelidze K, Lipner SR. Nail changes in alopecia areata: An update and review. *Int J Dermatol.* 2018;57(7):776-83.
17. Gandhi V, Baruah MC, Bhattacharaya SN. Nail changes in alopecia areata: Incidence and pattern. *Ind J Dermatol Venereol Leprol.* 2003;69:114-5.
18. Bains P, Kaur S. The Role of Dermoscopy in severity assessment of Alopecia Areata: A Tertiary care center study. *J Clin Aesthet Dermatol.* 2020;13(4):45-50.
19. Bapu NG, Chandrashekar L, Munisamy M, Thappa DM, Mohanan S. Dermoscopic findings of alopecia areata in dark skinned individuals: An analysis of 116 cases. *Int J Trichol.* 2014;6:156-9.
20. Mahmoudi H, Salehi M, Moghadas S, Ghandi N, Teimourpour A, Daneshpazhooch M. Dermoscopic findings in 126 patients with alopecia areata: A cross-sectional study. *Int J Trichol.* 2018;10(3):118.
21. Inui S, Nakajima T, Nakagawa K, Itami S. Clinical significance of Dermoscopy in alopecia areata: Analysis of 300 cases. *Int J Dermatol.* 2008;47:688-93.

**Cite this article as:** Nikhil N, Mamatha P, Hanumanthayya K. A study of clinical and dermoscopic features in alopecia areata at a tertiary referral center. *Int J Res Dermatol* 2020;6:744-9.