

Case Series

Skin manifestation in COVID-19 infection: a thousand appearances (immune response perspective)

Yohanes Firmansyah*, Jessica Elizabeth, Sukmawati Tansil Tan

Department of Dermatovenereology, Faculty of Medicine, Tarumanagara University, Jakarta, Indonesia

Received: 06 August 2020

Revised: 11 September 2020

Accepted: 14 September 2020

***Correspondence:**

Dr. Yohanes Firmansyah,

E-mail: yohanesfirmansyah28@gmail.com

Copyright: © the author(s), publisher and licensee Medip Academy. This is an open-access article distributed under the terms of the Creative Commons Attribution Non-Commercial License, which permits unrestricted non-commercial use, distribution, and reproduction in any medium, provided the original work is properly cited.

ABSTRACT

The clinical manifestations of COVID-19 infection are still unclear. The spectrum of the disease is very broad, with many target organs; one of them is skin. Various skin manifestations have been observed in COVID-19 patients. However, the observed skin manifestation was not specific. This following case series aims to provide an overview of skin manifestations in COVID-19 to help recognize the initial symptoms of COVID-19 infection. This case series also compares cases with and without skin manifestations. This case series discusses seven cases, which the patient had close contact, who had been diagnosed with confirmed COVID-19 by polymerase chain reaction (PCR) examination. The clinical symptoms were mild, such as fever, cough, sore throat, myalgia, malaise, headache, and skin lesions. There are few differences in complete blood laboratories. Radiology features within normal limits. All patients were given a treatment regimen according to the Indonesian lung association recommendations and symptomatic drugs. Three of seven cases had skin manifestation, which two of them had a maculopapular lesion, and the other one had urticaria lesions. Subjective symptoms, such as itching and burning sensation, were reported. The majority of lesions were localized on the upper and lower limb. Also, in this following case series, there is a tendency for complete blood parameters, neutrophil-to-lymphocyte ratio (NLR), and absolute lymphocyte count (ALC) to be lower in mild cases of confirmed COVID-19 with skin manifestations. It can be concluded that COVID-19 infection may result in skin manifestation with various clinical presentations. This important manifestation may help in diagnosing and treating COVID-19 and prevent further transmission.

Keywords: COVID-19, Skin manifestation, Maculopapular, Urticaria, NLR, ALC

INTRODUCTION

Since December 2019, there have been a series of unexplained cases of pneumonia reported in Wuhan, China. The Chinese government and researchers have taken swift steps to control the epidemic and find the etiology of mysterious pneumonia. On January 12, 2020, the World Health Organization (WHO) gave the terminology of the new virus as novel coronavirus 2019 (2019-nCoV). On January 30, 2020, WHO announced the status of the 2019-nCoV infection epidemic and gave warnings of a public health emergency and had become a serious problem at the international level. On February

11, 2020, WHO officially gave the terminology of the disease caused by 2019-nCoV as the 2019 COVID-19.

On the same day, the coronavirus study group of the international committee on virus taxonomy referred to the 2019-nCoV as severe acute respiratory syndrome coronavirus 2 (SARS-CoV-2).¹⁻³ Cases of SARS-CoV-2 infection until July 9, 2020, have infected 11,841,326 cases worldwide with a total death of 544,736 people. The United States occupied the country with the highest SARS-CoV infection with 6,125,802 cases, Europe 2,827,789 cases, Eastern Mediterranean with 1,222,070 cases, Southeast Asia 1,032,167 cases, and Africa with

397,942 cases.⁴ The state of Indonesia, as part of the Southeast Asian nation, reported 70,736 cases with 3,417 deaths on July 9, 2020.⁵⁻⁶

The clinical manifestations of COVID-19 itself are still unclear. Case reports indicate that the spectrum of the disease is very broad, with many target organs that may be targeted. In general, the symptoms reported range from mild to severe, with some cases leading to death. The most commonly reported symptoms are fever, cough, myalgia or fatigue, pneumonia, and severe dyspnea, while the rarely reported symptoms include headache, diarrhea, hemoptysis, runny nose, and cough with phlegm.⁷⁻⁹

As explained earlier, the clinical manifestations of COVID-19 disease itself may be very broad and not only focused on the respiratory organs or, in this case, the lungs.¹⁰⁻¹¹ Reports from various studies suggest that COVID-19 can attack the nervous system, gastrointestinal-hepatobiliary system, urology system, cardiovascular and metabolic system, hematology system, reproductive system especially in pregnancy, integument system or mucocutaneous with the actual form of efflorescence typical for other diseases, such as varicella.¹²⁻³³

This case series discusses the skin manifestations as a form of our vigilance in recognizing the initial symptoms of COVID-19 infection due to other than the general symptoms that exist in COVID-19 disease infection. Skin manifestation is one of the first visible manifestations and can appear on physical examination as an initial screening for suspected COVID-19 disease infection. This case report also compares cases with and without skin manifestations. All of these cases were cases with close contact due to living in the same house and with or without symptoms early in the course of the disease.

CASE SERIES

This case series discusses 7 cases that were medical personnel in a hospital and lived in the same house (close contact) who had been diagnosed as a case of COVID-19 confirmation by PCR examination for a DNA strain of COVID-19 with results of posterior anterior thoracic X-ray on day two symptoms and CT scan of the thorax on day four symptoms show a normal picture of the heart and lungs without infiltrates or increased pulmonary vascularity. The entire history of each patient's disease history is detailed in a chart in each section. All patients were given a treatment regimen according to the recommendations of the Indonesian lung association for mild symptoms, namely: Azithromycin 1x500 mg for three days, chloroquine phosphate 2x500 mg for five days, oseltamivir 2x75 mg for five days, vitamin C 3x1 tablets, and symptomatic drugs in the form of lansoprazole 1x30 mg for five days and Vectrin 2x1 tablet and paracetamol 3x500 mg to be taken together with azithromycin.

This following case report also discusses something unique that is 3 cases have manifestations of the skin and 4 cases that do not experience manifestations of the skin. The interesting thing to consider in this case report is that there are differences in the results of a complete blood laboratory, which will be presented in the discussion section.

Case 1

A 24-year-old woman with the main complaint of fever fluctuating with the highest temperature reaching 39° C. The patient is a medical staff at MAP-hospital has a history of contact with patients with positive COVID-19 confirmed. The history of the patient's disease is presented in detail in Figure 1. On day seven symptoms of skin lesions appear in the upper and lower extremities, symmetrical distribution, erythema colour, lenticular size, multiple numbers of discrete maculopapular rashes, and itching. Lesions did not appear in the body region and became more apparent on days 8 and 9 of symptoms. Patients were given 3x10 mg oral loratadine treatment and Nerilon cream for their skin lesions. Lesions on the skin disappear by the 10th day of symptoms.

Laboratory tests on day 2 of the symptoms gave results: haemoglobin 12.2 g/dl, haematocrit 35.8%, platelets 210,000/µl, erythrocytes 4.14 million/mm³, leukocytes 3160/µl with lymphocyte count of 23.4%, basophils 0.0%, neutrophils 60.8%, monocytes 15.5%. Neutrophil to lymphocyte ratio 2.6 and ALC 739 cells/mm³.

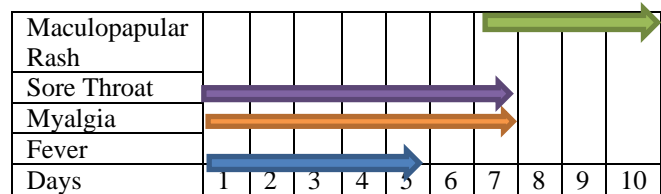


Figure 1: History of the first patient's disease.

Case 2

A 23-year-old woman with a chief complaint of cough and sore throat. The patient was a medical worker at MAP-hospital and had a history of contact with a positive COVID-19 patient. The history of the patient's disease is presented in detail in Figure 2. On the 12th day, symptoms of skin lesions appear in the upper and lower limb and neck region, symmetrically distributed, multiple in the form of urticaria with oedema in the central part with varying sizes and surrounded by erythema. The lesion is very itchy and feels hot. Patients were given treatment in the form of oral loratadine 3x10 mg, desoximetasone 0.25% cream, and Nerilon cream for skin lesions. Lesions on the skin disappear on the 15th day of symptoms. Laboratory tests on the 5th day of symptoms give results: haemoglobin 12.2 g/dl, haematocrit 37.0%, platelets 200,000/µl, erythrocytes 4.44 million/mm³, leukocytes 9400/µl with lymphocyte counts of 40.9%, basophils 0.2%, neutrophils 50.8%, 5.1% monocytes. NLR 1.24 and ALC 3845 cells/mm³.

MAP-hospital and had a history of contact with a positive COVID-19 patient. The patient's medical history is presented in detail in Figure 6.

Laboratory tests on the 5th day of symptoms gave results: haemoglobin 15.9 g/dl, haematocrit 44.7%, platelets 348,000/ μ l, erythrocytes 5.28 million/ mm^3 , leukocytes 9800/ μ l with a lymphocyte count of 33.8%, basophils 0.3%, neutrophils 57.2%, 7.0% monocytes. NLR 1.69 and ALC 3312 cells/ mm^3 .

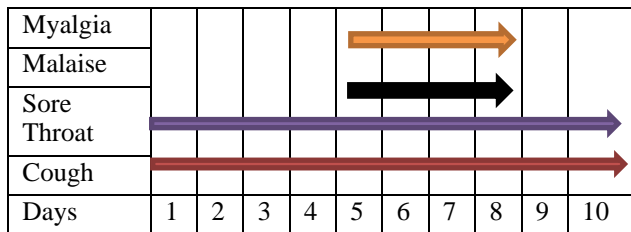


Figure 6: History of the sixth patient's disease.

Case 7

A 24-year-old man with a chief complaint of dry cough and sore throat. The patient was a medical worker at MAP-hospital and had a history of contact with a positive COVID-19 patient. The patient's medical history is presented in detail in Figure 7.

Laboratory tests on the 5th day of symptoms gave results: haemoglobin 16.3 g/dL, haematocrit 47.5%, platelets 326,000/ μ L, erythrocytes 5.89 million/ mm^3 , leukocytes 9460/ μ L with lymphocyte counts of 40.3%, basophils 0.4%, neutrophils 50.9%, monocytes 7.2%. NLR 2.10 and ALC 3812 cells/ mm^3 .

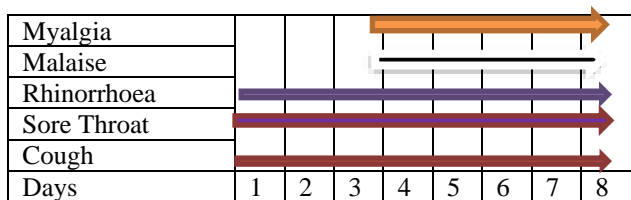


Figure 7: History of seventh patient disease.

DISCUSSION

The clinical manifestations of COVID-19 disease are very systemic and multi-organ that are not only focused on the respiratory system.^{10,11} Another organ system that has been proven to be part of the COVID-19 manifestation is the nervous system, gastrointestinal-hepatobiliary system, urology system, cardiovascular and metabolic system, hematology system, reproductive system especially in pregnancy, integument system or mucocutaneous with the actual form of efflorescence typical for other diseases, such as varicella.^{10-20,21-33}

This case series specifically discusses the skin manifestations of COVID-19 disease infections that occur in 3 of 7 cases with close contact in the same

environment. Several reports related to the skin manifestation of COVID-19 have been widely discussed abroad, but there are still very few case reports in Indonesia that discuss this.

Joob et al reported a petechial rash such as fever in a COVID-19 patient from Thailand.³⁴ Recalcati described 18 of 88 COVID-19 patients treated at Lecco hospital (Lombardy region, Italy) manifested as erythematous rash (n=14), extensive urticaria (n=3) or varicella-like vesicles (n=1). During the Italian outbreak, observed papulovesicular exanthem such as varicella as a rare but specific skin manifestation associated with COVID-19. Eight Italian dermatology units collected clinical data of patients with COVID-19 (microbiologically proven by nasopharyngeal swab), and there was no history of treatment in the previous 15 days that had drug side effects in the form of lesions such as varicella.³⁵

Case study reports from around the world report many forms of skin efflorescence from COVID-19 infection. Case reports from Fernandez (Spain) say the appearance of urticaria (urticaria from rash) spots six days after the onset of symptoms.³⁶ A case report from Estebanez (Spain) reports pruritic lesions (confluent erythematous yellowish papules) on the heel after 13 days of a definitive diagnosis of COVID-19 infection.³⁷ A case report from Zhang (China) reports the appearance of urticaria lesions in patients aged 57 years.¹⁰

Henry (France) reported the appearance of disseminated erythematous plaques eruption and urticaria on the face and all four limbs 48 hours before the appearance of respiratory manifestations.³⁸ Aghdam (Iran) reports the appearance of spots on the skin (Cutaneous mottling).³⁹ Mazzota (Italy) reported the presence of a round reddish red lesion measuring 5-15 mm with an indefinite border on the sole.⁴⁰ Alramthan (Qatar) reported the appearance of acral ischemic lesions with a purplish red color on the dorsal part of the finger bilaterally.⁴¹ Najarian (United States) said erythematous macules with lesions around them (morbilliform) on all four extremities and entire trunk at one day after the onset of respiratory symptoms.⁴² Kolivras (Belgium) reported the appearance of erythematous infiltrates placard lesions on the legs that appeared three days after the occurrence of respiratory symptoms. Sachdeva (Italy) reported 3 cases of Maculopapular itchy rash resembling Grover disease on the trunk, morbilliform spots and hemorrhagic macular spots on the body and extremities, as well as papulo-vesicular lesions with pruritic eruptions on the breast, groin, and trunk.²⁹

Sachdeva et al also reported eighteen articles, and three additional cases reported in her study found that the most common cutaneous manifestation of COVID-19 was maculopapular exanthem (morbilliform) in 36.1% (26/72) patients. Other skin manifestations that appeared were papulovesicular rash (34.7%, 25/72), urticaria (9.7%, 7/72), acral purple-red papules with pain (15.3%, 11/72), liveo reticular lesions (2.8%, 2/72) and petechiae (1.4%,

1/72). The majority of lesions were localized to the trunk (66.7%, 50/72). However, 19.4% (14/72) patients experienced skin manifestations on the hands and feet.²⁹

Manifestations of the skin have very broad and varied causes-research from Drago et al stated the seven morphological patterns studied included: macular erythema, papular erythema, papular erythema, erythematovesicular, macular-papular erythema with petechiae, erythema with pustules, and urticaria. Viruses caused ninety-four cases, 38 cases were caused by bacteria, 65 cases were caused by drugs, 3 cases by parasitic etiology, and one example was due to a mixture of viruses and drugs. Nineteen out of 25 cases with petechial patterns have etiology of infection (12 viruses and seven bacteria), and only 4 cases are iatrogenic. Sixty-one of 69 patients with infectious exanthem (57 viruses and four bacteria), 6 of which were iatrogenic, and two instances remained undiagnosed of the etiology of the disease. Petechial pattern with suspected infection in 80% of cases (14 viruses and two bacteria) with four of them being iatrogenic. During spring and summer, 60% of exanthem lesions are infectious or contagious, and 21% of cases are iatrogenic.⁴³

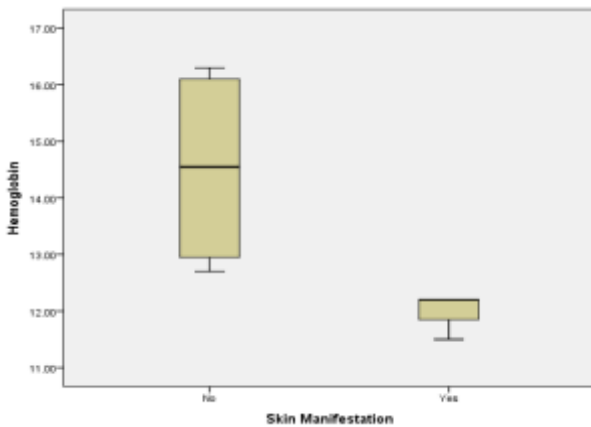


Figure 8: Comparison of haemoglobin levels in patients with and without skin manifestations.

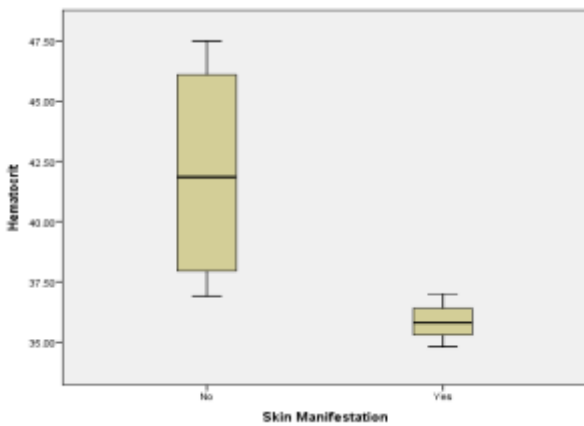


Figure 9: Comparison of haematocrit levels in patients with and without skin manifestations.

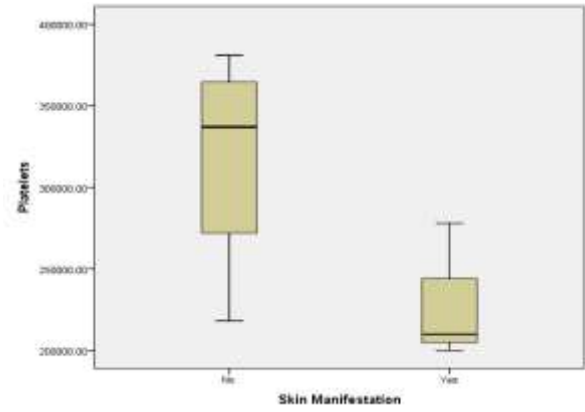


Figure 10: Comparison of platelet levels in patients with and without skin manifestations.

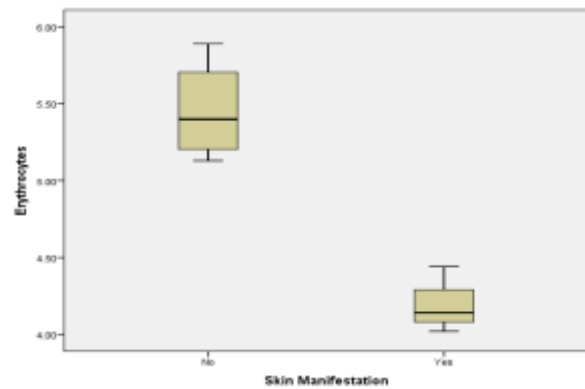


Figure 11: Comparison of erythrocyte levels in patients with and without skin manifestations.

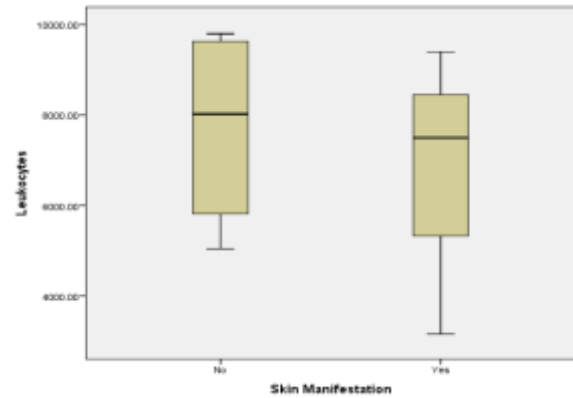


Figure 12: Comparison of leukocyte levels in patients with and without skin manifestations.

Interestingly enough, in this following case report is the tendency for complete blood parameters such as haemoglobin, haematocrit, platelets, erythrocytes, leukocytes, NLR, and ALC to be lower in mild cases of COVID-19 confirmation with skin manifestations. This is explained in detail in graphical form, which is presented from Figure 8 to Figure 14. The findings are a new finding, and when this journal was typed, there was no discussion of this in the literature search.

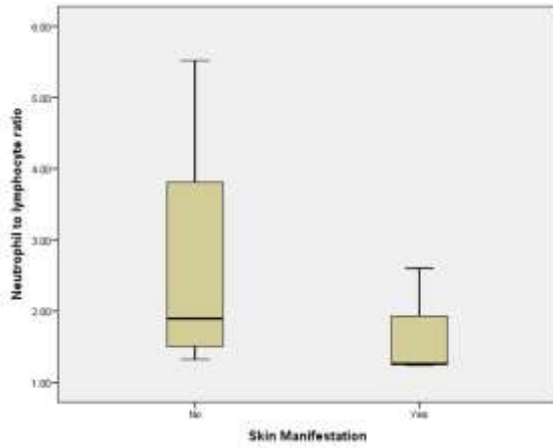


Figure 13: Comparison of NLR levels in patients with and without skin manifestations.

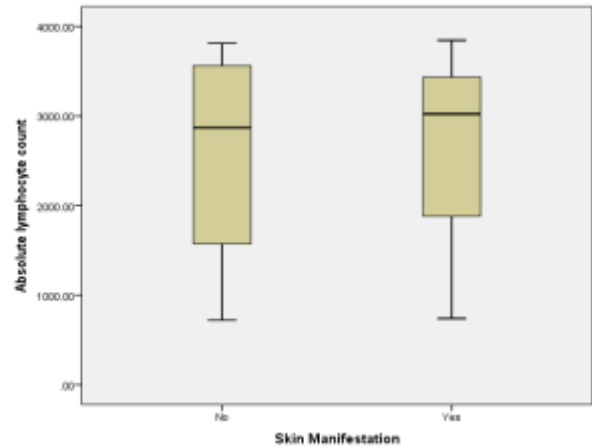


Figure 14: Comparison of ALC levels in patients with and without skin manifestations.

Table 1: Summary of laboratory results for all patients.

Variable	Hb (g/dl)	Ht (%)	Platelet (µl)	Ery (million/mm ³)	Leukocyte (µl)	NLR (cells/mm ³)	ALC (cells/mm ³)	Skin Manifestation
P1	12.2	35.8	210000	4.14	3160	2.6	739	Yes
P2	12.2	37	200000	4.44	9400	1.24	3845	Yes
P3	11.5	34.8	278000	4.02	7500	1.26	3023	Yes
P4	13.2	39	218000	5.52	5050	5.52	722	No
P5	12.7	36.9	381000	5.13	6590	1.32	2425	No
P6	15.9	44.7	348000	5.28	9800	1.69	3312	No
P7	16.3	47.5	326000	5.89	9460	2.1	3812	No

The above review explains that COVID-19 manifestations on the skin are very broad, but the results of this case series prove that there is no close correlation between the appearance of skin manifestations with COVID-19 infections, but the presence of skin manifestations can make clinicians more aware of possible COVID-19 infections.

CONCLUSION

Based on our findings and review of current evidence, it can be concluded that COVID-19 infection, although in a low percentage, can have skin manifestation. The lesions we found mostly look like an erythematous, morbilliform rash, and urticaria, where the upper and lower limb was the most frequently involved location. The most frequent symptom is itching, and the lesion usually healed within a few days. COVID-19 patients who experienced skin manifestation were relatively young and mostly had a mild clinical course, which can result from their younger age and no additional pathology. Skin manifestation also can be related to the patient’s immune response. However, the observed skin manifestation was not specific and similar to other viral infections. Therefore, clinicians should be aware of these important manifestations that may help in diagnosing and treating COVID-19 and prevent further transmission. Further

research is required to understand more about COVID-19 related skin manifestation.

Funding: No funding sources

Conflict of interest: None declared

Ethical approval: Not required

REFERENCES

1. Jones T, Nahal D. Beating the Pandemic: What Emergency Providers Should Know About COVID-19. *Pediatr Emerg Med Reports*. 2020.
2. Du B, Qiu HB, Zhan X, Wang YS, Kang HYJ, Li XY et al. Pharmacotherapeutics for the new coronavirus pneumonia. *Zhonghua Jie He He Hu Xi Za Zhi*. 2020;12;43(3):173-6.
3. Gorbalenya AE, Baker SC, Baric RS, Groot RJ, Gulyaeva AA, Haagmans BL et al. The species and its viruses-a statement of the Coronavirus Study Group. *Biorxiv*. Cold Spring Harb Lab. 2020.
4. World Health Organization. WHO Coronavirus Disease (COVID-19) Dashboard. World Health Organization. 2020. Available at: https://covid19.who.int/?gclid=CjwKCAjw5p_8BRBUEiwAPpJO67kCiZ1Z0nvV1tj94mikV9mitde615ruU8pB6g9TDAMx1t1ST9wEphoCm5gQAvD_BwE.
5. Indonesia Ministry of Health. COVID-19 Situation. Indonesia Ministry of Health. 2020. Available at:

- <https://covid19.kemkes.go.id/category/situasi-infeksi-emerging/info-corona-virus>.
6. Indonesia Ministry of Health. Guideline for Coronavirus Disease (COVID-19). Directorate General of Disease Prevention and Control. 2020. Available at: https://infeksiemerging.kemkes.go.id/download/REV-04_Pedoman_P2_COVID-19_27_Maret2020_TTD1.pdf.
 7. Huang C, Wang Y, Li X, Ren L, Zhao J, Hu Y et al. Clinical features of patients infected with 2019 novel coronavirus in Wuhan, China. *Lancet.* 2020;15;395(10223):497-506.
 8. Zhu N, Zhang D, Wang W, Li X, Yang B, Song J et al. A novel coronavirus from patients with pneumonia in China, 2019. *N Engl J Med.* 2020;382(8):727-33.
 9. Adhikari SP, Meng S, Wu YJ, Mao YP, Ye RX, Wang QZ et al. Epidemiology, causes, clinical manifestation and diagnosis, prevention and control of coronavirus disease (COVID-19) during the early outbreak period: A scoping review. *Infect Dis Poverty.* 2020;9(1):29
 10. J Jin ZJ, Dong X, Yuan CY, Dong YY, Bin YY, Qin YY et al. Clinical characteristics of 140 patients infected with SARS-CoV-2 in Wuhan, China. *Allergy Eur J Allergy Clin Immunol.* 2020;75(7):1730-41.
 11. Song JY, Yun JG, Noh JY, Cheong HJ, Kim WJ. COVID-19 in South Korea Challenges of Subclinical Manifestations. *N Engl J Med.* 2020;382:1199-207.
 12. Asadi-Pooya AA, Simani L. Central nervous system manifestations of COVID-19: A systematic review. *J Neurol Sci.* 202;413:116832.
 13. Zhou Y, Li W, Wang D, Mao L, Jin H, Li Y et al. Clinical time course of COVID-19, its neurological manifestation and some thoughts on its management. *Stroke Vasc Neurol.* 2020;5(2):177-9.
 14. Kotfis K, Williams RS, Wilson JE, Dabrowski W, Pun BT, Ely EW. COVID-19: ICU delirium management during SARS-CoV-2 pandemic. *Crit Care.* 2020;24(1):176.
 15. Tian Y, Rong L, Nian W, He Y. Review article: gastrointestinal features in COVID-19 and the possibility of faecal transmission. *Aliment Pharmacol Ther.* 2020;51(9):843-51.
 16. Cheong J, Bartell N, Peeraphatdit T, Mosli M, Al-Judaibi B. Gastrointestinal and liver manifestations of COVID-19. *Saudi J Gastroenterol.* 2020;26:226-32.
 17. Sinonquel P, Roelandt P, Demedts I, van Gerven L, Vandembriele C, Wilmer A et al. COVID-19 and gastrointestinal endoscopy: what should be taken into account? *Dig Endosc.* 2020.
 18. Agarwal A, Chen A, Ravindran N, To C, Thuluvath PJ. Gastrointestinal and Liver Manifestations of COVID-19. *J Clin Exp Hepatol.* 2020;10(3):263-5.
 19. Musa S. Hepatic and gastrointestinal involvement in coronavirus disease 2019 (COVID-19): What do we know till now? *Arab J Gastroenterol.* 2020;21(1):3-8.
 20. Wong SH, Lui RN, Sung JJ. Covid-19 and the digestive system. *J Gastroenterol Hepatol.* 2020;35(5):744-8.
 21. Puliatti S, Eissa A, Eissa R, Amato M, Mazzone E, Dell' Oglia P et al. COVID-19 and urology: a comprehensive review of the literature. *BJU Int.* 2020;125(6):E7-14
 22. Kang Y, Chen T, Mui D, Ferrari V, Jagasia D, Scherrer-Crosbie M et al. Cardiovascular manifestations and treatment considerations in COVID-19. *Heart.* 2020;106(15):1132-41.
 23. Li B, Yang J, Zhao F, Zhi L, Wang X, Liu L et al. Prevalence and impact of cardiovascular metabolic diseases on COVID-19 in China. *Clin Res Cardiol.* 2020;109(5):531-8.
 24. Bansal M. Cardiovascular disease and COVID-19. *Diabetes Metab Syndr Clin Res Rev.* 2020;14(3):247-50.
 25. Yang Z, Wang M, Zhu Z, Liu Y. Coronavirus disease 2019 (COVID-19) and pregnancy: a systematic review. *J Matern Neonatal Med.* 2020;1-4.
 26. Elshafeey F, Magdi R, Hindi N, Elshebiny M, Farrag N, Mahdy S et al. A systematic scoping review of COVID-19 during pregnancy and childbirth. *Int J Gynecol Obstet.* 2020;150(1):47-52.
 27. Zhao X, Jiang Y, Zhao Y, Xi H, Liu C, Qu F et al. Analysis of the susceptibility to COVID-19 in pregnancy and recommendations on potential drug screening. *Eur J Clin Microbiol Infect Dis.* 2020;1-3.
 28. Di Mascio D, Khalil A, Saccone G, Rizzo G, Buca D, Liberati M et al. Outcome of coronavirus spectrum infections (SARS, MERS, COVID-19) during pregnancy: a systematic review and meta-analysis. *Am J Obstet Gynecol MFM.* 2020;2(2):100107.
 29. Sachdeva M, Gianotti R, Shah M, Lucia B, Tosi D, Veraldi S et al. Cutaneous manifestations of COVID-19: Report of three cases and a review of literature. *J Dermatol Sci.* 2020;98(2):75-81.
 30. Wollina U, Karadağ AS, Rowland-Payne C, Chiriac A, Lotti T. Cutaneous Signs in COVID-19 Patients: A Review. *Dermatol Ther.* 2020;13549.
 31. Wollina U. Challenges of COVID-19 pandemic for dermatology. *Dermatol Ther.* 2020;13430.
 32. Ortega-Quijano D, Jimenez-Cauhe J, Burgos-Blasco P, Jimenez-Gomez N, Fernandez-Nieto D. Varicella-like exanthem as a specific COVID-19-associated skin manifestation: multicenter case series of 22 patients": Discussing specificity. *J Am Acad Dermatol.* 2020;83(1).
 33. Marzano AV, Genovese G, Fabbrocini G, Pigatto P, Monfrecola G, Piraccini BM, et al. Varicella-like exanthem as a specific COVID-19-associated skin manifestation: Multicenter case series of 22 patients. *J Am Acad Dermatol.* 2020;83(1):280-5.
 34. Joob B, Wiwanitkit V. COVID-19 can present with a rash and be mistaken for dengue. *J Am Acad Dermatol.* 2020;82(5):e177.
 35. Recalcati S. Cutaneous manifestations in COVID-19:

- a first perspective. *J Eur Acad Dermatol Venereol.* 2020;34(5):212-13.
36. Fernandez-Nieto D, Ortega-Quijano D, Segurado-Miravalles G, Pindado-Ortega C, Prieto-Barrios M, Jimenez-Cauhe J. Comment on: Cutaneous manifestations in COVID-19: a first perspective. Safety concerns of clinical images and skin biopsies. *J Eur Acad Dermatol Venereol.* 2020;34(6):e252-e254.
37. Estébanez A, Pérez-Santiago L, Silva E, Guillen-Climent S, García-Vázquez A, Ramón MD. Cutaneous manifestations in COVID-19: a new contribution. *J Eur Acad Dermatol Venereol.* 2020.34(6):250-51.
38. Henry D, Ackerman M, Sancelme E, Finon A, Esteve E. Urticarial eruption in COVID-19 infection. *J Eur Acad Dermatol Venereol.* 2020;34(6):544-45.
39. Kamali Aghdam M, Jafari N, Eftekhari K. Novel coronavirus in a 15-day-old neonate with clinical signs of sepsis, a case report. *Infect Dis (Auckl).* 2020;52(6):427-9.
40. Mazzotta F, Troccoli T. Acute Acro-Ischemia in the Child At the Time of COVID-19. *Dermatología Pediatr.* 2020;30(2):71-4.
41. Alramthan A, Aldaraji W. A case of COVID-19 presenting in clinical picture resembling chilblains disease. First report from the Middle East. *Clin Exp Dermatol.* 2020;45(6):746-8.
42. Najarian DJ. Morbilliform Exanthem Associated with COVID-19. *JAAD Case Reports.* 2020;6(6):493-4.
43. Drago F, Paolino S, Rebora A, Broccolo F, Drago F, Cardo P et al. The challenge of diagnosing atypical exanthems: A clinico-laboratory study. *J Am Acad Dermatol.* 2012;67(6):1282-8.

Cite this article as: Firmansyah Y, Elizabeth J, Tan ST. Skin manifestation in COVID-19 infection: a thousand appearances (Case series with close contact sample). *Int J Res Dermatol* 2020;6:776-83.