

Case Report

Familial diffuse comedones, different entity or variant of familial dyskeratotic comedones: a case report

Nandakishore Thokchom, Linda Kongbam*, Nandita Bhattacharjee, Erika Salam

Department of Dermatology, Venereology and Leprology, Regional Institute of Medical Sciences, Imphal, Manipur, India

Received: 05 July 2020

Accepted: 06 August 2020

***Correspondence:**

Dr. Linda Kongbam,

E-mail: lindaz_here@yahoo.co.in

Copyright: © the author(s), publisher and licensee Medip Academy. This is an open-access article distributed under the terms of the Creative Commons Attribution Non-Commercial License, which permits unrestricted non-commercial use, distribution, and reproduction in any medium, provided the original work is properly cited.

ABSTRACT

Familial dyskeratotic comedones (FDC) is a rare autosomal dominant genodermatosis characterized by numerous comedones with dyskeratosis in histology. We report a case of 43-year-old woman and her 16-year-old daughter presenting with extensive diffuse comedones on the face, trunk and proximal extremities. Mild slate-grey pigmentation of face in the mother was an additional finding. Skin biopsy showed crateriform invagination with parakeratotic lamellae filled with keratinous material in the epidermis but no dyskeratosis or acantholysis. The case resembles FDC as described earlier. However, certain features like presence of hyperpigmentation and minimal hyperkeratotic papules, and absence of dyskeratosis or acantholysis may suggest that diffuse familial comedones exist as a different genodermatosis.

Keywords: Familial dyskeratotic comedones, Comedones, Dyskeratosis

INTRODUCTION

Disseminated comedones have been described in some rare skin diseases. Familial dyskeratotic comedones (FDC) is a well-known genodermatosis with autosomal dominant inheritance characterized by asymptomatic widespread, symmetrically scattered, comedone like hyperkeratotic papules and dyskeratosis in histology.^{1,2} However, cases of familial diffuse comedones without dyskeratosis are extremely rare. Here, we present an unusual case of disseminated non-dyskeratotic comedones.

CASE REPORT

A 43 year old woman presented with extensive diffuse comedones affecting the face, trunk and proximal extremities. The lesions initially started on the face at 14 years of age as small dark pin-point papules followed by

slow progression to other body parts. The patient had no history of exposure to comedogenic substances or systemic medication. Her past medical history was unremarkable. Her first daughter had also developed similar lesions on the face, thighs and back at the age of 14 years. However, other family members were not affected (Figure 1).

Examination of the mother revealed generalized dark keratinous plugs distributed symmetrically on the face, upper back and proximal extremities (Figure 2). Diffuse pitted scars measuring 1-3 mm were also seen. A few tender inflammatory small papulonodular swellings were also present on the back. In addition, facial skin showed mild slate-grey pigmentation. No cystic swelling or pustules were seen. The scalp, palms, soles, mucous membranes and nails were normal. Systemic examination findings were normal. Examination of the daughter revealed few comedone like keratinous plugs on face, trunk and thighs (Figure 3).

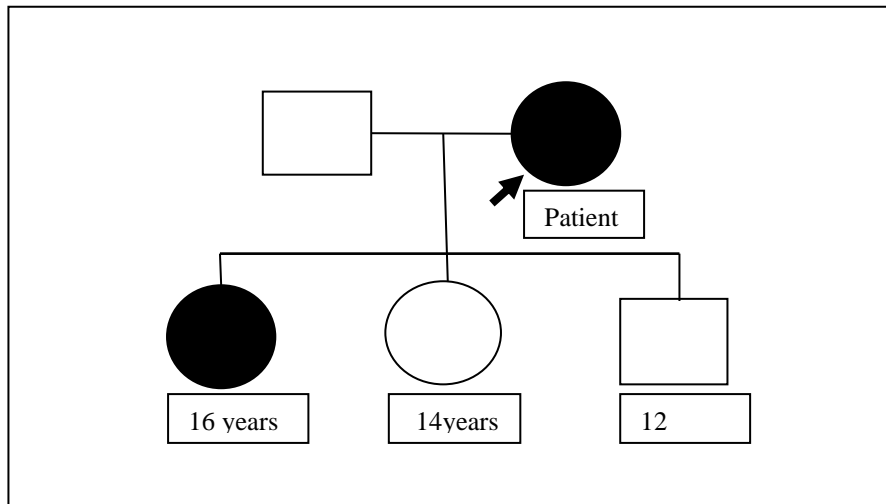


Figure 1: Pedigree chart.

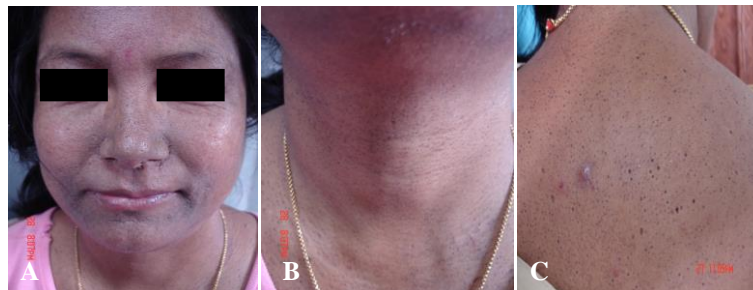

Figure 2: Dark keratinous plugs, (A) on face, (B) on neck and (C) on upper back. Mild slate-grey pigmentation of face and pitted scars in upper back.

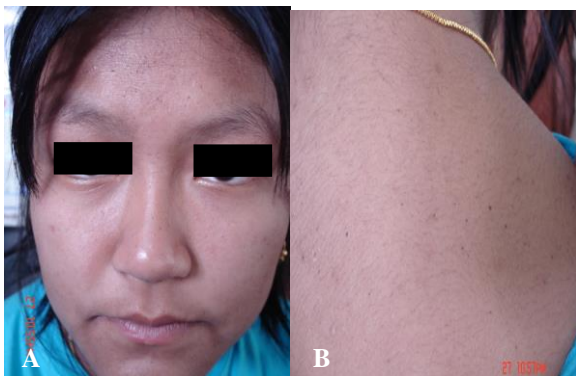

Figure 3: Few comedone like keratinous plugs, (A) on face and (B) on upper back.

Skin biopsy showed a crateriform invagination of the epidermis filled with keratinous material. Parakeratotic lamellae were seen within the invagination. However, no dyskeratotic or acantholytic cells were seen in the epidermis (Figure 4). Routine laboratory investigations were normal.

The lesions were treated with topical tretinoin and it showed mild improvement after 4 months.

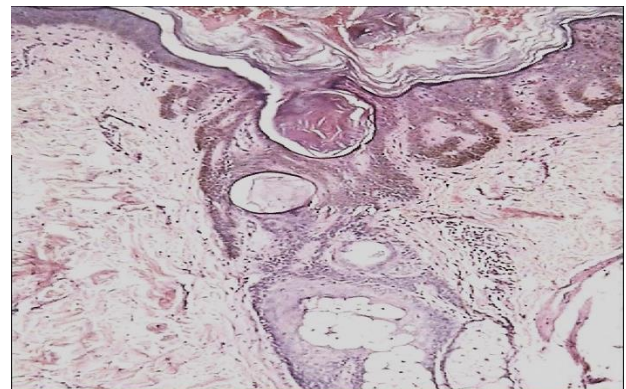


Figure 4: Epidermis showing a crater-like invagination filled with keratinous material. Parakeratotic lamellae are seen within the invagination. No dyskeratosis or acantholytic cells are seen. The dermis shows mild pericapillary lymphocytic infiltration (H&E, 40X).

DISCUSSION

A diffuse generalized distribution of comedones was first described by Rodin et al.³ in 1967. Later, Carneiro et al.¹ proposed the term FDC when he described a family of 4 members affected with lesions clinically resembling comedones and presence of dyskeratotic changes on

histological examination. Further studies showed autosomal dominant inheritance pattern of the disease.² Its onset is mostly in puberty, with a gradual increase in number and the lesions show a predilection for the trunk, arms, legs, face and shaft of the penis, sparing the glans, palms and soles.⁴ Onset at childhood has also been reported.^{1,2,5} Histologically, it is characterized by dyskeratosis and invaginations into the dermis, occasionally acantholysis may be seen. Acne vulgaris, Kyrle's disease, keratosis pilaris, perforating folliculitis, nevus comedonicus and Darier disease must be considered in the differential diagnosis.¹

In India, Kumaran et al.⁶ first reported 2 cases of FDC who had a strong familial history. Maddala RR et al.⁷ also reported a family of FDC from central India with one member with early age of onset and sparing of face. Our case also showed similar clinical presentation with an additional feature of slate-grey pigmentation of intervening skin and no acantholytic or dyskeratotic changes in histology. These features render the case distinct from FDC. Cheng et al.⁸ also reported a case of familial disseminated comedones without dyskeratosis with autosomal dominant trait but was associated with mild to pronounced acne and no pigmentation.

As the condition is asymptomatic it may only be discovered incidentally. Social interaction may be disturbed because of the cosmetic disfigurement. Various treatment modalities including topical retinoids and oral isotretinoin have been tried but largely ineffective.

CONCLUSION

The present case is the third report of diffuse familial comedones from India. It generally resembles familial dyskeratotic comedones which have been described and reported more often in the world literature. However, certain features like presence of minimal hyperkeratotic papules, absence of dyskeratosis or acantholysis and presence of hyperpigmentation may suggest that diffuse familial comedones exist as a different genodermatosis.

Funding: No funding sources

Conflict of interest: None declared

Ethical approval: Not required

REFERENCES

1. Carneiro SJ, Dickson JE, Knox JM. Familial dyskeratotic comedones. *Arch Dermatol.* 1972;105:249-51.
2. Cantú JM, Gomez-Bustamante MO, González-Mendoza A, Sánchez-Corona J. Familial comedones: evidence for autosomal dominant inheritance. *Arch Dermatol.* 1978;114:1807-9.
3. Rodin HH, Blankenship ML, Bernstein G. Diffuse familial comedones. *Arch Dermatol.* 1967;95:145-6.
4. Van Geel NA, Kockaert M, Neumann HA. Familial dyskeratotic comedones. *Br J Dermatol.* 1999;140:956-9.
5. Zhang RZ, Zhu WY. Idiopathic disseminated comedones in a child. *Pediatr Dermatol.* 2006;23:163-6.
6. Kumaran MS, Appachu D, Jayaseelan E. Familial dyskeratotic comedones. *Indian J Dermatol Venereol Leprol.* 2008;74:142-4.
7. Maddala RR, Ghorpade A, Polavarpu M, Adulkar SA, Das M. Familial dyskeratotic comedones: a rare entity. *Indian Dermatol Online J.* 2016;7:46-8.
8. Cheng MJ, Chen WC, Happle R, Song ZQ. Familial disseminated comedones without dyskeratosis: report of an affected family and review of the literature. *Dermatology.* 2014;228(4):303-6.

Cite this article as: Thokchom N, Kongbam L, Bhattacharjee N, Salam E. Familial diffuse comedones, different entity or variant of familial dyskeratotic comedones: a case report. *Int J Res Dermatol* 2020;6:680-2.