

Case Series

Disseminated talaromycosis: an AIDS defining fungal infection

Bijayanti Devi¹, Sana S.^{1*}, Bharath Meka¹, Bhuvanesh Raj²

¹Department of Dermatology, Venereology and Leprology, ²Department of Microbiology, Regional Institute of Medical Sciences, Imphal, Manipur, India

Received: 05 June 2020

Accepted: 29 July 2020

*Correspondence:

Dr. Sana S.,

E-mail: sanashems@gmail.com

Copyright: © the author(s), publisher and licensee Medip Academy. This is an open-access article distributed under the terms of the Creative Commons Attribution Non-Commercial License, which permits unrestricted non-commercial use, distribution, and reproduction in any medium, provided the original work is properly cited.

ABSTRACT

Talaromycosis is a systemic mycosis caused by *Talaromyces marneffeii*. It mostly occurs as an opportunistic infection in patients with human immunodeficiency virus (HIV). In India, its endemic in Manipur. We report 3 cases of disseminated talaromycosis with skin eruptions in HIV sero-positive patients from Manipur.

Keywords: Talaromycosis, *Talaromyces marneffeii*, AIDS, cutaneous penicilliosis

INTRODUCTION

Talaromycosis (aka Penicilliosis) is a systemic mycosis caused by *Talaromyces marneffeii* (earlier - *Penicillium marneffeii*), predominantly in immunocompromised patients. There is a strong association with AIDS. It ranks third in opportunistic infections behind tuberculosis and cryptococcosis in patients with acquired immunodeficiency syndrome (AIDS).¹⁻³ The disease is endemic in several regions of Southeast Asia including Thailand, Malaysia, South China, Indonesia and Vietnam. In India, it is endemic in Manipur state in Northeast India as evidenced by reports of numerous autochthonous cases from this state.^{4,5} A few imported cases of *T.marneffeii* infection have been reported from non-endemic areas of India.⁴⁻⁹ A lot is still unknown about the natural reservoir and route of transmission of *T.marneffeii*. Human and bamboo rats are the only known animal hosts of *T. marneffeii*.

CASE REPORT

Case 1

A 44 year old male, farmer from Manipur presented with multiple asymptomatic papules on face and trunk since 1

week with history of fever, cough, loose stools, loss of appetite, weight loss for past 2 months. The patient was known to be HIV seropositive and was on antiretroviral therapy (ART) for past 1 month. Skin lesions started 15 days after initiation of ART drugs (tenofovir, efavirenz, lamivudine (TEL)). Lesions started on forehead and progressed to involve whole face, trunk and bilateral upper extremities. There were no oro-genital lesions. On cutaneous examination multiple skin coloured flat topped, umbilicated and dome shaped papules, plaques and few nodules with umbilication and central hemorrhagic crusts distributed over face, neck, bilateral pinna, trunk, bilateral upper limbs noted (Figure 1). Systemic examination was normal. Differential diagnosis of histoplasmosis, secondary syphilis, cryptococcosis and penicilliosis was considered.

Laboratory investigations revealed Hb 8 gm%, plt 90,000/mm³, ESR- 110 mm/ 1st hr. HIV seropositive and absolute CD4 cell count 13 cells/ microlitre. Mantoux test, HBsAg, HCV Ab, VDRL, scrub typhus, typhoid test were negative. Chest X-ray was also normal. Skin biopsy revealed orthokeratotic epidermis, foamy histiocytes with scattered lymphocytes and plasma cells in dermis, numerous yeast forms of fungus displaying binary fission, morphologically resembling *T.marneffeii* (Figure

2). On KOH fungal elements were seen, lactophenol cotton blue (LCB) preparation showed metulae bearing brush like conidiophores suggestive of penicillium spp (Figure 3), fungal culture revealed growth of penicillium species after 3 weeks of incubation as a mold with red diffusible pigment (Figure 4). On the basis of clinical, histopathological and mycological findings, a diagnosis of Talaromycosis was established. The patient was treated with oral antifungal, itraconazole 400 mg/day, and he showed improvement in skin lesions after 4 weeks of treatment, however he was lost to follow up thereafter.

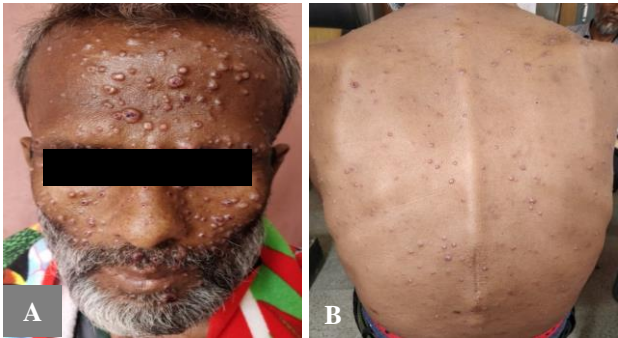

Figure 1: Multiple erythematous to skin coloured papules with umbilication and hemorrhagic crusts (few) (A) over face, (B) trunk.

Case 2

A 26 year old male student presented with generalised weakness and asymptomatic skin lesions over face since 1 month. Patient is a k/c/o HIV seropositive and is on 1st line ART (TLE) for past 6 years. On cutaneous examination multiple discrete skin coloured to hypopigmented papules, few of them with umbilication and central crusting on face and upper extremities were noted (Figure 5A). Systemic examination was normal.

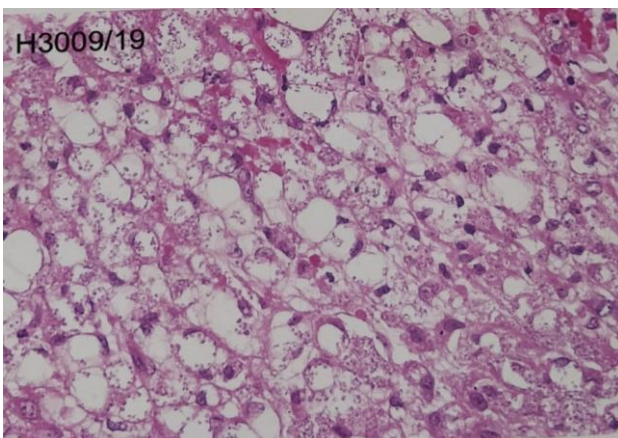


Figure 2: Histopathology: numerous yeast forms of fungus displaying binary fission, morphologically resembling *T.marneffeii* (H & E, 40X).

Laboratory investigations revealed pancytopenia, ESR of 120 mm/ 1st hr, deranged liver enzymes with absolute

CD4 count of 46 cells/microlitre. On Skin biopsy, dermis showed numerous yeast form of fungus, both extracellular and intracellular, few of which seen dividing by binary fission, morphologically resembling *T.marneffeii*. KOH and fungal culture was diagnostic of penicillium species. Patient was treated with Inj. Amphotericin B 50 mg for 2 weeks followed by tab. Itraconazole 400 mg/ day for 3 months followed by tab. Itraconazole 200 mg/ day till CD4 count >350 cells/microlitre. Patient showed significant improvement in skin lesions after 3 weeks of treatment, and complete resolution in 6 weeks, lost to follow up thereafter.

Case 3

A 39 year old male patient presented with fever for past 1 month and itchy skin lesions over face, neck and upper extremities for past 1 week. He is HIV seropositive with pulmonary tuberculosis and is on highly active antiretroviral therapy (HAART) and antitubercular drug (ATD) for past 1 month. On examination multiple discrete skin coloured papules and nodules with umbilication and central crusts on face, neck and bilateral upper extremities were noted. No oro-genital lesions (Figure 5B). Systemic examination was normal.

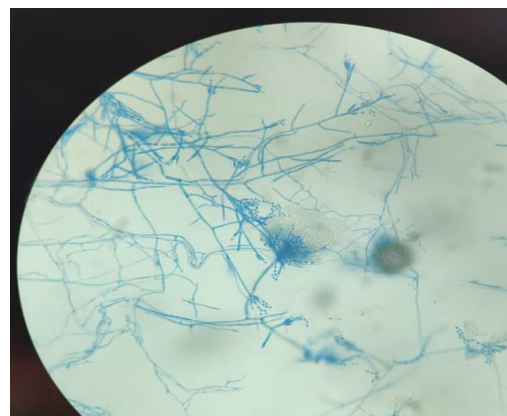


Figure 3: LCB preparation: metulae bearing brush like conidiophores.

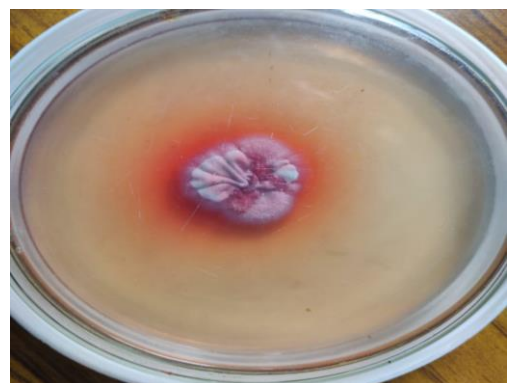

Figure 4: Fungal culture: growth of penicillium species as mold with red diffusible pigment after 3 weeks of incubation.

Laboratory investigations showed Hb 7 gm%, ESR- 100 mm/ 1st hr, absolute CD4 cell count of 74 cells/microlitre, rest of them were within normal limits. Skin biopsy showed similar picture as above two patients, suggestive of penicillium spp. KOH and Fungal culture were diagnostic of penicillium marneffeii. Patient was initiated treatment with itraconazole 400 mg/ day, but was lost to follow up thereafter.

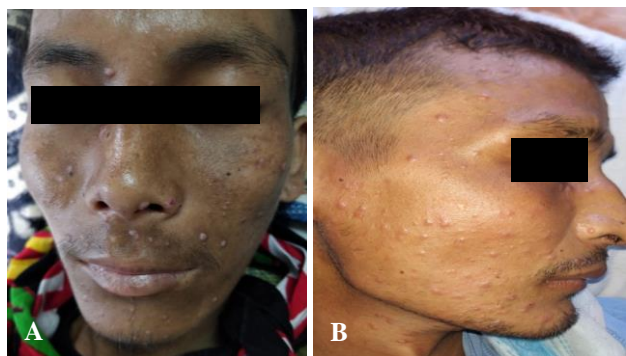


Figure 5: Multiple skin coloured umbilicated papules on face (A) case 2, (B) case 3.

DISCUSSION

Talaromycosis is the 3rd most common opportunistic infection in HIV infected patients in endemic areas. In India, disseminated talaromycosis has been reported among HIV- infected patients in Manipur and Assam. Though natural infections can occur in bamboo rats, no evidence of direct transmission to humans were seen. It is rare in children and affects both the sexes equally.

T. marneffeii can cause focal or disseminated infection. Our patients suffered from disseminated infection. Other authors also reported similar typical talaromycosis infection in their study.^{4,6} The incubation period varies from a few weeks to many years. The common symptoms are fever of unknown origin, cough, chest pain, weight loss, lymphadenopathy. Signs of dissemination are anemia, multiple skin papules and hepatosplenomegaly. The skin lesions are usually present in 50% of cases, as small papules/nodules with central umbilication and crusts/ ulcers. Common sites are face, upper trunk, pinnae, arms. These skin eruptions may be confused with molluscum contagiosum, histoplasmosis and cryptococcosis. Rarely patient may present with lung abscess, fungaemia, diarrhea, necrotic nodules, osteomyelitis, leukocytosis, genital ulcers, pericarditis also. Most of the patients show absolute CD4 count less than 100/ul. Complications include dissemination to other sites and fungaemia and if it is left untreated, the infection is fatal.¹⁰

The diagnosis of talaromycosis may be suspected or made through examination of cytology or biopsy specimens. Specimens for investigation can be collected as skin scraping, bone marrow aspirate, lymph node,

blood, sputum. Skin biopsy shows intracellular & extracellular basophilic elliptical yeast-like organism with central septation. Fungal culture is the gold standard investigation, as displayed by green or greyish mold with red diffusible pigment at 26°C and as dry, yeast-like colonies at 37°C. Microscopically, the mold form is typical of other *Penicillium* species with hyaline septated hyphae and fruiting structures composing of branching metulae and phialides which produce spherical conidia in chains.

The fungus is sensitive to amphotericin B, itraconazole, and ketoconazole. The current recommended treatment regimen is to give amphotericin B 0.6 mg/kg/day for 2 weeks followed by itraconazole 400 mg/day orally in two divided doses for the next 12 weeks. After initial treatment the patient should be given itraconazole 200 mg/day, as secondary prophylaxis for life, if HAART cannot be offered.¹¹

CONCLUSION

As *T. marneffeii* is an emerging pathogen, a high index of suspicion is required in areas which have geographical proximity to Southeast Asia, North-Eastern India and Bangladesh. Penicilliosis requires further in-depth study with respect to its global distribution, natural history, pathogenesis and the impact of antiretroviral therapy. The mortality rate of untreated penicilliosis is 100%.¹² Any delay in the initiation of antifungal therapy is associated with poor outcome, whereas the therapeutic response is good with early institution of treatment.

Funding: No funding sources

Conflict of interest: None declared

Ethical approval: Not required

REFERENCES

1. Nittayananta W. Penicilliosis marneffeii: Another AIDS defining illness in Southeast Asia. *Oral Dis.* 1999;5:286-93.
2. Ustianowski AP, Sieu TP, Day JN. *Penicillium marneffeii* infection in HIV. *Curr Opin Infect Dis.* 2008;21:31-6.
3. Vanittanakom N, Cooper CR Jr, Fisher MC, Sirisanthana T. *Penicillium marneffeii* infection and recent advances in the epidemiology and molecular biology aspects. *Clin Microbio Rev.* 2006;19:95-110.
4. Ranjana KH, Priyokumar K, Singh TJ, Gupta ChC, Sharmila L, Singh PN, et al. Disseminated *Penicillium marneffeii* infection among HIV-infected patients in Manipur state, India. *J Infect.* 2002;45:268-71.
5. Varghese GM, Pise G, Michael SJ, Jacob M, George R. Disseminated *Penicillium marneffeii* infection in a human immunodeficiency virus infected individual. *J Postgrad Med.* 2004;50:235-6.

6. Maniar JK, Chitale AR, Miskeen A, Shah K, Maniar A. *Penicillium marneffei* infection: An AIDS-defining illness. *Indian J Dermatol Venereol Leprol.* 2005;71: 202-4.
7. Sharma A, Hazarika NK, Barua P, Dey I, Tudu NK. *Penicillium marneffei* infection in a HIV infected child. *Indian J Med Res.* 2007;126:580-2.
8. Devi KR, Singh LR, Rajkumari R, Usharani M, Devi KhS, Singh TB. *Penicillium marneffei*- an indicator disease of AIDS. *Indian J Pathol Microbiol.* 2007;50:3:674-6.
9. George IA, Sudarsanam TD, Pulimood AB, Mathews MS. An acute abdomen: An unusual presentation of disseminated *Penicillium marneffei* infection. *Indian J Med Microbiol.* 2008;26:180-2.
10. Hay RJ, Ashbee HR. Fungal Infections. In: Griffiths C, Barker J, Bleiker T, Chalmers R, Creamer D, editors. *Rook's Textbook of Dermatology.* 9th ed. UK: Wiley - Blackwell Publication; 2016: 32.90-1.
11. Supparatpinyo K, Perriens J, Nelson KE, Sirisanthana T. A controlled trial of itraconazole to prevent relapse of *Penicillium marneffei* infection in patients infected with the human immunodeficiency virus. *N Engl J Med.* 1998;339:1739-43.
12. Supparatpinyo K, Nelson KE, Merz WG, Breslin BJ, Cooper CR, Kamwan C, et al. Response to antifungal therapy by human immunodeficiency virus infected patients with disseminated *Penicillium marneffei* infections and in vitro susceptibilities of isolates from clinical specimens. *Antimicrob Agents Chemother.* 1993;37(11):2407-11.

Cite this article as: Devi B, Sana S, Meka B, Raj B. Disseminated talaromycosis: an AIDS defining fungal infection. *Int J Res Dermatol* 2020;6:676-9.